

# Odontogenic Keratocyst (OKC) as Tumor: A Surgeons Dilemma between Resection and Recurrence

Vivek Kumar<sup>1</sup>, Avanindra Kumar<sup>2</sup>, Soumen Mandal<sup>3</sup>, Anupam Kumar<sup>4</sup>

## ABSTRACT

**Introduction:** Keratocystic odontogenic tumours (KCOTs) are benign but locally aggressive lesions with high propensity to recurrence with Aggressive growth, within the jaws and tendency to invade surrounding anatomical structures.

**Case Report:** The article presents a case report of very commonly happened case of the recurrence of KCOTs after conservative approach, like marsupialization or curettage in the treatment of cyst like small OKC in day to day practice along with the treatment modalities. The case of recurrence KCOTs, shows the degenerative nature of tumor in a short period of time after operation. A 28 years old female having history of extraction of third molar followed by curettage of cyst done just 2.5 years back.

**Conclusion:** The postoperative course was uneventful. The patient has been checked regularly for more than 3 years without any sign of recurrence

**Keywords:-** Odontogenic keratocyst (OKC), Keratocystic odontogenic tumor (KCOTs), Orthokeratinization, Marsupialization.

also present as a multilocular radiolucency with a ratio of unilocular to multilocular varying from 3:1 to 1:1.3.<sup>7,9</sup>

## Common Treatment Modalities

Morgan and colleagues categorize surgical treatment methods for KCOT as conservative or aggressive.<sup>15</sup> Conservative treatment is cyst-oriented and, thus, includes enucleation, with or without curettage, or marsupialization.<sup>5,16</sup> Aggressive treatment addresses the neoplastic nature of the KCOT and includes peripheral ostectomy, chemical curettage with Carnoy's solution or en-bloc resection.

Some authors advocate a site and size based approach to KCOT treatment planning. For example, Dammer R. and co workers suggest that "small OKC of 1 cm in diameter should be treated by simple excision, but large OKC near the base of the skull which should be treated by radical excision".<sup>17</sup> This is presumably because of the potential for local invasion of the skull base, which can have catastrophic consequences. With surgical treatment, removal of the mucosa overlying the lesion has been recommended, based on histologic evidence that clusters of epithelial islands and microcysts presumably with the potential to cause recurrence have been found in the area where the KCOT was connected with the mucosa.<sup>18</sup>

## INTRODUCTION

The odontogenic keratocyst (OKC) was first described in 1876 and the name proposed by Phillipson in 1956.<sup>1</sup> It is one of the most aggressive odontogenic cysts of the oral cavity.<sup>2</sup> Due to neoplastic nature World Health Organization (WHO) recognized OKC as keratocystic odontogenic tumour (KCOT-2005). Keratocystic Odontogenic Tumors (KCOTs) is defined as a benign, odontogenic, uni- or multicystic intraosseous tumors, with characteristic parakeratinized stratified squamous epithelium lining, having a potential for aggressive and infiltrative behavior (growth).<sup>3</sup> However, since KCOTs also exhibit some cysts-like features, including response to decompression.<sup>4</sup> KCOTs comprise approximately 11% of all cysts of the jaws<sup>5</sup>, and almost always occur within bone, although a small number of cases of peripheral KCOT have been reported.<sup>4</sup> Around 40% to 60% of KCOTs are diagnosed in patients in their 2nd and 3rd decade of life. In some studies, bimodal age distribution has been noted, with highest number of cases in patients aging from 10 to 19 and from 20 to 29 years, just to be followed by another rise in a group of those from 50 to 64 years of life.<sup>6</sup> The distribution between sexes varies from equality to a male to female ratio of 1.6:1, except children.<sup>7,9-11</sup> Odontogenic keratocyst may occur in any part of the upper and lower jaw with the majority occurring in the mandible, most commonly in the angle and ramus of the mandible.<sup>7,8,10-13</sup> Radiographically, odontogenic keratocyst present predominantly as a unilocular radiolucency with well-developed sclerotic borders. They may

## RESULT

A review of the literature suggests that recurrence rate is relatively low with aggressive treatment, whereas more conservative methods tend to result in more recurrences. First, enucleation along with Carnoy's solution, with or without peripheral ostectomy results in a significantly lower rate of recurrence than enucleation alone. Second, the use of cryotherapy with enucleation appears to have no significant effect on the recurrence rate compared with enucleation alone. Third, marsupialization as a definitive treatment is associated with a significantly higher recurrence rate than when the KCOT is subsequently enucleated. Finally, resection, despite

<sup>1</sup>Reader, Department of Oral and Maxillofacial Surgery, <sup>2</sup>Reader, Department of Oral and Maxillofacial Pathology, Dr. B R Ambedkar Institute of Dental Sciences and Hospital, Patna, <sup>3</sup>Private Practitioner, Oral and Maxillofacial Surgery, Kolkata, West Bengal, <sup>4</sup>Dental Surgeon, Bihar Government Health Service, Bihar, India

**Corresponding author:** Vivekkumar, Reader, Department of Oral and Maxillofacial Surgery, Dr. B R Ambedkar Institute of Dental Sciences and Hospital, Patna, India.

**How to cite this article:** Vivek Kumar, Avanindra Kumar, Soumen Mandal, Anupam Kumar. Odontogenic Keratocyst (OKC) as tumor: a surgeons dilemma between resection and recurrence. International Journal of Contemporary Medical Research 2016;3 (2):336-338.

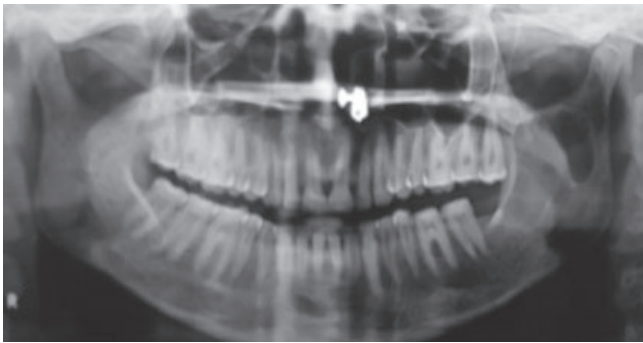

Figure-1: pre operative

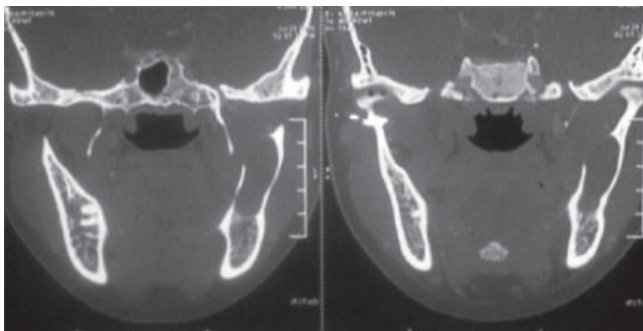


Figure-2: pre operative CTF

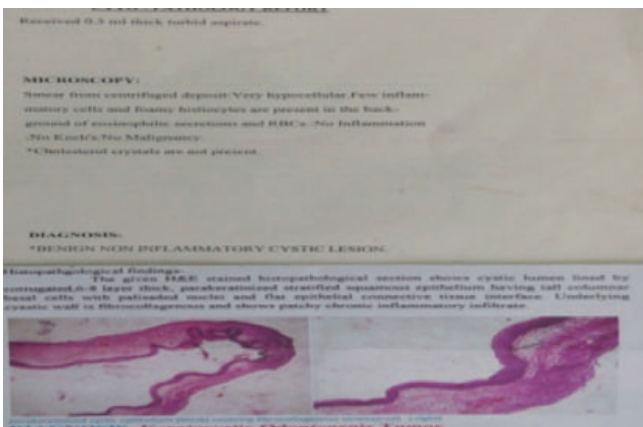


Figure-3: pre operative

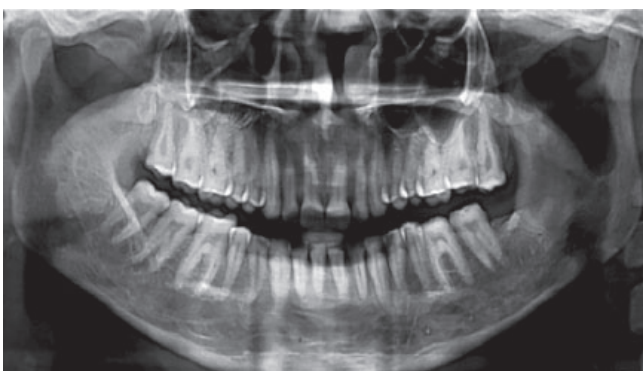

Figure-4: 6 month post op.

a recurrence rate of about zero, is not significantly better at eliminating recurrences than enucleation plus Carnoy's solution or marsupialization plus cystectomy. Therefore, to minimize invasiveness and recurrence, the

most effective treatment option appears to be enucleation of the KCOT and subsequent application of Carnoy's solution. Alternatively, marsupialization followed by cystectomy is likewise effective.<sup>19</sup>

**CASE REPORT**

A 28-year-old female patient reported to a department of oral and maxillofacial surgery in Dr B. R Ambedkar institute of dental science and hospital with complain of pain and swelling in the left facial region, along with pus discharge from left lower posterior tooth region for last one year.

Patient was alright one year back when she noticed intraoral swelling digital to left lower second molar tooth with some fluid discharge from same region of mouth. Pain present over left lower border of mandible to auricular region during mouth opening. Pain was subsided by the unknown medication. She gave history of extraction of third molar along with removal of cyst in a single surgical procedure, about two and half years back. Clinical examination revealed intra oral swelling present digital to second molar in the 3<sup>rd</sup> quadrant, with sinus opening which was fluctuant on palpation. Bilaterally condylar movement was felt properly, but mouth opening limited to 20 mm. limited mouth opening was most probably due to pain. Diagnostic records included orthopantomogram (OPG), CT face for rule out of any maxillofacial pathology involving mandible or other facial bone. Based on the above findings and Panoramic radiograph demonstrated a well-demarcated unilocular radiolucency with well-developed sclerotic border on left ramus of mandible from angle to coronoid notch (Fig 1). Computed tomography also demonstrate cystic lesion in the left ramus of mandible (Fig 2). FNAC report also conforms the above mention case was benign non inflammatory cyst (Fig-3).

Due to the anatomy and recurrence nature of cyst we follow the most effective treatment option i.e enucleation of the cyst and subsequent application of Carnoy's solution under general anesthesia. The removed specimen was sent for histopathology, and the report conform KCOTs(Fig-3).

The postoperative course was uneventful. The patient has been checked regularly for more than 3 years without any sign of recurrence (Fig-4).

**REFERENCES**

1. Philipsen HP. Om keratocystedr (Kolesteratomer) and kaeberne. Tandlaegebladet 1956;60:963-71.
2. Shear M. The aggressive nature of the odontogenic keratocyst: is it a benign cystic neoplasm? Part 2. Proliferation and genetic studies. Oral Oncol. 2002;38:323-331.
3. Barnes L, Eveson JW, Reichart P, Sidransky D, editors. Pathology and genetics of head and neck tumours. Lyon: IARC Press; 2005. WHO classification of tumours series.
4. Brondum N, Jensen VJ. Recurrence of keratocysts and decompression treatment. Along-term follow-up of forty-four cases. Oral Surg Oral Med Oral Pathol. 1991;72: 265-269.

5. Maurette PE, Jorge J, de Moraes M. Conservative treatment protocol of odontogenic keratocyst: a preliminary study. *J Oral Maxillofac Surg* 2006;64:379–83.
6. Shear M, Speight PM. Odontogenic keratocyst. In Shear M, Speight PM. *Cysts of the Oral and Maxillofacial Regions*, Oxford: Blackwell Munksgaard; 2007,6–58.
7. Haring JI, Van Dis ML. Odontogenic keratocysts; a clinical, radiographic and histopathologic study. *Oral Surg Oral Med Oral Pathol* 1988;66:145-53.
8. Brondum N, Jensen VJ. Recurrence of keratocysts and decompression treatment. A long-term follow-up of forty-four cases. *Oral Surg Oral Med Oral Pathol* 1991;72:265-69.
9. Chen C-H, Lin C-C. Clinical and histopathological study of the odontogenic keratocyst - a follow-up study of 16 cases. *Kaohsiung J Med Sci* 1986;2:601-07.
10. Woolgar JA, Rippin JW, Browne RM. A comparative study of the clinical and histological features of recurrent and non-recurrent odontogenic keratocysts. *J Oral Pathol* 1987;16:124-28.
11. El-Hajj G, Anneroth G. Odontogenic keratocysts - a retrospective clinical and histological study. *Int J Oral Maxillofac Surg* 1996;25:124-29.
12. Vedtofte P, Praetorius F. Recurrence of the odontogenic keratocyst in relation to clinical and histological features. *Int J Oral Surg* 1979;8:412-20.
13. Forssell K. The primordial cyst: a clinical and radiographic study (Thesis). *Proc Finn Dent Soc* 1980;76:129-74.
14. Dayan D, Buchner A, Gorsky M, Harel-Raviv M. The peripheral odontogenic keratocyst. *Int J Oral Maxillofac Surg* 1988;17:81–3.
15. Morgan TA, Burton CC, Qian F. A retrospective review of treatment of the odontogenic keratocyst. *J Oral Maxillofac Surg* 2005;63:635–9.
16. Meiselman F. Surgical management of the odontogenic keratocyst: conservative approach. *J Oral Maxillofac Surg* 1994;52:960–3.
17. Dammer R, Niederdellmann H, Dammer P, Nuebler-Moritz M. Conservative or radical treatment of keratocysts: a retrospective review. *Br J Oral Maxillofac Surg* 1997;35:46–8.
18. Stoelinga PJ. Long-term follow-up on keratocysts treated according to a defined protocol. *Int J Oral Maxillofac Surg* 2001;30:14–25.
19. Madras J., Lapointe H. Keratocystic Odontogenic Tumour: Reclassification of the Odontogenic Keratocyst from Cyst to Tumour. *JCDA March* 2008;74:165.

**Source of Support:** Nil; **Conflict of Interest:** None

**Submitted:** 10-12-2015; **Published online:** 31-12-2015