

A Study Evaluating Xanthelasma Palpebrarum Clinically and Biochemically

Rohit Aggarwal¹, Praveen Kumar Rathore²

ABSTRACT

Introduction: Xanthelasma palpebrarum refers to lipid deposition that occurs on eyelids and inner canthi. It may be associated with certain systemic conditions. Present study was done to know / understand about the relationship between xanthelasma and lipid profile.

Material and Methods: In this type of Case control study, 30 cases with Xanthelasma palpebrarum and 30 healthy individuals of similar age group were selected. All cases and controls underwent clinical examination and fasting lipid profile study with written consent. A detailed history was taken from the patients about the lesions, with respect to age of onset, duration of lesion, progression of lesion etc. All cases underwent lipid profile study in empty stomach.

Result: Total cholesterol levels were increased in 53.34% (16cases) as compared to 10 controls (30%), making it highly significant, triglycerides levels were increased in 19cases (63.34%) as compared to 8 controls (26.67%) . No significant relationship was observed with respect to other cholesterol parameters.

Conclusion: This study showed that there is a significant elevation in total cholesterol and triglycerides in Xanthelasma palpebrarum patients as compared to controls, thus making lipid profile compulsory for all patients with Xanthelasma.

Keywords: Xanthelasma palpebrarum (XP), Lipid profile

INTRODUCTION

Xanthelasma palpebrarum (XP) refers to xanthoma that occurs on eyelids and inner canthi. The term 'Xanthoma' means 'yellow tumour' i.e. deposition of fat or lipid over the eyelids and around the eye.¹ It was Erasmus Wilson² who first coined the term xanthelasma nearly more than 100 years ago. Xanthelasma is derived from two Greek terms "xanthos" (yellow) and "elasma" (beaten metal plate). The commonest type of cutaneous xanthoma, is Xanthelasma palpebrarum. It's symmetrical, bilateral and permanent. XP is highly associated with atherosclerosis, cardiovascular disease, diabetes, obesity and pancreatitis.¹ Xanthelasma usually is seen in the 3rd – 5th decade, more commonly seen in women than in men. These xanthomas are yellowish in colour and are soft, velvety lesions on the eyelids.¹ The exact cause is not known however any disturbance in the lipid metabolism contributes to its etiopathogenesis.³ Type V Hypolipoproteinemia often result in deposition of cholesterol in the skin. The risk of Coronary Artery Disease is more commonly associated with individuals presenting with XP than without XP.⁴ The LDL accumulated in the blood, lines along the wall of capillary blood vessels. When biochemical lipid profiles are considered for patients presenting with XP, it is noticed that there is a higher level of LDL and VLDL cholesterol and lower level of HDL cholesterol which is an important predictor for Coronary Artery Disease (CAD).⁵

Present study aimed to understand the relationship between xanthelasma and lipid profile.

MATERIAL AND METHODS

Study design: A descriptive case control study was conducted from Sept 2015 to Feb 2016 in the department of Dermatology, Rohilkhand Medical College and Hospital, Bareilly. Sample was selected based on the inclusion and exclusion criteria. Prior to the study an informed consent was obtained from the patients.

Inclusion Criteria: Patients attending Dermatology O.P.D. with xanthelasma palpebrarum. Patients of the age group 25-70 years of both sexes willing to undergo lipid profile test were included in the study. Similarly the age matched and disease free subjects taken as control group.

Exclusion criteria: Patients not willing for lipid test.

Grouping: Group A consisted of age and sex matched 30 Controls without Xanthelasma Palpebrarum and Group B consisted of 30 Cases with Xanthelasma Palpebrarum. All were subjected to undergo lipid profile test after which the study was carried.

Methodology: A detailed history was taken from all the 30 patients regarding the skin lesion, in respect to appearance and duration of lesion. Past history regarding any systemic conditions like hypertension, diabetes mellitus, hyperlipidemia and their respective form of treatment were taken into account. Family history of xanthomas was also noted. General and systemic examination was also done for all cases. All subjects underwent a detailed cutaneous examination and morphology of the lesion in the eyelids was noted. All cases (subjects and controls) underwent lipid profile study (Total cholesterol, LDL cholesterol, HDL cholesterol, VLDL) in empty stomach. From each patient (Control and Case) 2ml of blood was collected aseptically and serum was separated by centrifugation. Within 24 hours, the sample was analyzed for lipid profile and the data was entered.

STATISTICAL ANALYSIS

Collected data was analyzed by t test and chi-square test with the help of SPSS version 21.

¹P.G. 3rd year, ²Professor, Department of Dermatology, Rohilkhand Medical College and Hospital, Bareilly, Uttar Pradesh, India

Corresponding author: Room no. 24, PG/ Interns hostel, Pilibhit bypass road, Rohilkhand medical college and hospital campus, Bareilly (U.P.) 243001, India

How to cite this article: Rohit Aggarwal, Praveen Kumar Rathore. A study evaluating xanthelasma palpebrarum clinically and biochemically. International Journal of Contemporary Medical Research 2016;3(9):2565-2567.

RESULT

Total cholesterol levels were increased in 53.34% (16cases) as compared to 10 controls (30%) making it highly significant. Triglycerides levels were increased in 19 cases (63.34%) as compared to 8 controls (26.67%) . No significant relationship was observed with respect to other cholesterol parameters. Table-1 shows that total of 8 patients reported with diabetes mellitus, 7 with hypertension and 15 had no illness. Figure-1 shows that there were 16.67% of males and rest were females in the sample.

DISCUSSION

Our study showed a female preponderance with 25 females (80.95%) and 5 males (19.04%) among the 30 cases. Female to male ratio of 5:1 was observed. This was in accordance with the study done by Jain et al⁶, Gangopadadhyia et al⁷, Epstein et al⁸ and Pedace et al.⁹ Reddy et al found a peak incidence in the age group of 31-40 years. Gangopadadhyia et al⁷ noted that highest number of cases (30%) were in the age group of 31- 40 years. Jain et al⁶ also observed that majority of the patients were in the age group of 31- 50 years (37.9%). Chhetri et al.¹⁰ observed a peak in the age group of 40- 50 majority of the cases i.e. 40% came in the age group of 30- 40 years

Gangopadadhyia et al reported Diabetes Mellitus (DM) in 20% of patients, Hypertension (HTN) in 32.5% and xanthoma in 2.5% of patients.⁷ In study by Jain et al 42.4% of patients had associated systemic diseases like HTN and DM. Epstein et al reported a history of HTN in 28.6% cases. Incidence of DM associated with XP was reported to be 6% by Ribera et al and 34.2% by Vacca et al . In our study Hypertension was seen in 8 cases (26.7%) and Diabetes Mellitus was seen in 7 cases (23.34%) and 11 of the 30 cases had no illness. Jain et al reported 72.7% had both eyelids involvement.⁶ Chhetri et al reported bilateral lesions in 39% cases, two eyelids involvement in 53.2% cases. Ribera et al reported 42.6% in both the eyelids.¹¹ Examination in our study showed that 19 cases (63.34%) had bilateral lesions and that majority of xanthelasma were found near the medial canthus of the eyelids, 11 cases (36.67%). Tursten et al¹² reported that clinically xanthelasma are usually plaque like yellow lesions. Chhetri et al observed that the lesion was yellowish in colour, flat topped and slightly raised from the surface. Whereas in our study, we have noticed that plaque like lesions were more commonly seen than the papular type of lesions. Comparison of total cholesterol and XP showed 16 cases (53.34%),making it highly significant.

Gangopadadhyia et al showed 40% patients (significant) and Pedace et al⁹ showed 59.8% patients as significant. Comparison of triglycerides and XP in our study showed increased triglycerides levels in 14cases (63.34%) which was statistically significant.

Our study showed a decrease in HDL cholesterol in 6 cases (20%) which is non-significant. This was in accordance with the study done by Ribera et al¹³ with 31.3% (significant) values. Jain et al⁶ observed a significant increase in VLDL levels in patients with XP as compared to controls. In our study VLDL cholesterol were increased in 5 cases (16.67%). This shows that in our study along with the concordance of other articles that total cholesterol levels and triglycerides levels were not only high but were highly statistically significant. This proves that

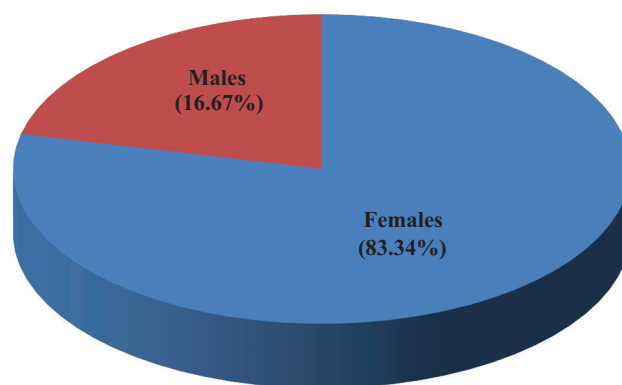


Figure-1: Sex distribution in cases

Comorbid condition	No. of patients	Percentage
Diabetes mellitus	8	26.67
Hypertension	7	23.34
No illness	15	50

Table-1: Comorbid conditions

there is a correlation between the total cholesterol levels and LDL levels with individuals presenting with XP in the OPD with or without systemic involvement. The HDL levels are lower and there is an increase in the VLDL levels, but there seems to be no statistically significant making these lipid values insignificant in relationship with XP. Therefore in this current study there was a correlation of XP with total cholesterol and triglycerides values and this by itself can be a potential risk and an indicator for atherosclerosis and CAD.

CONCLUSION

This study shows that there is a significant elevation in total cholesterol and triglycerides cholesterol in Xanthelasma palpebrarum patients as compared to controls, thus making lipid profile compulsory for all patients with Xanthelasma. Females were most commonly affected than males. Most of the cases were in the age group of 30-40 years. Hypertension and diabetes mellitus are the two commonly associated Comorbid illnesses.

ACKNOWLEDGEMENT

It is with the sense of accomplishment and deep gratitude that we dedicate our work to all those who have been instrumental in its completion. We are thankful to the cooperative patients who have helped us in this study, our faculty and staff of RMC and H, Bareilly- for their timely help, support and constant in our work. We would like to thank our family members for their blessings and guidance.

REFERENCES

1. IADVL text book of Dermatology, R.G.Valia, third edition, Mumbai, Bhalani publishing house, 2001;2:1300-01.
2. Bergman R. The pathogenesis and clinical significance of xanthelasma palpebrarum. *J Am Acad Dermatol.* 1994;5: 236-42.
3. S, Sahin S, Tokgozoglu L. Xanthelasma palpebrarum and its relation to atherosclerotic risk factors and lipoprotein(a). *Int J Dermatol.* 2008;47:785-9.
4. Reddy SNB, Singh G, Pandey SS, Tiwari D. Clinical and Lipid profile studies in xanthelasma palpebrarum. *Indian J Dermatol Venereol Leprol.* 1983;49:127-31.
5. Watanabe A, Yoshimura A, Wakasugi T, Tatami R, Ueda K,

- Ueda R et al. Serum lipids, lipoprotein lipids and coronary heart disease in patients with xanthelasma palpebrarum. *Atherosclerosis*. 1981;38:283-90.
6. Jain A, Goyal P, Nigam PK, Gurbaksh H, Sharma RC. Xanthelasma palpebrarum clinical and biochemical profile in tertiary care hospital of Delhi. *Indian J Clin Biochem*. 2007;22:151-3.
 7. Gangopadadhy DN, Dey SK, Chanda M, Pal D, Chaudhuri S. Serum lipid profile in xanthelasma. *Indian J Dermatol*. 1998;43:53-7.
 8. Epstein NN, Rosenman RH, Gofman JW. Serum lipoproteins and cholesterol metabolism in xanthelasma. *AMA Arch Derm Syphilol*. 1952;65:70-81.
 9. Pedace FJ, Winkelmann RK. Xanthelasma palpebrarum. *JAMA*. 1965;193:893-4.
 10. Chhetri MK, Chowdhury ND, De B. Xanthelasma palpebrarum: An analysis of 141 cases. *J Assoc Physicians India*. 1967;15:405-12.
 11. Ribera M, Pinto X, Argimon JM, Fiol C, Pujol R, Ferrandiz C. Lipid metabolism and apolipoprotein E phenotypes in patients with xanthelasma. *Am J Med*. 1995;99:485-90.
 12. Vacca JB, Knight WA Jr, Broun GO Sr. Clinical observations regarding xanthelasma. *Ann Intern Med*. 1959;51:1019-31.
 13. Tursen U, Eskandari G, Kaya TI, Tamer L, Ikizoglu G, Atik U. Apolipoprotein E polymorphism and lipoprotein compositions in normolipidaemic xanthelasma patients. *JEur Acad Dermatol Venereol*. 2006;20:260-3.

Source of Support: Nil; **Conflict of Interest:** None

Submitted: 08-07-2016; **Published online:** 27-08-2016