# Herpes Zoster Induced Osteonecrosis of Mandible: Case Report

M. Chandra Sekhar[1], Gandham Meghana[2], Y. Mercy Sravanthi[3], D. Suresh[4]

**ABSTRACT**

Herpes zoster infection (HZI), commonly known as Shingles or Zona, is a viral disease characterized by painful skin rashes and blisters with unilateral distribution. The virus becomes latent, usually in the ganglia of the cranial nerves. Herpes zoster infection has been observed in immunocompromised conditions. Postherpetic neuralgia, a morbid sequela of HZI, is a neuropathia resulting from peripheral and central nervous system injury and altered central nervous system processing. HZI of mandibular nerve with osteonecrosis and exfoliation of teeth is a rare phenomenon. This report presents such an unusual complication of HZI.

**Keywords:** Herpes Zoster Infection, Post Herpetic Neuralgia, Osteonecrosis, Tooth Exfoliation.

## INTRODUCTION

Primary infection with Varicella zoster virus (VZV), an α-herpesvirus, leads to varicella (chicken pox). After the initial infection with VZV, the virus can become latent in the nerve cell bodies and less frequently in non-neuronal satellite cells of the dorsal root, cranial nerve or autonomic ganglion, without causing any symptoms.[1,2] Reactivation produces herpes zoster infection (HZI), commonly called shingles. The incidence of HZI increases with age and the degree of immunosuppression.[3] There are 1.5 to 3 cases of HZI per 1,000 subjects; this increases to 10 per 1,000 in those over age 75 years. Therefore, it is not uncommon to see HZI in the elderly, in patients undergoing cancer chemotherapy, in patients on chronic immunosuppressive drug therapy (such as those who have received organ transplants), and in patients with AIDS. Transmission is usually by the respiratory route, with an incubation period of 2 to 3 weeks. As with HSV, this virus is cytopathic to the epithelial cells of the skin and mucosa, causing blisters and ulcers. Usually, oral vesicles appear after skin lesions. Oral vesicles rupture and coalesce as large mucosal erosions.[4] Postherpetic neuralgia (PHN), a complication of HZI, is a neuropathia precipitated by peripheral and central nervous system injury and altered central nervous system processing.

## CASE REPORT

A 54-year-old man, came to the oral medicine and radiology department, complaining of pain in the right side of jaw the since 20 days. The patient's history revealed that herpes zoster infection had arisen in the third division of the trigeminal nerve on right side 2 months back with single blister initially and later number of blisters increased in number. Pain in the right side of face which is insidious, burning type, continuous in nature and tingling sensation present. The patient had been treated with intravenous acyclovir, NSAIDS and antibiotics for the same. He observed loosening and spontaneous teeth exfoliation (central incisor, lateral incisor, canine and first premolar) on right side 20 days back and the bone got exposed in the same region. Patient had history of uncontrolled diabetes for nine years and on general examination patient was moderately built and nourished.

Extra oral examination revealed facial brownish black scar and hyperpigmentation on the right side of the face restricted to the mandibular division of trigeminal nerve dermatome extending anterio -posteriorly from 2cm away from corner of mouth to tragus of right ear, superior inferiorly 4cm away from right eye to 4cm away from angle of mandible (figure 1). Tenderness on palpation of the facial scar.

Intraoral examination revealed exposed necrotic alveolar bone in the mandibular right alveolus, buccal mucoperiosteum of 41,42,43,44, missing 41,42,43,44 teeth, sockets of the exfoliated teeth were devoid of blood clots. (Figure 2) and on palpation surface texture was rough with sharp edges. The remaining teeth (45,46) were mobile in the affected quadrant.

Histopathological report showed empty osteocytic lacunae, altered trabecular pattern

Based on the history, clinical, radiographic and histopathology features, a diagnosis of osteonecrosis and tooth exfoliation following HZI was made. Debridement of the necrotic bone was performed under local anaesthesia and the affected teeth were removed. As postoperative medication, Augmentin 625 mg was prescribed for 5 days, gabapentin 300mg was prescribed for 15 days and capsaicin cream for application over right side of face 4 to 5 times and chlorhexidine mouth wash were prescribed. After sequestrectomy, the surgical site was healed with reduction of pain in the right side of face (figure 4)

[1]Professor and HOD, Department of Oral Medicine and Radiology, Government Dental College and Hospital, Kadapa, Andhra Pradesh, [2]PG Student, Department of Oral Medicine and Radiology, Government Dental College and Hospital, Kadapa, Andhra Pradesh, [3]Assistant Professor Department of Oral Medicine and Radiology, Government Dental College and Hospital, Kadapa, Andhra Pradesh, [4]Assistant Professor, Department of Oral Medicine and Radiology, Government Dental College and Hospital, Kadapa, Andhra Pradesh, India

**Corresponding author:** Dr. Gandham Meghana, Department Of Oral Medicine and Radiology, Government Dental College and Hospital, Kadapa, Andhra Pradesh, 516001

**How to cite this article:** Sekhar MC, Meghana G, Sravanthi YM, Suresh D. Herpes zoster induced osteonecrosis of mandible: case report. International Journal of Contemporary Medical Research 2022;9(5):E9-E11.

**Figure-1:** Extraoral view showing facial scarring and hyperpigmentation post-herpes

**Figure-2:** Intraoral examination, showing extensive necrosis of the labial, buccal mucoperiosteum

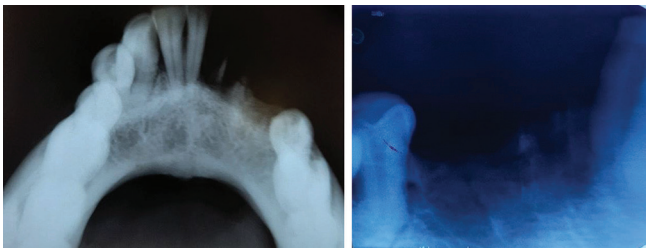

**Figure-3:** The occlusal radiograph(A) and IOPA (B) showed altered trabecular patter, missing 41,42,43,44 and outlines of the sockets of exfoliated teeth.

**Figure-4:** The Panoramic radiograph showed no lytic changes, missing 41,42,43,44 and outlines of the sockets of exfoliated teeth

## DISCUSSION

Herpes zoster is a sporadic disease. varicella-zoster virus

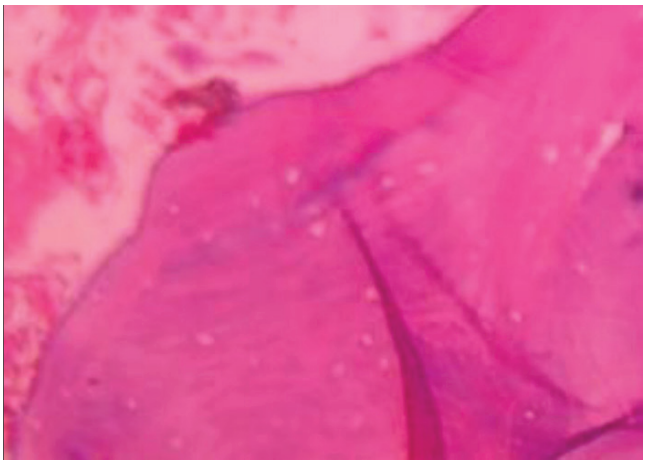

**Figure-5:** Necrotic bone trabeculae showing loss of osteocytes

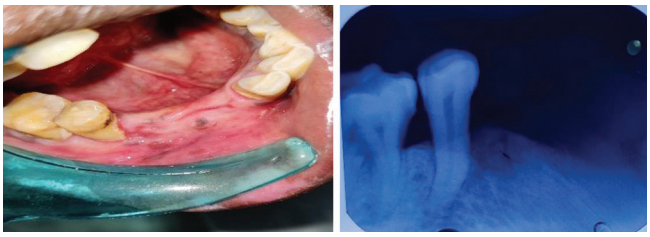

**Figure-6:** Postoperative intraoral view and IOPA after one month follow up showed healed surgical site.

(VZV) becomes reactivated, causing lesions of localized HZ. The most commonly affected nerves with HZ are C3, T5, L1, L2, and the trigeminal nerve. Post herpetic neuralgia occurs in 9–19% of all HZ patients. Incidence of PHN is age dependent: the risk of PHN is ~35% in those over the age of 80 years, ~20% in those older than 50 years, low (2%) in patients younger than 50 years of age.[5] The incidence of HZ is more in elderly males and increases with age or on the degree of immunosuppression. Triggering factors include stress or local trauma, diminished immune response or in association with malignancies, chronic hepatitis, polymyalgia rheumatica, acute rheumatic fever.[6,7] The increasing frequency of HZI with age has been suggested to be due to the disappearance of zoster-neutralizing antibodies which usually persist for 40 years after the original attack of chickenpox. There is a slight predilection for post- HZI osteonecrosis in the mandible compared to the maxilla.[8]

The pathogenesis of alveolar necrosis is still controversial. Two hypotheses are present. One viable explanation is ischemia. Vasculitis induced by the Varicella zoster virus may lead to necrosis of the periodontal tissue and alveolar bone.[6,9] Another possible reason is that the oedema due to inflammation of the alveolar nerve in maxillary or mandibular canal cause compression of alveolar artery resulting in ischemia and subsequent necrosis of the periodontal tissue and alveolar bone.[10] In addition, if any pre-existing pulpal and periodontal infection may contribute to the mechanism.[9] Another explanation is by bacterial invasion through acantholysis and blistering of the mucosa in the affected region caused by VZV. In an immunocompromised patient a long-lasting mucosal ulcer provides portal for actinomycete

and staph variants to invade, inhabit, and form osteomyelitis. Infections occur unilaterally almost exclusively in middle-aged and elderly patients and may cause significant distress mainly because of the neuralgia that accompanies and may persist after skin eruption. Mandibular alveolar bone necrosis associated with Herpes zoster infection is rare.

Jaw osteonecrosis clinically appears as stripping of bone with exposure of teeth sockets. Panoramic radiographs may reveal sequestrations of the necrotizing bone and empty teeth sockets and rarely underlying bone shows "moth-eaten" appearance.[11]

HZI is treated by administering the antiviral drugs within 72 hours after onset of rash.[12] Topical antiviral agents such as 0.5% acyclovir cream and docosanol 10% cream five times a day.[12] Oral administration includes acyclovir 800 mg orally 5 times daily for 7-10 days or in severe cases 10 mg/kg IV every 8 hours for 7-10 days is recommended.

Acute pain associated with PHN is treated by orally administered anticonvulsants such as phenytoin; 100-300 mg orally at bedtime; carbamazepine 100 mg orally at bedtime; gabapentin 100-300 mg orally at bedtime.[12]

## CONCLUSION

Herpes zoster infection is a common viral infection with a wide range of oral manifestations. In immunocompromised and older patients, the clinicians should consider HZI as a possible cause of tooth mobility, exfoliation, and alveolar osteonecrosis, which needs early intervention to prevent complications.

### Authors' contributions

All authors read and approved the final manuscript.

### Consent

All authors declare that written informed consent was obtained from the patient (or other approved parties) for publication of this case report and accompanying images.

## REFERENCES


1. Johnson RW, Dworkin RH. Clinical review: Treatment of herpes zoster and postherpetic neuralgia. BMJ. 2003;748-50.
2. Kennedy PG. Varicella-zoster virus latency in human ganglia. Rev Med Virol 2002; 12 (5): 327–34.
3. Akintoye, SO, Greenberg MS. Recurrent aphthous stomatitis. Dent Clin North Am 2005;49:31
4. Arora PC, Manchanda AS, Narang RS, Arora A. Mandibular osteonecrosis and teeth exfoliation after herpes zoster infection in an HIV-inflicted individual. J Indian Acad Oral Med Radiol 2015;27:101-4
5. Hope-Simpson RE. Postherpetic neuralgia. J R Coll Gen Pract 1975; 25: 571–575.
6. Mendieta C, Miranda J, Brunet LI, Gargallo J, Berini L. Alveolar bone necrosis and tooth exfoliation following herpes zoster infection: a review of the literature and case report. J Periodontal 2005; 76(1): 148-53.
7. Manz HJ, Canter HG, Melton J. Trigeminal herpes zoster causing mandibular osteonecrosis and spontaneous tooth exfoliation. South Med J 1986;79:1026-8
8. Owotade FJ, Ugboko VI, Bamidele K. Herpes zoster infection of maxilla. J Oral Maxillofac Surg 1999; 57(10): 1249-51.
9. Volvoikar P, Patil S, Dinaker A. Tooth exfoliation, osteonecrosis and neuralgia following herpes zoster of trigeminal nerve. Ind J Dent Res 2002; 13(1): 11-14.
10. Peterslund NA. Herpesvirus infection: an overview of the clinical manifestations. Scand J Infect Dis Suppl 1991; 80(23): 15–20
11. Mahima VG, Patil K, Srikanth HS. Herpes zoster induced alveolar necrosis in an immunocompetent patient. Iranian J Clin Inf Dis 2010; 5(4): 235-8.
12. Dworkin RH, Johnson RW, Breuer J, Gnann JW, Levin MJ, Backonja M, et al. Recommendations for the management of herpes zoster. Management of herpes zoster. Clin Infect Dis. 2007;44(1):S1-26.


**Source of Support:** Nil; **Conflict of Interest:** None

**Submitted:** 25-03-2022; **Accepted:** 28-04-2022; **Published:** 31-05-2022