A Rare Case of Partial Molar Pregnancy in a Caesarean Scar – A Case Report

Padmavathy[1], Asma Siddiqua[2]

ABSTRACT

Introduction: Caesarean scar ectopic pregnancy is a rare type of ectopic pregnancy with a frequency of 1:1800 to 1:2216 pregnancies which may lead to uncontrollable hemorrhage and hemorrhagic shock. Here we report a rare case of molar pregnancy in a cesarean scar.

Case Report: A 27year old Gravida 4, Para 2, Live 2, Abortion 1 presented to the hospital with irregular vaginal bleeding and sonography revealing gestational sac in the lower uterine segment with cervix and uterus empty and no myometrial thinning. Impression was given as possibility of scar ectopic cannot be ruled out. Emergency laparotomy and scar site ectopic excision was done and sample sent for histopathological examination revealed diagnosis of Partial Hydatidiform mole in a Cesarean scar.

Conclusion: Cesarean scan pregnancy is difficult to diagnose and must be considered in patients with history of previous cesarean section with complaints of irregular vaginal bleeding. Molar pregnancy in a cesarean scar is even more rare and therefore all the ectopic pregnancies should be sent for histopathological examination for ruling out molar pregnancy and to prevent further complications due to risk of transformation to Invasive mole and Choriocarcinoma.

Keywords: Caesarean Section Scar Ectopic, Molar Pregnancy, Histopathological Examination, Invasive Mole, Choriocarcinoma.

INTRODUCTION

Gestational Trophoblastic Diseases (GTD's) includes a range of pregnancy related disorders of Complete, Partial and Invasive Hydatidiform moles of which Invasive moles are premalignant. Other disorders under GTD's includes benign trophoblastic tumor like lesions of Exaggerated Placental Site reaction and Placental Site Nodule and neoplastic trophoblastic tumors of Choriocarcinoma and rare Placental Site Trophoblastic Tumor (PSTT) and Epithelioid Trophoblastic Tumor (ETT).

Incidence Rates of Hydatidiform moles is estimated to be 7.5 per 10000 at 1% of pregnancies[1] of which incidence of Partial Mole is frequent. i.e., 1:695 compared to 1:1945 for Complete Mole[2].

Cesarean scar ectopic pregnancy and molar pregnancies are two very rare pathologies related to obstetrics with serious morbidities involved; requiring careful management in both the cases. The co-existence of these two rare entities is far more rare with high risk of uncontrolled hemorrhage or uterine rupture[3].

Ectopic molar pregnancy in a cesarean scar was reported as very rare with incidence of one per million pregnancies.

Here, we report an extremely rare case of partial molar pregnancy in a caesarean scar that was diagnosed and managed at our tertiary care hospital.

CASE REPORT

A 27yrs old Gravida$_4$ Para$_2$ Live$_2$ Abortion$_1$ with two previous Lower Segment Cesarean Section(LSCS) with last child birth-2yrs back presented to the hospital with amenorrhoea for 49days(7 weeks) and vaginal spotting for 10 days on and off. She had last child birth 2yrs ago which was by caesarean section.

On admission, she complained of mild pain in abdomen and irregular vaginal bleeding/spotting since 10 days. On examination, external cervical OS was closed with no adnexal tenderness.

Pelvic sonogram/Transvaginal Sonography revealed single gestational sac with single fetal pole with Crown-Rump Length corresponding to 7 weeks 3 days seen in lower segment. Scan also revealed cervical length measuring approximately 3cms with internal OS closed with evidence of tiny anechoic lesion with irregular borders in subendometrial location in anterior myometrial wall.

Mild endometrial fluid collection also noted in sonogram, scan also showed good Fetal Heart Rate.

Follow up sonography after 2 days revealed Gestational sac in lower uterine segment with cervix and uterus empty and no myometrial thinning. Radiologically it was given as possibility of scar ectopic cannot be ruled out. Serum Beta-HCG levels done showed value of 65,244mIU/ml. Sequential Beta-HCG levels are given in [table 1].

Emergency laparotomy with scar site ectopic excision along with sterilization was done and gestational sac and myometrium were sent for histopathological examination fixed in formalin (10% neutral buffered formalin).

Grossly, we received multiple grey brown soft tissue bits with a bit suspected to be a sac (not clearly identified) measuring 0.7x0.5x0.2cms with cut section showing grey

[1]Professor, Department of Pathology, [2]Post Graduate, Year II, Department of Pathology, Modern Government Maternity Hospital, Petlaburz, Hyderabad, India

Corresponding author: Dr. Asma Siddiqua, 17-9-179/B/2, kurmaguda, Saidabad, Hyderabad, 500059, India

How to cite this article: Padmavathy, Siddiqua A. A rare case of partial molar pregnancy in a caesarean scar – a case report. International Journal of Contemporary Medical Research 2021;8(7):G1-G3.

DOI: http://dx.doi.org/10.21276/ijcmr.2021.8.7.11

white areas. We also received multiple friable grey brown tissue measuring 1x0.5cms.

The specimen was fixed in 10% neutral buffered formalin and grossing of the specimen was done and gross bits were given. 2 bits were given from suspected gestational sac and 1 bit from friable grey brown tissue was given and the entire tissue was submitted for tissue processing and paraffin wax embedding. Two micro sections of 4-5 micron thickness were prepared from the corresponding paraffin blocks, one on albumin coated slide for Hematoxylin and Eosin staining and the other on poly-L-lysine coated slide for Immunohistochemical staining.

Appropriate controls were used for the antibody. Immunohistochemical staining for P_{53} and P_{57} antibody was done.

Microscopically Histopathological examination of the tissue revealed the following:

A) Sections from suspected gestational sac showed bundles of uterine myometrial smooth muscles arranged in interlacing fascicles with adjacent areas of endometrial glands and mucinous areas also noted with few interspersed avascular immature Chorionic Villi and large convoluted congested blood vessels.

B) Sections from friable grey brown bits of tissue revealed two population of villi:

1)Hydropic avascular edematous chronic villi of varying sizes with cistern formation, some of them showing scalloping lined by inner layer of cytotrophoblast and outer layer of syncytiotrophoblast showing circumferential trophoblastic proliferation and 2)Smaller fibrotic villi. Mild cytological atypia is also noted. Areas of hemorrhage and fibrinoid necrosis also seen. Nucleated RBC's are also noted. Impression was given as, Features suggestive of → Molar Pregnancy – Partial Hydatidiform Mole in a caesarean scar.

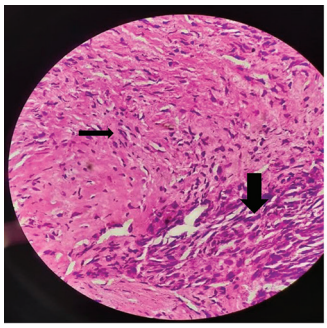

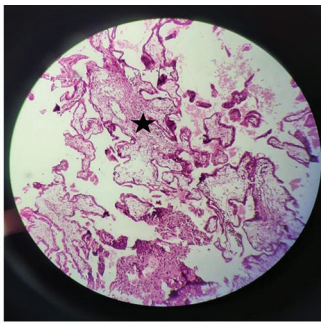

Trophoblast ⬇ invading the uterine myometrium ➡ at the caesarean scar site.

★ Indicates hydropic chorionic villi.

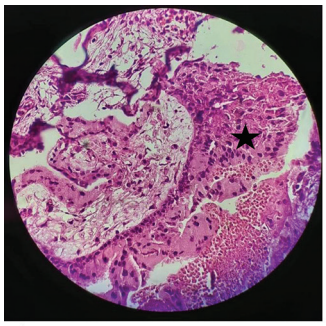

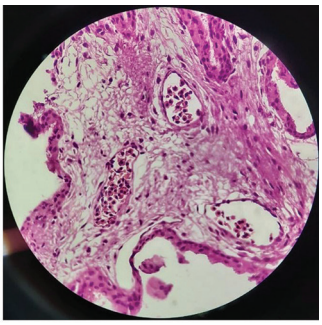

★ Indicates circumferential trophoblastic proliferation.

Nucleated RBC's seen inside chorionic villous capillaries.

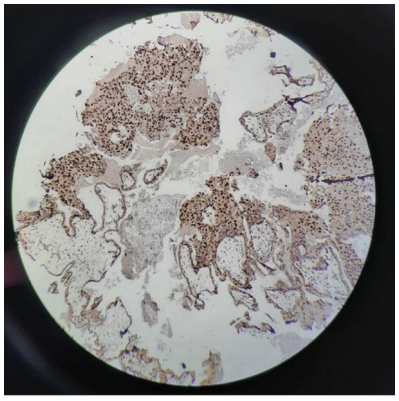

P_{57} nuclear positivity seen in villus stomal cells and trophoblasts.

	Beta-HCG levels
7 weeks gestational age	65,244
2 weeks after ectopic excision	117
3 weeks after ectopic excision	16
5 weeks after ectopic excision	1.4

Table-1: Sequential beta-hcg levels with corresponding gestational age:

Author reference	Age	Clinical presentation	HCG levels (IU/L)	Histopathology
Wu et al, 2006[4]	31	Persistent symptoms	61798	Partial hydatidiform mole
Michener et al, 2009[5]	33	Vaginal hemorrhage	161	Type of molar pregnancy not specified
Jin et al, 2011[2]	44	Vaginal bleeding, lower abdominal pain	94724	Partial hydatidiform mole
Ko et al, 2012[6]	34	Persistent symptoms of pregnancy	21925	Partial hydatidiform mole
Kaluarachchi et al, 2013[7]	40	Asymptomatic	6743	Complete hydatidiform mole
Vimercati et al, 2016[8]	34	Abdominal pain and vaginal bleeding	51547	Invasive hydatidiform mole
Ling et al, 2018[1]	28	Abdominal pain, vaginal bleeding, amenorrhea	7984	Partial hydatidiform mole
Hao-Ru Jiang et al, 2020[3]	35	Vaginal bleeding, menopause	1515540	Invasive hydatidiform mole
Present case, 2021	27	Amenorrhoea and vaginal spotting	65000	Partial hydatidiform mole

Table-2: Summary of all the cases reported in literature of ectopic molar pregnancy in a cesarean section scar:

IHC was done for P_{53} and P_{57}. P_{53} was negative and P_{57} was positive. Its expression was seen in villous stromal cells and cytotrophoblasts. Internal positive control requirement was fulfilled by syncytiotrophoblast cells. P_{57} is a nuclear stain.
Thus the patient was confirmed to have ectopic partial molar pregnancy in a caesarean scar.
Patients serum Beta-HCG levels were monitored regularly until the levels gradually returned to normal.

DISCUSSION

Ectopic molar pregnancy in a cesarean scar as noted in our case is an exceedingly rare condition with high risk of hemorrhage and uterine rupture[3]. Established risk factors include advanced maternal age, previous caesarean sections and previous history of molar pregnancy.
Extremely low incidence of this entity made us search for it in the literature for the fear of overdiagnosis and we could find only 8 cases to date. The case reports on reviewing of literature including our present case are listed in the table 2.
Wu et al reported the first case of molar pregnancy in a cesarean scar ectopic pregnancy in 2006 – A 31yr old gravida 8 para 1 female patient with complains of vaginal bleeding after a miscarriage at 7 weeks 2 days from last menstrual period with Transvaginal sonography revealing a gestational sac with irregular surface surrounded by heterogenous placenta with multicystic spaces with Beta-HCG levels of 61,798. Careful dilatation and suction curettage was done under Ultrasonographic guidance and diagnosis of partial hydatidiform mole was confirmed histologically.
The latest case in the literature was reported in world journal of clinical cases in April 2020 by Hao-Ru Jiang et al wherein a 35 year old woman, gravida 4, para1, complained of vaginal bleeding and amenorrhoea with serum Beta-HCG levels of 4287800IU/L. Patient underwent suction evacuation and histopathological examination revealed Hydatidiform mole in a cesarean scar.
Our patient was admitted to the hospital with amenorrhoea of 7 weeks and vaginal spotting for 10 days on and off with history of cesarean section 2 years back. Ultrasonography revealed gestational sac in lower uterine segment with cervix and uterus empty and radiologically initial diagnosis was made as possibility of cesarean scar ectopic pregnancy cannot be ruled out. The incompatible value of Beta-HCG level with the corresponding gestational Age of 7 weeks made us suspect for caesarean scar ectopic molar pregnancy which was confirmed on histopathological examination. Various modalities used in the treatment of cesarean scar pregnancy include, Systemic or direct methotrexate injection, resection of scar site by laparotomy or laparoscopy, dilatation and curettage, curettage by hysteroscopy and uterine artery embolization or a combination of these modalities.

CONCLUSION

Caesarean scar ectopic pregnancy results in high risk of maternal morbidities that includes severe uncontrolled Hemorrhage, uterine rupture and increased risk of transformation to invasive mole or Choriocarcinoma. These are very rare entities and molar pregnancy in the cesarean scar is a challenging diagnosis and hard to diagnose preoperatively and Histopathological examination is mandated in every case of cesarean scar ectopic pregnancy with abnormal increase in HCG levels and should be suspected early in pregnancies with a prior cesarean section. Early diagnosis and treatment may be life saving in such rare cases.

REFERENCES

1. Ling C, Zhao J, Qi X. Partial molar pregnancy in the cesarean scar: A case report and literature review. Medicine (Baltimore) 2018; 97: e11312.
2. Jin FS, Ding DC, Wu GJ, Hwang KS. Molar Pregnancy in a Cesarean Section Scar of Uterus. J Med Sci 2011; 31: 173-176.
3. Hao-Ru Jiang, Wen-Wei Shi, Xiao Liang, Hui Zhang, Yan Tan. Hydatidiform mole in a scar on the uterus: A case report. World J Clin Cases 2020; 8: 1547-1553.
4. Wu CF, Hsu CY, Chen CP. Ectopic molar pregnancy in a cesarean scar. Taiwan J Obstet Gynecol 2006; 45: 343-345.
5. Michener C, Dickinson JE. Caesarean scar ectopic pregnancy: a single centre case series. Aust N Z J Obstet Gynaecol 2009; 49: 451-455
6. Ko JK, Wan HL, Ngu SF, Cheung VY, Ng EH. Cesarean scar molar pregnancy. Obstet Gynecol 2012; 119: 449-451.
7. Kaluarachchi C, Tissera A, Gananatha Karunarathna S. Caesarean scar site complete molar pregnancy. Sri Lanka J Obstet Gynaecol 2013; 35: 62-64.
8. Vimercati A, de Gennaro AC, Resta L, Cormio G, Cicinelli E. Sonographic and Power Doppler Evaluation of an Invasive Mole Located in a Cesarean Scar Pregnancy. J Ultrasound Med 2016; 35: 1608- 1612.

Source of Support: Nil; **Conflict of Interest:** None

Submitted: 08-06-2021; **Accepted:** 30-06-2021; **Published:** 14-07-2021