

Evaluation of Root Canal Morphology of Mandibular Central and Lateral Incisors According to Age and Gender based on Cone-Beam Computed Tomography Images

Hasan ÖZ¹, Ahmet Akay²

ABSTRACT

Introduction: Many teeth have additional canals and different canal morphologies that are considered normal. This study aimed to assess the root canal morphology of mandibular central and lateral incisors with cone-beam computed tomography (CBCT) in populations from the Southeastern Anatolia Region of Turkey.

Material and Methods: The CBCT archive records of patients who applied to Dicle University, Faculty of Dentistry, Department of Oral and Maxillofacial Radiology were retrospectively scanned. In addition, CBCT images of 300 patients (1,187 teeth in total), including at least one of mandibular central and lateral incisors that were imaged for different reasons, were included in the study. Root canal morphology was evaluated using the Vertucci classification. A chi-squared test was used to compare the frequencies and rates of the morphology types determined by the Vertucci classification according to age groups and gender.

Results: In the present study, the most common root canal morphology found in the mandibular central and lateral incisors was type I (61.92%). The frequency of the two canals in the central and lateral incisors was 38.38% in the right lateral incisor and 36.70% in the central incisor and 37.04% in the left lateral incisor and 40.20% in the central incisor.

Conclusion: Due to the two canal variations in root canal treatments performed on mandibular central and lateral incisors, including additional canals can increase the success of the treatment. Moreover, CBCT images are significantly useful in evaluating root canal morphology.

Keywords: Cone-beam Computed Tomography, Mandibular Incisor, Morphology.

INTRODUCTION

Some additional root canals may not be detected if the clinician performing root canal treatment lacks sufficient knowledge and experience about root canal anatomy or fails to properly search for additional canals. Finding these canals and including them in root canal treatment can significantly improve the prognosis of the treatment.¹

The morphology of mandibular central and lateral incisors is widely distributed in different populations.^{2,3} Studies have performed root canal morphology examinations and evaluated mandibular incisors using transparency, staining, and sectioning techniques, two-dimensional radiographic imaging, three-dimensional cone-beam computed tomography (CBCT), and micro-computed tomography (μCT).⁴⁻⁶ In addition, studies examining the morphology of

mandibular incisors have reported that a single root canal (Vertucci type I) is the most common root canal morphology, followed by a single root canal originating from the pulp that is divided into two and united in a single apical foramen (Vertucci type III).^{7,8} All morphology studies on extracted teeth have involved invasive methods. Periapical radiographs, computed tomography, CBCT, and μCT have also been used in radiographic examinations.³ Because periapical radiographs provide two-dimensional images, it is difficult to use them to detect variations, such as the presence of a second or lateral canal in the root canals.⁹

When compared to CBCT, images with higher resolution require shorter shooting times and fewer doses of radiation. In recent years, CBCT has frequently been used in dentistry for the three-dimensional imaging of teeth and the maxillofacial area. In endodontics, CBCT images can facilitate detailed examinations of the root canal system.¹⁰

In order to reveal gender- and age-related differences, our study aimed to examine the root canal morphology of mandibular central and lateral incisors in populations from the Southeastern Anatolia Region of Turkey.

MATERIAL AND METHODS

The study was approved by the Ethics Committee of the Dicle University Faculty of Dentistry (2021-5). The evaluated CBCT images were taken between 2013 and 2021 from the archive of Dicle University, Faculty of Dentistry, Department of Oral and Maxillofacial Radiology.

CBCT images (I-Cat, Imaging Sciences International, Hatfield, PA, USA) were obtained with 120 kVp 3–7 mA parameters and a voxel size of 0.30 mm. The study's inclusion criteria were the complete apexification of all teeth, teeth without large decay, and teeth without calcification in the root canals. The exclusion conditions included patients under the age of 20; the presence of any pathology in the evaluated

¹Dentist/Research Assistant, Department of Endodontics, ²Dentist/Research Assistant, Department of Endodontics, Dicle University, Diyarbakir, Turkey

Corresponding author: Hasan ÖZ, Dentist/Research Assistant, Department of Endodontics, Dicle University, Diyarbakir, Turkey

How to cite this article: ÖZ H, Akay A. Evaluation of root canal morphology of mandibular central and lateral incisors according to age and gender based on cone-beam computed tomography images. *International Journal of Contemporary Medical Research* 2021;8(4):D1-D4.

DOI: <http://dx.doi.org/10.21276/ijcmr.2021.8.4.12>



area or near the tooth roots; teeth with advanced periodontal disease; teeth with external and internal resorption in the root structure; images with any artifact that could reduce image quality; teeth with coronal restoration; teeth with root canal treatment; and intracanal post restoration. The CBCT images of 300 patients who met the inclusion criteria were evaluated using 1.187 mandibular central and lateral incisors with I-Cat version 1.6.2.0 (I-Cat Imaging Sciences International, Hatfield, PA, USA) software.

The root canal morphology teeth numbers were examined with coronal, sagittal, and axial section views. The root canal configurations were evaluated according to the Vertucci classification. The evaluation was made by two endodontic specialists after they reached an agreement on separate decisions. Patients were grouped by gender and age. The patients' age groups were determined as follows:

- Group A: ages 20–29;
- Group B: ages 30–39;
- Group C: ages 40–49;
- Group D: ages 50 and over.

In order for the study's patients to reflect the Southeastern Anatolian Turkish population, the number of patients in each group was determined using Turkish Statistical Institute (TUIK) 2020 regional population data (Table 1). Patients were randomly selected according to the numbers determined for the groups.

In addition, root canal morphologies were evaluated in eight groups according to the Vertucci root canal configurations.

- Type I: A single canal extends from the pulp chamber to the apex.
- Type II: Two separate canals leave the pulp chamber and join short of the apex to form one canal.
- Type III: One canal leaves the pulp chamber, divides into two canals within the root, and then merges to exit as one canal.
- Type IV: Two separate and distinct canals extend from the pulp chamber to the apex.
- Type V: One canal leaves the pulp chamber and divides short of the apex into two separate and distinct canals with separate apical foramina.
- Type VI: Two separate canals leave the pulp chamber, merge within the body of the root, and then re-divide short of the apex to exit as two distinct canals.
- Type VII: One canal leaves the pulp chamber, divides and then re-joins within the body of the root, and finally re-divides into two distinct canals short of the apex.
- Type VIII: Three separate canals extend from the pulp chamber to the apex.

SPSS (Version 25; IBM Inc., Chicago, IL, USA) software was used in the analysis of the data; a significance level of $p < 0.05$ was determined as significant. A chi-squared test was used to evaluate the morphological differences in different age groups and genders.

Group	South-eastern Anatolia Turkey Population n / percent	Number of Sampling in the Group
Group A	1.567.940 (%31.40)	94
Group B	1.268.677 (%25.41)	76
Group C	913.423 (%18.29)	55
Group D	1.243.347 (%24.90)	75
Total	4.993.387 (%100)	300

Table-1: Sample size in groups created according to population.

	Right Lateral (42) (n / %)	Right Central (41) (n / %)	Left Central (31) (n / %)	Left Lateral (32) (n / %)
Total Number of Teeth	297 (%100)	297 (%100)	297 (%100)	296 (%100)
Type I	183 (%61.62)	188 (%63.30)	187 (%62.96)	177 (%59.80)
Type II	54 (%18.18)	41 (%13.80)	40 (%13.47)	45 (%15.20)
Type III	58 (%19.53)	68 (%22.90)	70 (%23.57)	74 (%25.00)
Type IV	0 (%0.00)	0 (%0.00)	0 (%0.00)	0 (%0.00)
Type V	2 (%0.67)	0 (%0.00)	0 (%0.00)	0 (%0.00)

Table-2: Distribution of examined teeth according to canal morphology.

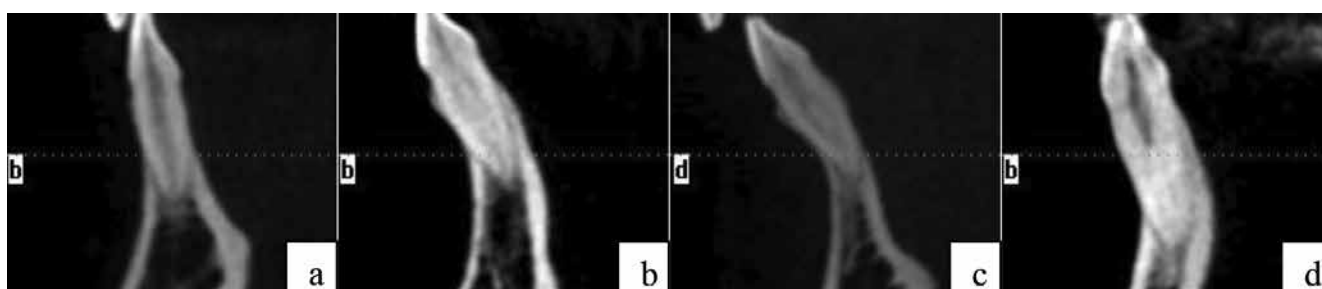


Figure-1: Teeth with Vertucci Type I (a), II (b), III (c) and V (d) morphology observed in our study

RESULTS

In our study, the root and canal morphology of 1,187 mandibular central and lateral incisors of 300 individuals (151 males, 149 females) were evaluated. All teeth were single rooted ($n = 1.187$, 100%). Additionally, 61.92% of all central and lateral incisors were observed as type I, 15.16% as type II, 22.75% as type III, and 0.17% as type V canal morphology (Table 2).

There was no significant morphological difference between age groups ($P = 0.905$) or gender ($P = 0.339$) ($P > 0.05$). In our study, the canal morphologies of the teeth were not observed in Vertucci type IV, type VI, type VII, or type VIII (Figure 1).

DISCUSSION

Completely cleaning and filling the root canal system is one of the important factors affecting the success of root canal treatment.^{11,12} That has been shown that more periapical lesions are seen in canal treatments performed on anterior teeth and maxillary molar teeth, and the reason for this is the presence of additional and unnoticeable canals in these areas.¹³ Therefore, a comprehensive assessment of root canal morphology and variations is an essential prerequisite for the success of root canal treatment.¹⁴

In studies conducted to evaluate root and canal morphology, methods such as the examination of histopathological sections, evaluations by radiographic imaging, radiographic imaging with contrast material, modified canal cleaning and staining techniques, and dental operation microscopy were used.¹⁵⁻¹⁷ Most of these methods are invasive methods that can change the canal morphology.¹⁸ Conventional radiographic imaging refers to the two-dimensional imaging of three-dimensional structures. However, it has disadvantages, such as interpretation, anatomical differences, and the overlapping of teeth and surrounding tissues.⁹ These problems can be overcome by advanced three-dimensional radiographic imaging methods, such as μ CT and CBCT, which provide in-depth anatomical information in three dimensions and facilitate the identification of abnormalities.¹⁹ CBCT is an excellent method for analyzing variations in anatomy and is used effectively in the evaluation of root and canal morphologies as it eliminates artifacts caused by overlapping anatomical structures.²⁰

Field of view (FOV) and voxel size are important in evaluating small anatomical structures, such as root canal morphology examinations, with CBCT. As the FOV size and voxel size increase, the details in image become less visible.²¹ The FOV size of the CBCT images examined in our study is 100 x 50 mm, and the voxel size is 0.30 mm; these resolution values are sufficient to evaluate root and canal morphology. In our study, the two-canal morphology was right lateral 38.38%, right central 36.70%, left central 37.04%, and left lateral 40.20%. When we compare these results with other studies conducted in the Turkish population, our results were higher than Helvacioğlu Yigit et al.'s (25.5%) and lower than Kartal and Yanikoglu's (45%), Arslan et al.'s (47.60%),

Orhan et al.'s (55.60%), and Sert et al.'s (67.75%).²²⁻²⁵ The reason for the different results in similar populations was attributed to the different samples selected in different regions and whether the study was conducted using invasive methods.²⁵

In our study, type I morphology was observed the most, then type III morphology was the second most observed morphology. Although Orhan et al. observed type II morphology the most after type I, Yigit et al. and De Almeida et al. after type I morphology, second most type III morphology was observed. The differences in these results are due to sample sizes and geographic differences.^{22,23,26}

Orhan et al. reported that women have two more canals than men, and Altunsoy et al. reported that two more canals were observed in males.^{22,27} In our study, no significant difference was found between genders in terms of morphology for central and lateral incisors ($P = 0.339$).

CONCLUSION

In our study, one canal was observed with a rate of 61.92%, and two canals with a rate of 38.08%. Considering the two canal variations, the inclusion of additional channels during root canal treatment would increase the success rate of the treatment. Three-dimensional imaging with CBCT is also more useful in morphological evaluations.

REFERENCES

1. Versiani M, Pécora J, Sousa-Neto M. The anatomy of two-rooted mandibular canines determined using micro-computed tomography. *International Endodontic Journal* 2011;44:682-687.
2. Verma GR, Bhadage C, Bhoosreddy AR, Vedpathak PR, Mehrotra GP, Nerkar AC, et al. Cone beam computed tomography study of root canal morphology of permanent mandibular incisors in Indian subpopulation. *Polish Journal of Radiology* 2017;82:371.
3. Kayaoglu G, Peker I, Gumusok M, Sarikir C, Kayadugun A, Uçok O. Root and canal symmetry in the mandibular anterior teeth of patients attending a dental clinic: CBCT study. *Brazilian Oral Research* 2015;29:1-7.
4. Sert S, Aslanalp V, Tanalp J. Investigation of the root canal configurations of mandibular permanent teeth in the Turkish population. *International Endodontic Journal* 2004;37:494-499.
5. Vertucci FJ. Root canal anatomy of the human permanent teeth. *Oral Surgery, Oral Medicine, Oral Pathology and Oral Radiology* 1984;58:589-599.
6. Plotino G, Grande NM, Pecci R, Bedini R, Pameijer CH, Somma F. Three-dimensional imaging using microcomputed tomography for studying tooth macromorphology. *The Journal of the American Dental Association* 2006;137:1555-1561.
7. Liu J, Luo J, Dou L, Yang D. CBCT study of root and canal morphology of permanent mandibular incisors in a Chinese population. *Acta Odontologica Scandinavica* 2014;72:26-30.
8. Rankine-Wilson R, Henry P. The bifurcated root canal in lower anterior teeth. *The Journal of the American Dental Association* 1965;70:1162-1165.

9. Cotton TP, Geisler TM, Holden DT, Schwartz SA, Schindler WG. Endodontic applications of cone-beam volumetric tomography. *Journal of Endodontics* 2007;33:1121-1132.
10. Koç C, Yılmaz F, Kamburoğlu K. KIBT'nin (Konik ışıklı bilgisayarlı tomografi) Endodontide kullanımı: Durum güncellemesi. *7tepe Klinik* 2019;15:248-252.
11. Ng YL, Mann V, Gulabivala K. A prospective study of the factors affecting outcomes of nonsurgical root canal treatment: part 1: periapical health. *International Endodontic Journal* 2011;44:583-609.
12. Vertucci FJ. Root canal morphology and its relationship to endodontic procedures. *Endodontic Topics* 2005;10:3-29.
13. Nascimento EHL, Gaêta-Araujo H, Andrade MFS, Freitas DQ. Prevalence of technical errors and periapical lesions in a sample of endodontically treated teeth: a CBCT analysis. *Clinical Oral Investigations* 2018;22:2495-2503.
14. Hargreaves KM, Cohen S, Berman LH. Cohen's pathways of the pulp. 10th ed. Mosby Elsevier; 2011.
15. Vertucci FJ. Root canal anatomy of the human permanent teeth. *Oral Surgery, Oral Medicine, Oral Pathology* 1984;58:589-599.
16. Gupta S, Sinha DJ, Gowhar O, Tyagi SP, Singh NN, Gupta S. Root and canal morphology of maxillary first premolar teeth in north Indian population using clearing technique: an in vitro study. *Journal of Conservative Dentistry: JCD* 2015;18:232.
17. Singh S, Pawar M. Root and canal morphology of mandibular incisors and canines in South Asian Indian population by canal staining and tooth clearing technique. *Endodontology* 2016;28:148.
18. Mao T, Neelakantan P. Three-dimensional imaging modalities in endodontics. *Imaging Science in Dentistry* 2014;44:177.
19. Neelakantan P, Subbarao C, Subbarao CV. Comparative evaluation of modified canal staining and clearing technique, cone-beam computed tomography, peripheral quantitative computed tomography, spiral computed tomography, and plain and contrast medium-enhanced digital radiography in studying root canal morphology. *Journal of Endodontics* 2010;36:1547-1551.
20. Hassan B, Payam J, Juyanda B, Van der Stelt P, Wesselink P. Influence of scan setting selections on root canal visibility with cone beam CT. *Dentomaxillofacial Radiology* 2012;41:645-648.
21. Patel S, Brown J, Pimentel T, Kelly R, Abella F, Durack C. Cone beam computed tomography in Endodontics—a review of the literature. *International Endodontic Journal* 2019;52:1138-1152.
22. Orhan K, Özemre MÖ, Seçgin CK, Gülşahi A. Alt Anterior Dişlerin Kök Kanal Morfolojisinin Konik Işıklı Bilgisayarlı Tomografi Kullanılarak Değerlendirilmesi. *Türkiye Klinikleri Dishekimliği Bilimleri Dergisi* 2018;24:190-196.
23. Helvacıoğlu Yigit D, Cora S, Sinanoğlu A, Gur C. Analysis of root canal morphology and symmetry of mandibular anterior teeth using cone beam computed tomography: a retrospective study. *Türkiye Klinikleri J Endod Special Topics* 2015;3:53.
24. Kartal N, Yanıkoğlu FÇ. Root canal morphology of mandibular incisors. *Journal of Endodontics* 1992;18:562-564.
25. Arslan H, Ertas H, Ertas ET, Kalabalık F, Saygılı G, Capar ID. Evaluating root canal configuration of mandibular incisors with cone-beam computed tomography in a Turkish population. *Journal of Dental Sciences* 2015;10:359-364.
26. De Almeida MM, Bernardineli N, Ordinola-Zapata R, Villas-Bôas MH, Amoroso-Silva PA, Brandao CG, et al. Micro-computed tomography analysis of the root canal anatomy and prevalence of oval canals in mandibular incisors. *Journal of Endodontics* 2013;39:1529-1533.
27. Altunsoy M, Ok E, Nur BG, Aglarci OS, Gungor E, Colak M. A cone-beam computed tomography study of the root canal morphology of anterior teeth in a Turkish population. *European Journal of Dentistry* 2014;8:302.

Source of Support: Nil; **Conflict of Interest:** None

Submitted: 11-03-2021; **Accepted:** 03-04-2021; **Published:** 28-04-2021