

A Comparative Evaluation of 0.5% Levobupivacaine in Combination with Dexamethasone and 0.5% Levobupivacaine alone in Ultrasound Guided Interscalene Block

Upasana Asooja¹, Sarfraj Ahmad², Malti Agrawal³

ABSTRACT

Introduction: Benefits of regional anesthesia are prolonged by addition of adjuvants. The aim of our study was to evaluate the effect of adding Dexamethasone to 0.5% levobupivacaine in ultrasound guided interscalene block. Study aimed at comparative evaluation of 0.5% levobupivacaine in combination with dexamethasone and 0.5% levobupivacaine alone in ultrasound guided interscalene block.

Material and methods: A double blinded randomized controlled study was done among 60 patients between the age group of 18-60 years of ASA grade I and II undergoing upper limb surgeries. Group A received 30 ml 0.5% levobupivacaine and 2mg (1ml) dexamethasone whereas group B received 30 ml 0.5% levobupivacaine and 2ml normal saline under ultrasound guided interscalene block.

Results: It was found that onset of sensory block was 5.37 min in group A and 6.82 min in group B. Onset of motor block was 10.14 min in group A and 12.54 min in group B. Mean duration of sensory blockade was 1075.83 min in group A and 585.96 min in group B. Mean duration of motor blockade was 915.70 min in group A and 474.6 min in group B.

Conclusion: we concluded that low dose dexamethasone when added to 0.5% levobupivacaine it shortened onset of both sensory and motor block and prolonged the duration of both sensory and motor block.

Keywords: Levobupivacaine, Dexamethasone, Interscalene Block, Ultrasound, Brachial Plexus Block

INTRODUCTION

Modern anaesthetic techniques provides rapid, smooth and complete recovery of patients. Regional anaesthesia reduces the hazards and discomforts caused due to general anaesthesia and also offers a number of advantages for day care surgical procedures. It provides prolonged intraoperative and postoperative analgesia without sedation, and also earlier recovery and discharge of the patient¹.

Brachial plexus block was first introduced by William Stewart Halsted in 1884, where he directly injected cocaine solution around nerves of brachial plexus².

Winnie first introduced interscalene block in 1970. Nowadays, interscalene block is effectively used for anaesthesia and analgesia of shoulder and upper arm surgical procedures³.

The use of Ultrasound for nerve blocks was first reported by La Grange et al. in 1978⁴. Ultrasound guidance has improved the success and decreased the complication rate in regional anaesthesia. Ultrasound guided technique also reduces the

volume of local anaesthetic to be used and incidence of toxicity. It provides good operating conditions with complete sensory and motor blockade⁵.

Levobupivacaine is a long acting, amide-type local anaesthetic that is the S (-)- enantiomer of the racemate bupivacaine. Compared to bupivacaine, levobupivacaine has a longer duration of action, lower risk of CNS and CVS toxicity⁶.

Dexamethasone is naturally occurring synthetic glucocorticoid with anti-inflammatory and immune-suppressant activity. Several adjuncts have been studied to potentiate efficacy of levobupivacaine including opioids, midazolam, neostigmine, bicarbonate, hyaluronidase and dexamethasone⁷.

There is very limited literature available regarding the use of dexamethasone as an adjuvant to levobupivacaine in ultrasound interscalene block. Hence, the study was designed to compare effects of adding dexamethasone as an adjuvant to 30 ml of 0.5% levobupivacaine and 30 ml 0.5% levobupivacaine alone in ultrasound guided interscalene block.

MATERIAL AND METHODS

After obtaining approval from institutional ethical committee, a double blinded randomised controlled study was carried out in Rohilkhand medical college and hospital, Bareilly. Informed written consent was taken from all patients prior to the procedure and patients of ASA grade I and II posted for upper limb surgery (clavicle, shoulder and upper arm) under age group 18-60 years were randomly divided into 2 groups using computer generated randomization technique. Group A received 30 ml 0.5% levobupivacaine and 2mg (1ml) dexamethasone whereas group B received 30 ml 0.5% levobupivacaine and 2ml normal saline. Patients who

¹Junior Resident, Department of Anesthesiology, ²Assistant Professor, Department of Anesthesiology, ³Professor and Head of Department, Department of Anesthesiology, Rohilkhand Medical College and Hospital, Bareilly, India

Corresponding author: Dr. Sarfraj Ahmad, Rohilkhand Medical College and Hospital, Bareilly, India

How to cite this article: Asooja U, Ahmad S, Agrawal M. A comparative evaluation of 0.5% levobupivacaine in combination with dexamethasone and 0.5% levobupivacaine alone in ultrasound guided interscalene block. International Journal of Contemporary Medical Research 2021;8(2):B1-B4.

DOI: <http://dx.doi.org/10.21276/ijcmr.2021.8.2.5>



refused to give informed consent, on anticoagulant therapy, sedatives and hypnotics, drugs or alcohol abusers, patients with decreased pulmonary reserve, with neurological deficits involving brachial plexus, known allergy to local anaesthetics and local infection at injection site were excluded from the study.

Standard preanesthetic evaluation was done one day before the day of surgery by an anaesthetist. All patients were premedicated with tablet Ranitidine 150 mg and tablet alprazolam 0.50 mg night before surgery and on the morning of surgery. In the operating room IV line was secured with 18 G cannula and monitors were attached (Non-invasive blood pressure monitoring, spO_2 , electrocardiogram). Oxygen was started at rate of 6 l/min via Hudson mask. with complete aseptic precautions patient was positioned in supine position, affected arm adducted and head turned to contralateral side and sterile field was established at the site where block has to be given. Block was performed by a trained anaesthesiologist as per protocol who was blind for group allocation. Sternocleidomastoid muscle was identified and patient was asked to take a deep breath which caused contraction of interscalene muscles and clearly visualises the interscalene groove. Linear ultrasound probe was placed in interscalene groove and three to five oval shaped hypoechoic nerve structure were visualized. (figure-1)

22 gauge spinal needle was introduced by in plane approach from lateral side of the probe and advanced under ultrasound guidance. Predetermined volume of Local anaesthetic was injected by negative aspiration around neural structures so that it spreads circumferentially around all the nerves. Deposition of local anaesthetic is seen as hypoechoic fluid expansion under ultrasound guidance. Standard monitoring was done throughout the procedure.

Sensory and motor assessment was done at every 2 min after local anesthetic was injected till achievement of complete. Onset of Sensory block assessment was done with 23 gauge hypodermic needle using a three point scale and compared to same stimulation on contralateral arm. grade 0 – normal sensation, grade 1 – loss of sensation of prick (analgesia), grade 2 – loss of sensation of touch (anesthesia). duration of sensory block was defined as time between complete sensory block and return of sensations.

Onset of Motor block assessment was done with modified bromage scale.

Grade 0 - absence of movement

Grade 1 - trembling of the muscle group

Grade 2 - ability to move against gravity but not against resistance

Grade 3 - strength reduced but able to move against resistance

Grade 4 - full strength of shoulder muscles

Duration of motor block was defined as time between complete muscle paralysis and complete recovery of motor functions.

Surgery was started after ensuring complete block has been achieved. Hemodynamic monitoring was done

perioperatively and postoperatively till 12 hours.

STATISTICAL ANALYSIS

Statistical data analysis was done using SPSS version 22.0 using independent t- test to determine mean significant difference between the two variables and $p < 0.05$ is considered statistically significant. Continuous variables were expressed as mean \pm standard deviation.

RESULTS

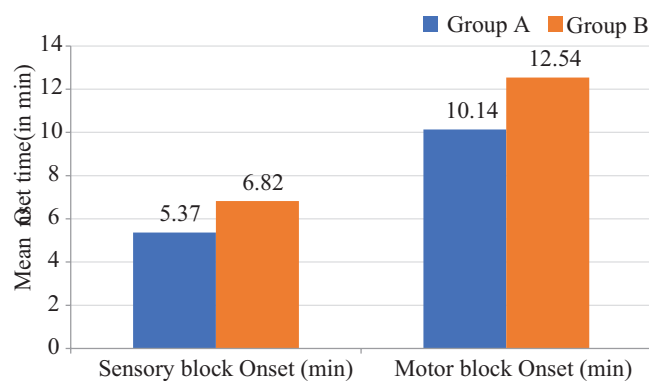
Block was successfully achieved in all the patients and all patients enrolled for the study completed the study. Demographic variables like age, gender and duration of surgery were comparable in both the groups. (table-1, graph-1)

There were 26 male and 4 females in group A and 20 males and 10 females in group B. There was no statistical difference in age group between the two groups.

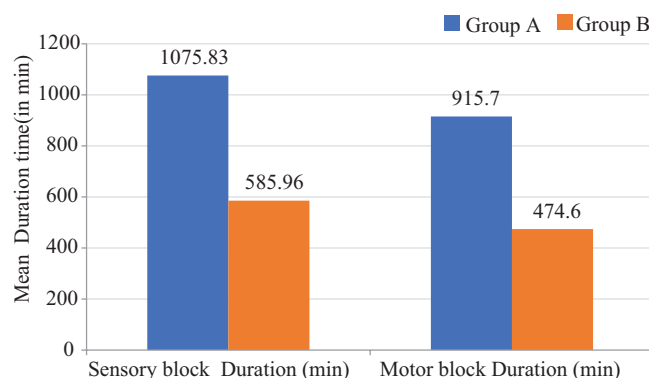
Onset of sensory block 5.37 ± 2.34 in group A which received 30 ml of 0.5% levobupivacaine plus 2mg dexamethasone compared to group B in which it was 6.82 ± 2.24 which received 0.5% levobupivacaine 30 ml plus 2ml normal saline and the result was statistically significant.

Onset of motor block in group A was 10.14 ± 2.20 whereas in group B was 12.54 ± 2.34 . the result was statistically significant.

Duration of sensory block was 1075.83 ± 196.08 in group A and 585.96 ± 6.24 in group B. The difference in duration of sensory block in two groups was statistically significant.



Graph-1: Onset of sensory block and motor block in Group A and Group B



Graph-2: Duration of sensory block and motor block in Group A and Group B

Parameters	Group A (case)	Group B (control)	p- value
Age	38.1±13.88	37.07±10.41	0.7462#
Gender (male/ female)	26/4	20/10	0.067#
Duration of surgery	75.67±13.31	79.83 ±10.04	0.177#
#statistically not significant.			

Table-1: Demographic parameters

Variables	Group A (n=30)	Group B (n=30)	p- value
Sensory block Onset (min)	5.37±2.34	6.82±2.24	0.0172*
Motor block Onset (min)	10.14±2.20	12.54±2.34	<0.001*
Sensory block Duration (min)	1075.83±196.08	585.96±6.24	<0.001*
Motor block Duration (min)	915.70±189.92	474.6±20.63	<0.001*
* Statistically significant.			

Table-2: Brachial plexus block characteristics.

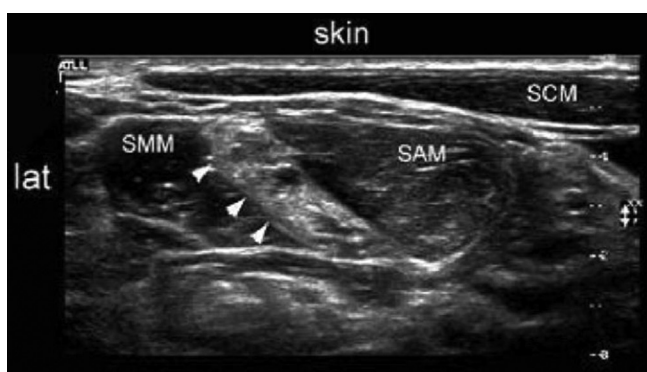

Figure-1: Transverse sonogram showing local anaesthetic spread and distension in the interscalene groove; SCM - sternocleidomastoid, SMM - scalenus Medius muscle, SAM - scalenus anterior muscle

Duration of motor block in group A was 915.7 ±189.92 and in group B was 474.6 ±20.63. The difference in duration of motor block in two groups was statistically significant. (table-2, graph-2)

DISCUSSION

Regional anaesthesia reduces the time spent in post anaesthetic care unit (PACU) and ambulatory surgical unit (ASU). Many studies have been done in past on ultrasound guided interscalene block in the world showing varying effects with different dosages of drugs used⁸. Variety of adjuvants to local anaesthetics such as clonidine, tramadol, dexmedetomidine and neostigmine have been studied in brachial plexus block in past⁹.

Steroids are added to local anaesthetic agents to prolong the duration of analgesia and improve the quality of pain relief. Glucocorticoids produces localised vasoconstriction, therefore it decreases systemic absorption of local anaesthetic agent and more amount of drug is available to act at nerve ending, thus it prolongs the duration of action. This combination has been used in both neuraxial blockade and peripheral nerve blockade¹⁰.

Present study demonstrated that addition of 2mg dexamethasone to 30 ml of 0.5% levobupivacaine prolonged the duration of both sensory and motor block in ultrasound guided interscalene block. Our findings were consistent

with Ahmed et al. who also concluded that addition of 2ml (8mg) dexamethasone to 25 ml of 0.5% levobupivacaine during ultrasound guided interscalene block prolonged the duration of motor and sensory block¹¹. Merle et al also found that addition of different doses of dexamethasone to bupivacaine also prolonged duration of motor blockade¹². Sakae et al concluded that addition of 1ml (4mg) perineural dexamethasone to 20 ml of 0.75% ropivacaine also prolonged the duration of sensory and motor block¹³. Many modalities have been investigated for post-operative pain relief due to Shoulder arthroscopic surgeries which includes single shot interscalene block (SISB), continuous interscalene block (CISB), subacromial injection of local anaesthetic and suprascapular nerve block. Woo Hee et al concluded that perineural dexamethasone significantly prolongs the analgesia produced by ropivacaine SISB and this effect is dose dependent¹⁴.

From our study we also found that onset of sensory and motor blockade was also shorter in group A which received 0.5% levobupivacaine plus 2mg dexamethasone compared to group B. Ahmed et al concluded that addition of dexamethasone to 0.5% levobupivacaine shortens the onset of sensory and motor blockade¹¹. Pani et al found that there was early onset of both sensory and motor block when 8mg of dexamethasone was added to 0.5% levobupivacaine. They concluded that both routes of drug administration extends the duration of analgesia but intravenous route should be preferred as it has less chances of neurotoxicity¹⁵.

Absence of any neurological and systemic side effects on adding 2mg dexamethasone to 0.5% levobupivacaine shows that it can be safely used in interscalene block. Therefore low dose dexamethasone can safely be added to local anaesthetics for interscalene block to have extended duration of analgesia, patient comfort, better and localised pain control, less systemic changes, minimal side effects, better recovery and early mobilisation of the patient.

CONCLUSION

Dexamethasone when used as an adjuvant to levobupivacaine has been proved capable to prolong the duration of analgesia and causes early onset of both sensory and motor blockade.

Thus regional anaesthesia helps in early recovery of patient and better postoperative management.

REFERENCES

- Hadzic A, Vloka JD. *Peripheral nerve blocks: principles and practice*. New York: McGraw-Hill; 2004 Sep 20.
- Bruce BG, Green A, Blaine TA, Wesner LV. Brachial plexus blocks for upper extremity orthopaedic surgery. *J Am Acad Orthop Surg*. 2012;20:38-47.
- Winnie AP. Interscalene brachial plexus block. *Anesthesia & Analgesia*. 1970;49:455-66.
- La Grange PD, Foster PA, Pretorius LK. Application of the Doppler ultrasound bloodflow detector in supraclavicular brachial plexus block. *British journal of anaesthesia*. 1978;50:965-7.
- Schwemmer U, Schleppers A, Markus C, Kredel M, Kirschner S, Roewer N. Operative management in axillary brachial plexus blocks: comparison of ultrasound and nerve stimulation. *Der Anaesthesist*. 2006;55:451-6.
- Morrison SG, Dominguez JJ, Frascarolo P, Reiz S. A comparison of the electrocardiographic cardiotoxic effects of racemic bupivacaine, levobupivacaine, and ropivacaine in anesthetized swine. *Anesthesia & Analgesia*. 2000;90:1308-14.
- Desmet M, Braems H, Reynvoet M, et al. IV and perineural dexamethasone are equivalent in increasing the analgesic duration of a single-shot interscalene block with ropivacaine for shoulder surgery: a prospective, randomized, placebo-controlled study. *British journal of anaesthesia*. 2013;111:445-52.
- Liu SS, Strodbeck WM, Richman JM, Wu CL. A comparison of regional versus general anesthesia for ambulatory anesthesia: a meta-analysis of randomized controlled trials. *Anesth Analg*. 2005;101:1634-42.
- Das A, RoyBasunia S, Mukherjee A, Biswas H, Biswas R, Mitra T et al. Perineural nalbuphine in ambulatory upper limb surgery: A comparison of effects of levobupivacaine with and without nalbuphine as adjuvant in supraclavicular brachial plexus block—A prospective, double-blinded, randomized controlled study. *Anesth Essays Res*. 2017;11:40-6.
- Vasconcelos MM, Pontes JP, de Menezes Rodrigues A, de Brito Neto DR, Alves RR, do Prado Silva FC, de Souza DF. Perineural dexamethasone in ultrasound-guided interscalene brachial plexus block with levobupivacaine for shoulder arthroscopic surgery in the outpatient setting: randomized controlled trial. *Brazilian Journal of Anesthesiology (English Edition)*. 2020 Oct 10.
- Abd El-Hamid AM, Alrabiey MA. Dexamethasone added to levobupivacaine prolongs ultrasound-guided interscalene brachial plexus blockade: a prospective, randomized, controlled study. *Ain-Shams Journal of Anaesthesiology*. 2016;9:422-5.
- Tandoc MN, Fan L, Kolesnikov S, Kruglov A, Nader ND. Adjuvant dexamethasone with bupivacaine prolongs the duration of interscalene block: a prospective randomized trial. *Journal of anesthesia*. 2011;25:704-9.
- Sakae TM, Marchioro P, Schuelter-Trevisol F, Trevisol DJ. Dexamethasone as a ropivacaine adjuvant for ultrasound-guided interscalene brachial plexus block: a randomized, double-blinded clinical trial. *Journal of Clinical Anesthesia*. 2017;38:133-6.
- Woo JH, Kim YJ, Kim DY, Cho S. Dose-dependency of dexamethasone on the analgesic effect of interscalene block for arthroscopic shoulder surgery using ropivacaine 0.5%: a randomised controlled trial. *European Journal of Anaesthesiology (EJA)*. 2015;32:650-5.
- Pani N, Routray SS, Mishra D, Pradhan BK, Mohapatra BP, Swain D. A clinical comparison between 0.5% levobupivacaine and 0.5% levobupivacaine with dexamethasone 8 mg combination in brachial plexus block by the supraclavicular approach. *Indian Journal of Anaesthesia*. 2017;61:302-7.

Source of Support: Nil; **Conflict of Interest:** None

Submitted: 20-12-2020; **Accepted:** 26-01-2021; **Published:** 28-02-2021