

# Expression of c-kit in Adenoid Cystic Carcinoma and Polymorphous Adenocarcinoma

Nishita Anthwal<sup>1</sup>, Sonia Gupta<sup>2</sup>, Himanshu Gupta<sup>3</sup>, Ankur Joshi<sup>4</sup>

## ABSTRACT

**Introduction:** Adenoid cystic carcinoma (ACC) and polymorphous adenocarcinoma (PAC) are salivary gland malignancies with some overlapping histomorphologic feature and immunophenotypic profiles; however their biologic behavior is significantly different. Study aimed to evaluate and compare the immunohistochemical expression of C-Kit (CD117) in differentiating adenoid cystic carcinoma and polymorphous adenocarcinoma.

**Material and methods:** A retrospective study was conducted on 20 formalin-fixed, paraffin-embedded tissue blocks, including 15 cases of Adenoid Cystic Carcinoma (5 cases for each pattern) and 5 cases of Polymorphous Adenocarcinoma histopathologically diagnosed using hematoxylin and eosin. All the sections were stained immunohistochemically using C-Kit.

**Results:** In the present study, a significant increase in C-Kit expression (both percentage of C-Kit stained cells and intensity of C-Kit) in adenoid cystic carcinoma as compared to polymorphous adenocarcinoma

**Conclusion:** Thus, the percentage of the C-kit immunoreactive cells and the staining intensities are considered to be an important factor in distinguishing adenoid cystic carcinoma from polymorphous adenocarcinoma.

**Keywords:** Staining Intensity, C-Kit, Immunohistochemistry, Salivary Gland Neoplasm

and relatively frequent occurrence in the intraoral accessory glands particularly the palate. They exhibit cribriform, tubular and solid growth pattern having hyperchromatic and angulated nuclei as well as prominent perineural invasion.<sup>5</sup> PAC arise in the minor salivary gland with a predilection for intraoral sites and exhibit wide variety of growth patterns within a single tumor including solid, glandular, tubular, trabecular, cribriform and single-file pattern. They are characterized by bland, uniform nuclei with lower recurrence rate and rarely metastasis along with prominent neurotropism.<sup>6</sup>

CD117 (C-Kit proto-oncogene) is a type III receptor tyrosine kinase operating in cell signal transduction and are normally expressed in several cell types like hematopoietic stem cells, mast cells, interstitial cells of Cajal, melanocytes, basal cells of skin, breast epithelial cells, germ cells, and cells of the central nervous system. KIT is activated (phosphorylated) by binding of its ligand, the stem cell factor. This leads to a phosphorylation cascade ultimately activating various transcription factors in different cell types. Such activation regulates apoptosis, cell differentiation, proliferation, chemotaxis and cell adhesion.<sup>7, 8</sup> Alteration in the KIT expression is seen in a variety of neoplasms such as mastocytosis, gastrointestinal stromal cell tumours, germ cell tumours, neuroblastomas, gliomas etc.<sup>9</sup> The aim of the present study was to evaluate and compare the immunohistochemical expression of C-Kit (CD117) in differentiating adenoid cystic carcinoma and polymorphous adenocarcinoma.

## INTRODUCTION

Salivary glands have the histologically heterogeneous group of tumours and greatest diversity of morphological features amongst their cells and tissue. Even though their characteristically rather pronounced variation in histological appearance, all salivary gland tumours were simplistically separated only into infiltrating and encapsulated type.<sup>1,2</sup> The morphology of salivary gland tumor reveals the cellular make up of basic ductoacinar unit of normal salivary gland.<sup>3</sup> Adenoid cystic carcinoma (ACC) and polymorphous adenocarcinoma (PAC) are salivary gland malignancies with some overlapping histomorphologic features and immunophenotypic profiles; however their biologic behavior is considerably diverse. Some histopathologic resemblance is predictable as both tumours are believed to originate from intercalated duct as well as consisted of ductal and abluminal myoepithelial differentiated cells. Both tumors have a noticeable tendency to infiltrate around nerves.<sup>4</sup> ACC is a clinically and pathologically well-defined entity which is characterized by the persistent, relentless growth with late metastasis. It occurs primarily in the major salivary glands

## MATERIAL AND METHODS

A retrospective study was conducted on 20 formalin-fixed, paraffin-embedded tissue blocks, including 15 cases of Adenoid Cystic Carcinoma (5 cases for each pattern) and 5 cases of Polymorphous Adenocarcinoma histopathologically diagnosed using hematoxylin and eosin. All the cases were

<sup>1</sup>Senior Lecturer, Department of Oral Pathology, UDMRI, Dehradun, <sup>2</sup>Tutor, Department of Oral Pathology, Govt. Dental College & Hospital, Srinagar, <sup>3</sup>Senior lecture Department of Oral Pathology, Seema Dental College, Rishikesh, <sup>4</sup>Assistant Professor, Department of Dentistry, GDMC-Dehradun, Uttarakhand, India

**Corresponding author:** Dr. Sonia Gupta, Tutor, Department of Oral Pathology, Govt. Dental College & Hospital, Srinagar

**How to cite this article:** Anthwal N, Gupta S, Gupta H, Joshi A. Expression of c-kit in adenoid cystic carcinoma and polymorphous adenocarcinoma. International Journal of Contemporary Medical Research 2020;7(11):K6-K9.

**DOI:** <http://dx.doi.org/10.21276/ijcmr.2020.7.11.7>



retrieved from archives of the Department of Oral Pathology IDST College, Modinagar and a private laboratory at Jaipur in the year 2017. All the sections were stained immunohistochemically using C-Kit. In the present study, 3 µm paraffin embedded tissue sections were cut using a semiautomatic rotary microtome (Leica). After sectioning, dewaxing, washing, and rehydration of the slides through xylene and graded alcohol concentrations as well as antigen retrieval was done with citrate buffer at pH 6.0–6.2. After this, slides were subsequently treated with 3% hydrogen peroxide so as to block endogenous peroxidase activity. Following incubation with the primary antibodies i.e. c-kit (Biocare Medical manufacturer's), the secondary conjugate antibody was applied and followed by chromogen DAB and counterstaining with Mayer's hematoxylin. In this study, breast carcinoma was taken as a positive control. All the stained slides were analysed by two observers under the microscope to eliminate any subjective bias. C-Kit expression was determined on the basis of localization, intensity and area of stained cells

**Evaluation of C-kit immunoreactivity:** C-kit immunostaining was evaluated by a semi-quantitative scoring system as:

a) Percentage of C-kit immunoreactivity; b) Intensity of staining

In each section, five high power light microscopic fields were randomly selected. Two observers individually noted the percentage of C-kit positivity in each field and the region of staining was scored as follows:

Score 0 - no staining of cells in any microscopic field

Score 1+ - less than 25% of tissue stained positive

Score 2+ - between 25% and 50% of tissue stained positive

Score 3+ - between 50% and 75% of tissue stained positive

Score 4+ - more than 75% of tissue stained positive

The intensity scores were recorded by comparing it with the positive control slides. The intensity of C-kit reaction was scored as follows:

Score 0 – No staining was evident

Score 1- Mild staining when intensity was less than the

positive control

Score 2- Moderate staining when intensity was equal to the positive control

Score 3- Intense staining when intensity was greater than the positive control

Statistical analysis

Data on immunohistochemical expression of C-kit in all the tissue sections was determined and statistically analysed with the help of Statistical package for social sciences (SPSS) software version 21.0 using percentage, Pearson Chi-square test, Pearson correlation coefficient test and Cronbach's alpha reliability test. A probability value of <0.05 was considered to be statistically significant.

**RESULTS**

In the present study, majority of the patients were females (65%) and rest were males (35%). A good interobserver reliability was found on applying Cronbach's alpha reliability test to the observations obtained from all two observers for the determination of percentage of C-kit immunoreactivity and intensity of C-kit staining (Table 1).

**Evaluation of C-kit immunostaining:** Dense brown membranous and cytoplasmic c-kit staining patterns of the tumor cells were regarded as positive for antibody. C-kit was expressed in luminal cells of the tubular and cribriform types whereas all the neoplastic cells in solid ACC exhibit C-kit immunostaining (Figure 1A, 1B & 1C). Majority of the cases of PAC revealed absence of C-kit immunostaining (Figure 1D).

**Percentage of C-kit immunoreactivity:** In cribriform and tubular pattern ACC, 40% and 60% of the cases revealed score 3+ and score 4+ respectively but in solid pattern ACC, 100% of the cases showed score 4+. In PAC, 80% and 20% of the cases revealed score 0 and score 1+ respectively. The p-value was found to be statistically significant (Table 2).

**Intensity of C-kit immunostaining:** In cribriform pattern ACC, 40% and 60% of the cases revealed score 2 and score 3 respectively whereas in tubular pattern ACC, 20%, 40%

Reliability Analysis	Cronbach's α Test	
	C-Kit percentage	C-Kit intensity
Observer 1 & Observer 2	0.982	0.968

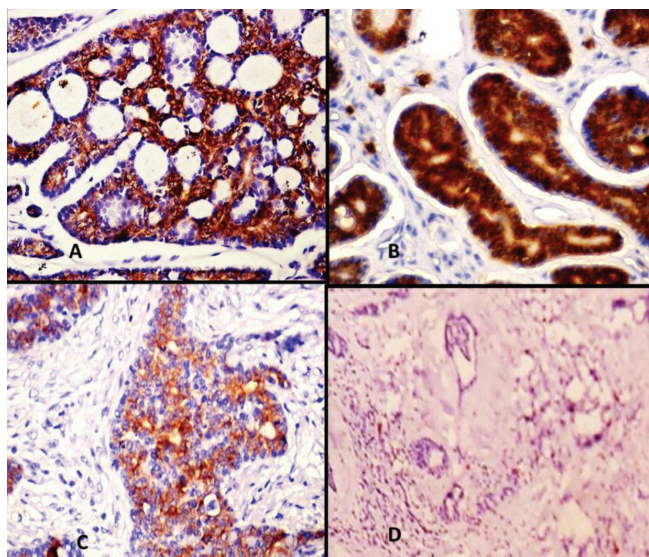
**Table-1:** Interobserver reliability analysis for C-kit immunostaining

Tumour	C-kit percentage				
	Score 0	Score 1+	Score 2+	Score 3+	Score 4+
Cribriform pattern ACC	00 (00.0%)	00 (00.0%)	00 (00.0%)	02 (40.0%)	03 (60.0%)
Tubular pattern ACC	00 (00.0%)	00 (00.0%)	00 (00.0%)	02 (40.0%)	03 (60.0%)
Solid pattern ACC	00 (00.0%)	00 (00.0%)	00 (00.0%)	00 (00.0%)	05(100.0%)
PAC	04 (80.0%)	01 (20.0%)	00 (00.0%)	00 (00.0%)	00 (00.0%)
Chi-square test	26.822				
Degree of freedom (df)	7				
p-value	0.001				

**Table -2:** C-Kit percentage in adenoid cystic carcinoma and in polymorphous adenocarcinoma

Tumour	C-kit intensity			
	Score 0	Score 1	Score 2	Score 3
Cribriform pattern ACC	00 (00.0%)	00 (00.0%)	02 (40.0%)	03 (60.0%)
Tubular pattern ACC	00 (00.0%)	01 (20.0%)	02 (40.0%)	02 (40.0%)
Solid pattern ACC	00 (00.0%)	01 (20.0%)	03 (60.0%)	01 (20.0%)
PAC	03 (60.0%)	02 (40.0%)	00 (00.0%)	00 (00.0%)
Chi-square test	28.180			
Degree of freedom (df)	5			
p-value	0.0001			
ACC-Adenoid cystic carcinoma, PAC-Polymorphous adenocarcinoma				

**Table-3:** C-kit intensity in adenoid cystic carcinoma and in polymorphous adenocarcinoma



**Figure-1:** Photomicrograph showing A) C-Kit expression in the luminal cells in cribriform pattern in adenoid cystic carcinoma, B) C-Kit expression in the luminal cells in tubular pattern in adenoid cystic carcinoma, C) C-Kit expression in all cells in solid pattern in adenoid cystic carcinoma and D) Absent C-Kit expression in polymorphous adenocarcinoma

and 40% of the cases showed score 1, score 2 and score 3 respectively. In solid pattern ACC, 20%, 60% and 20% of the cases revealed 1, score 2 and score 3 respectively but 60% and 40% of the cases of PAC showed score 0 and score 1 respectively. The p-value was found to be statistically significant (Table 3).

**DISCUSSION**

The C-kit proto-oncogene protein (a transmembrane receptor Type-III tyrosine kinase) on binding to its ligand, stem cell factor initiates a signal cascade which contributes to the growth and differentiation of multiple hematopoietic lineages. It demonstrates structural homology to the receptors of platelet-derived growth factor, macrophage colony stimulating factor.<sup>10</sup> Distinguishing PAC and ACC on H&E morphology alone can be a difficult work especially if in case of biopsies dealing with minor salivary glands. Prognostic difference of the two is sufficiently different thus distinguishing them becomes an important task of the pathologist.

Various studies have been attempted to distinguish ACC from PAC with the help of various antibodies to GFAP,

vimentin, S- 100 protein, Ki-67,  $\alpha$ -smooth muscle actin, muscle specific actin, cytokeratins, c-kit, bcl-2, cadherins and CD43. No single antibody has yet been identified that can unambiguously be used in the differentiation of ACC and PAC.<sup>4, 11</sup> The present study was done to determine and compare the immunohistochemical expression of C-Kit (CD117) in differentiating adenoid cystic carcinoma and polymorphous adenocarcinoma.

In the present study, C-kit was expressed in luminal cells of the tubular and cribriform types whereas all the neoplastic cells in solid ACC exhibit C-kit immunostaining. Majority of the cases of PAC revealed absence of C-kit immunostaining. These results were in accordance with the studies carried out by Jain A et al, Meer S et al and Penner CR et al.<sup>12-14</sup> This indicates that myoepithelial cells donot express C-kit expression in tubular and cribriform pattern, as the abluminal cells donot stain whereas, solid pattern reveal expression in all cells, most of which are considered as modified myoepithelial cells. This difference in the pattern of C-kit expression in both tubular and cribriform pattern ACC as compared with solid pattern suggest that a loss of cellular heterogeneity in solid variants, with differentiation primarily along the lines of the luminal cell layer and may correlate with the worse clinical course of the solid variant of ACC.<sup>2</sup> In the current study, C-kit percentage was greater in solid pattern ACC followed by cribriform and tubular pattern ACC with a statistically significant p-value. Only 20% of the cases of polymorphous adenocarcinoma revealed percentage of c-kit reactivity. The intensity of c-kit was significantly greater in cribriform pattern ACC followed by tubular and solid pattern ACC. Only 40% of the cases of polymorphous adenocarcinoma showed mild C-kit intensity. These results were in accordance the studies carried out by Andreadis D et al, Meer S et al, Beltran D et al and Epivatianos A et al.<sup>8, 13, 15-16</sup> This signifies that strong expression of C-kit immunoreactivity in adenoid cystic carcinoma as compared to polymorphous adenocarcinoma.

**CONCLUSION**

The distinction between ACC and PAC is important since the clinical course and prognostic significance differ. It is imperative that immunohistochemical stains can be used as an adjuvant in histological-based diagnosis so that simple, accurate, reliable, and reproducible results can be assessed. C-kit can aid in the differential diagnosis of lesion presenting



a morphological confusion between ACC and PAC. However, the percentage of the C-Kit immunoreactivity and the staining intensity are considered to be an important factor in distinguishing ACC and PAC.

## REFERENCES

1. Foote FWJ and Frazell EL. Tumors of the major salivary glands. Atlas of Tumor Pathology, first series, Fascicle 11. Washington, DC: Armed Forces Institute of Pathology 1954.
2. Ellis GL and Auclair PL. Tumors of the salivary glands. Atlas of Tumor Pathology, third series, Fascicle 11. Washington, DC: Armed Forces Institute of Pathology.1996.
3. Dardick I. Current status of histogenetic and morphogenetic concepts of salivary gland tumorigenesis. *Cri Rev Oral Biol Med* 1993; 4:639-677.
4. Edwards PC, Bhuiya T, and Kelsch RD. C-kit expression in the salivary gland neoplasms adenoid cystic carcinoma, polymorphous low-grade adenocarcinoma, and monomorphic adenoma. *Oral Surg Oral Med Oral Pathol Oral Radiol Endod* 2003; 95: 586–593.
5. Premkumar J, Karthik S, Sathyakumar M and Martin Y. Concurrent occurrence of adenoid cystic carcinoma of the salivary glands with small cell carcinoma of the liver: A rare case report. *J Oral Maxillofac Pathol* 2013; 17:288–291.
6. Crean SJ, Bryant C, Bennett J, Harris M. Four cases of polymorphous low-grade adenocarcinoma. *Int J Oral Maxillofac Surg* 1996; 25:40–44.
7. Jeng YM, Lin CY, and Hsu HC. Expression of the c-kit protein is associated with certain subtypes of salivary gland carcinoma. *Can Lett* 2000; 154:107–111.
8. Andreadis D, Epivatianos A, Pouloupoulos A et al. Detection of c-KIT (CD117) molecule in benign and malignant salivary gland tumours. *Oral Oncol* 2006; 42: 57-65.
9. Lammie A, Drobnjak M, Gerald W, Saad A, Cote R and Cordon-Cardo C. Expression of C-Kit and Kit ligand proteins in normal human tissue. *J Histochem Cytochem* 1994; 42: 1417-1425.
10. Vandenbark GR, de Castro CM, Taylor H, Dew-Knight S, Kaufman RE. Cloning and structure analysis of the human c-kit gene. *Oncogene* 1992; 7:1259-1266.
11. Woo VL, Bhuiya T, and Kelsch R. Assessment of CD43 expression in adenoid cystic carcinomas, polymorphous low grade adenocarcinomas, and monomorphic adenomas. *Oral Surg Oral Med Oral Pathol Oral Radiol Endod* 2006; 102: 495–500.
12. Jain A, Shetty DC, Rathore AS and Kumar K. Characterization and localization of C-kit and epidermal growth factor receptor in different pattern of adenoid cystic carcinoma. *J Can Res Ther* 2016; 12:834-839.
13. Meer S, Singh S and Altini M. C-kit and bcl-2 are not useful markers in differentiating adenoid cystic carcinoma from polymorphous low-grade adenocarcinoma. *Int Sch Res Network* 2011; 2011: 1-6.
14. Penner CR, Folpe AL and Budnick SD. C-kit expression distinguishes salivary gland adenoid cystic carcinoma from polymorphous low-grade adenocarcinoma. *Mod Pathol* 2002; 15:687-691.
15. Beltran D, Faquin WC, Gallagher G and August M. Selective immunohistochemical comparison of polymorphous low-grade adenocarcinoma and adenoid cystic carcinoma. *J Oral Maxillofac Surg* 2006; 64: 415-423.
16. Epivatianos A, Pouloupoulos A, Dimitrakopoulos I, Andreadis D, Nomikos A, Vlahou S, et al. Application of alpha-smooth muscle actin and c-kit in the differential diagnosis of adenoid cystic carcinoma from polymorphous low-grade adenocarcinoma. *Oral Oncol* 2007;43:67-76

**Source of Support:** Nil; **Conflict of Interest:** None

**Submitted:** 01-09-2020; **Accepted:** 23-10-2020; **Published:** 20-11-2020