

# Outcome of Arthroscopic Bone Marrow Stimulation in Osteochondritis Dissecans of the Talus in a Tertiary Care Hospital

Atanu Mohanty<sup>1</sup>, Chandra Sekhar Pradhan<sup>2</sup>, Jitendra Sarangi<sup>3</sup>, Anuraag Mohanty<sup>4</sup>

## ABSTRACT

**Introduction:** Osteochondritis dissecans of the talus is a rare condition that can create challenges for both the patient and the treating surgeon. Arthroscopic bone marrow stimulation (i.e. microfracture, drilling) is a well-accepted and proven technique to allow fibrocartilage differentiation and thereby provide infill at the site of a cartilage defect in several joints, including the ankle. The aim of our study was to examine the role of arthroscopic bone marrow stimulation techniques as a means of treatment for osteochondral lesions of the talus.

**Material and methods:** Thirty two ankles were identified between January 2012 and January 2020 with talus OCD that underwent arthroscopic bone marrow stimulation. Each lesion was classified according to the Berndt and Harty classification. Study patients were evaluated at 6 weeks, 3 months, 6 months, 12 months, and annually after surgery. Assessments via a visual analogue scale (VAS) for pain during daily activities and sport activity and the American Orthopaedic Foot & Ankle Society (AOFAS) scoring system were obtained at each visit.

**Result:** There were 25 men and 4 women of average age 35 years (range 17–50) and mean body mass index (BMI) 22 kg/m<sup>2</sup> (range 20–34) at the time of surgery. Quantitative MRI measurements on 3D FSPGR Sequence showed that mean area of the lesions were 0.801 ± 0.505 cm<sup>2</sup>. Mean AOFAS scores improved from 66 points (range 53–77) preoperatively to 90 points (range 83–100) at final follow-up (p<0.05) and mean Visual Analogue Scale (VAS) scores from 6 points (range 5–8) to 2 points (range 0–5) with p value <0.05 which is statistically significant.

**Conclusion:** Arthroscopic management of osteochondral lesions of the talus has the advantages of better cosmetic results, less pain, and less surgical trauma. This technique is technically demanding and should be reserved for the experienced foot and ankle arthroscopist.

**Keywords:** Ankle arthroscopy, Microfracture, Osteochondritis Dissecans, Talus

an incidence of 0.09% and a prevalence of 0.002/100,000 person/year.<sup>2,3</sup> The etiology of osteochondritis dissecans was once controversial, but most investigators now consider trauma to be the main causative factor in osteochondral lesions of the lateral talar dome. In contrast, 80% of medial fractures are not accompanied by a clear history of trauma. MRI is invaluable in correctly staging osteochondritis dissecans and is particularly useful in distinguishing between stable and unstable lesions. Although, over the years, various classifications have been proposed using CT, MRI or arthroscopy, Berndt and Harty's classification is still the most widely used. For these lesions, diverse treatment options have been published in the last decades, however the goals of the current article are to summarise the outcome of arthroscopic bone marrow stimulation different for treating Osteochondritis dissecans of the talus.

## MATERIAL AND METHODS

Thirty two ankles were identified between January 2012 and January 2020 with talus OCD that underwent arthroscopic bone marrow stimulation. Isolated osteochondral lesions of the talus without combined lesions, in patients of less than 50 years old with lesions of <15mm were included in our study. Patients with osteoarthritis, impingement or kissing lesions of the ankle, and patients with rheumatoid arthritis were excluded from the study. Demographic data, mechanism of injury, conservative treatment history, surgical details of initial treatment and subsequent treatment, if necessary was collected. Pre-operatively, radiographs and MRI were evaluated for location of the lesion, border, and size of the lesion. Each lesion was classified according to the Berndt and Harty classification (table-1). Study patients were evaluated at 6 weeks, 3 months, 6 months, 12 months, and annually after surgery. Assessments via a visual analogue scale (VAS)

## INTRODUCTION

Osteochondritis dissecans (OCD) is an acquired idiopathic lesion of subchondral bone that can produce delamination and sequestration with or without articular cartilage involvement and instability. In 1888 Konig was the first author to use the term osteochondritis dissecans to describe loose bodies found in the knee joint; he believed them to be fragments from an avascular bone lesion.<sup>1</sup> The ankle is the third most frequently affected anatomical site, after the knee and the elbow joints. In the ankle, the anterolateral and posteromedial aspects of the talar dome are the most frequently involved areas. According to the literature, OCD of the talus has

<sup>1</sup>Associate Professor, Orthopaedics, SCB Medical College, Cuttack,

<sup>2</sup>Assistant Professor, Orthopaedics, SCB Medical College, Cuttack,

<sup>3</sup>Lecturer/GDMO, Department of PMRD SVNIRTAR, Olatpur, Cuttack, <sup>4</sup>8th Sem MBBS Student, IMS and SUM Hospital, Bhubaneswar, India

**Corresponding author:** Dr Chandra Sekhar Pradhan, Assistant Professor, Orthopaedics, SCB Medical College, Cuttack, Cuttack, India

**How to cite this article:** Atanu Mohanty, Chandra Sekhar Pradhan, Jitendra Sarangi, Anuraag Mohanty. Outcome of arthroscopic bone marrow stimulation in osteochondritis dissecans of the talus in a tertiary care hospital. International Journal of Contemporary Medical Research 2020;7(6):F12-F16.

**DOI:** <http://dx.doi.org/10.21276/ijcmr.2020.7.6.12>



for pain during daily activities and sport activity and the American Orthopaedic Foot & Ankle Society (AOFAS) scoring system were obtained at each visit (Figure-1). Radiographs at each follow-up visit were evaluated by a Healing matrix that assessed serial changes in lesion length, lesion depth, perilesional sclerosis or density of the lesion. At final follow-up, lesion size, border, Berndt and Harty classification, and signs of osteoarthritis were recorded. The data were evaluated using IBM SPSS. The paired Student's t-test was used for assessing changes between preoperative and postoperative scores and p value < 0.05 was accepted as statistically significant.

**Technique:** The principal objective of arthroscopic bone marrow stimulation is to create multiple openings in the subchondral bone whereby pluripotent mesenchymal stem cells aggregate to the defect site and, in response to growth factors, stimulate the differentiation of fibrocartilaginous tissue.<sup>4</sup> The patient is positioned supine on the operative table with a blanket roll under the ipsilateral right hip. A thigh tourniquet is placed on the operative right leg. Under traction, an anteromedial portal to the ankle is established medial to the tibialis anterior tendon, approximately 1 cm proximal to the tip of the medial malleolus. A 2.7 mm 30 degree arthroscope is used. An anterolateral portal is established under arthroscopic visualization with use of an 18-gauge needle. This portal is lateral to peroneus tertius and about 1.5 cm proximal to the tip of the lateral malleolus. However the location of the osteochondral lesion should be accurately determined by preoperative imaging to choose the appropriate arthroscopic approach. Routine diagnostic ankle arthroscopy is performed and a 3.5-mm shaver is used to debride the extensive synovitis to allow for full visualization of the ankle joint. An arthroscopic probe is used to identify the borders of the lesion (Fig 2). The cartilage over the lesion which is friable and nonviable is debrided with the use of a curette. The underlying subchondral bone also is debrided using both portals with both a curette and an arthroscopic burr until bleeding bone is encountered. Microfracture of the base of the osteochondritis dissecans (OCD) is performed using an arthroscopic awl or a k wire at 3- to 4-mm intervals to promote vascularization.<sup>5,6,7</sup>

**Rehabilitation:** Postoperatively, the patient is placed into a well-padded below knee splint for 3 weeks. At the 3-week visit, the patient is allowed for ankle range of motion exercises. The patient is kept non-weightbearing for 10 to 12 weeks.

**RESULT**

Twenty nine patients (32 ankles) with isolated osteochondral lesions of the talus belonging to stage II and stage III were treated by arthroscopic micro fracture. There were 25 men and 4 women of average age 35 years (range 17–50) and mean body mass index (BMI) 22 kg/m<sup>2</sup> (range 20–34) at the time of surgery. The lesions were located medially in 29 cases (95%) and laterally in 3 cases. Quantitative MRI measurements on 3D FSPGR Sequence showed that mean area of the lesions were 0.801 ± 0.505 cm<sup>2</sup> (Table-2). The

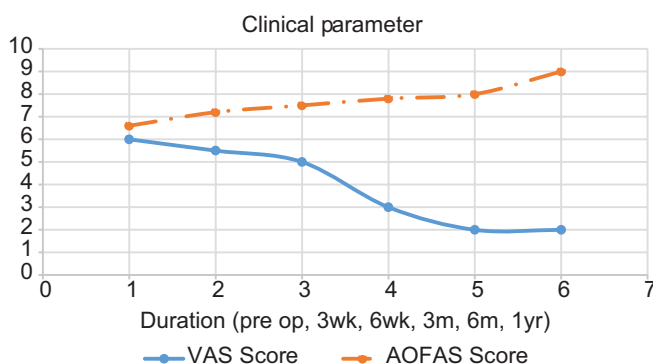
Stage	Definition
I	Compression fracture with intact overlying cartilage
II	Incomplete avulsion of an osteochondral fragment
III	Complete avulsion of an osteochondral fragment without displacement
IV	Avulsed fragment displaced into joint

Berndt AL, Harty M. Transchondral fractures (osteochondritis dissecans) of the talus. J Bone Joint Surg Am. 1959;41-A:988-1020.

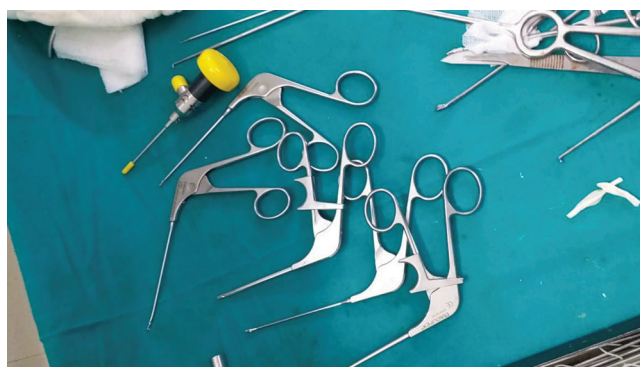**Table-1:** Radiographic classification of transchondral fractures of the talus

Stage	Mean age	Mean BMI (KG/M <sup>2</sup> )	Mean dimension (CM <sup>2</sup> )
II	32	20.4	0.735
III	38	23.6	0.874

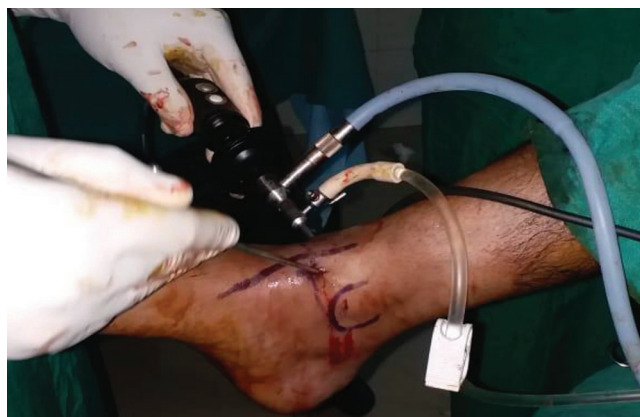**Table-2:** Distribution of osteochondral lesion of talus



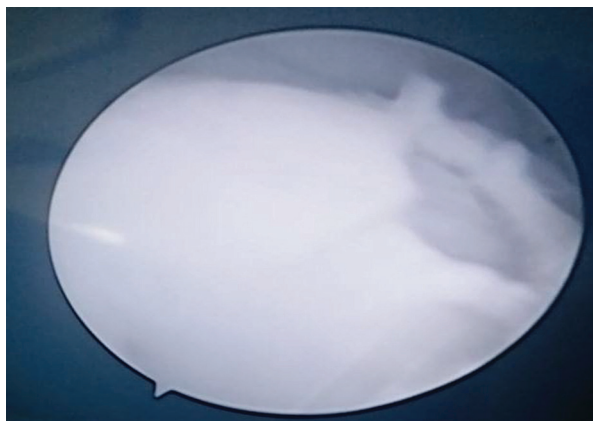**Figure-1:** Change of clinical parameters during follow-up



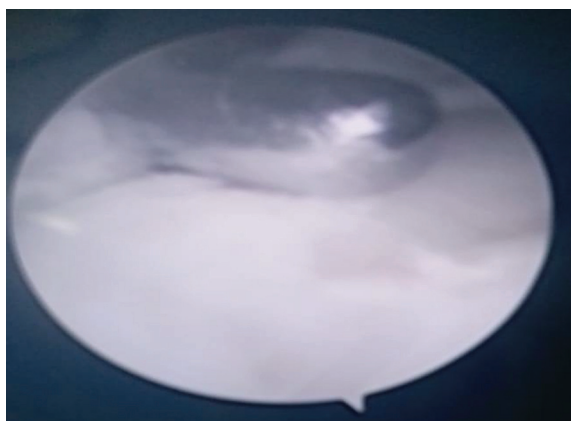
**Figure-2(a):** Instruments required




**Figure-2(b):** patient positioning and portal placement



**Figure-2(c):** Arthroscopic view of OCD of Talus



**Figure-2(d):** Debridement through shaver



**Figure-2(e):** Creation of microfracture through arthroscopic awl

measurements also correlated with intra operative lesion size which showed no significant statistical difference. Clinical outcome evaluations were performed at a mean follow-up of 15 months. Mean AOFAS scores improved from 66 points (range 53–77) preoperatively to 90 points (range 83–100) at final follow-up ( $p < 0.05$ ) and mean Visual Analogue Scale (VAS) scores from 6 points (range 5–8) to 2 points (range 0–5) with  $p$  value  $< 0.05$  which is statistically significant. There were no postoperative complications related with the surgery including nerve injury, infection, and delayed wound healing. In terms of prognostic factors, a longer symptom duration, elderly individuals and high BMI patients were found to negatively affect outcome, as determined by AOFAS scores, VAS scores ( $p < 0.05$ ).

## DISCUSSION

Based on the current literature, arthroscopic microfracture is defined as first line of treatment option for talus OCD especially for the lesions smaller than  $1.5 \text{ cm}^2$  or  $15 \text{ mm}$ .<sup>8,9</sup> With microfracture, vascularized subchondral bone is penetrated. This results with the formation of a blood clot that contains growth factors and progenitor cells that stimulate healing. With time, blood clot shows metaplastic changes and promote formation of fibrous cartilage repair tissue. Although formed fibrous cartilage has less resistance to compression and shear forces than the normal articular cartilage tissue; it is shown that approximately 78% to 86% of patients achieve good to excellent results after arthroscopic microfracture.<sup>10,11,12</sup>

There have been multiple studies addressing different patient factors and lesion characteristics that may yield a poorer outcome. Lesions smaller than  $15 \text{ mm}$ , contained lesions, and anterolateral lesions are considered to be the positive prognostic indicators; negative indicators include older age ( $> 33$ - $40$  years old), lesions deeper than  $7 \text{ mm}$ , lesions larger than  $15 \text{ mm}$ , cystic lesions, medial talar lesions, higher BMI, history of trauma, longer duration of symptom, and presence of osteophytes.<sup>13,14,15</sup> Our study also yielded similar results in terms of VAS Score and AOFAS Score.

Zengerink et al.<sup>16</sup> performed a review of the literature on the surgical treatment of OCD lesions. Fragment removal led to a clinical success rate of 54%; the addition of debridement of the crater increased the success rate to 88%. The association of removal, debridement and marrow stimulation techniques led to the best result, with a success rate of 85% in stage III or IV lesions smaller than  $1.5 \text{ cm}$ .

Chuckpaiwong et al.<sup>17</sup> reviewing 105 OCD lesions treated with microfractures, reported no failures in the case of lesions smaller than  $15 \text{ mm}$  (73 patients), but obtained only one good result in lesions greater than  $15 \text{ mm}$  (32 cases). An older age, a high body mass index, a traumatic etiology and the presence of osteophytes are all factors that negatively affect the result.

In a current concepts review, Giannini and Vannini<sup>18</sup> suggested that marrow stimulation can even be attempted in lesions up to sizes of  $2.0 \text{ cm}^2$ . One recent study by Choi et al.<sup>19</sup> reported successful results at a mean 44.5 months following surgery in 89.5% of patients with lesion sizes less than  $150 \text{ mm}^2$  and increased success (94.8%) with lesion sizes less than  $100 \text{ mm}^2$ . The depth of the lesion was found to only weakly correlate with the overall clinical outcome.

The short- and medium-term results of arthroscopic bone marrow stimulation techniques in treating osteochondral lesions of the talus are primarily good. Saxena and Eakin<sup>20</sup> studied the results of microfracture in high-demand athletes at a mean follow-up of 32 months and showed significant improvement in AOFAS scores of 54.6 preoperatively to 94.4 following surgery (96% good to excellent). Lee et al.<sup>21</sup> reported 89% good and excellent outcomes following microfracture at a mean follow-up of 33 months and a postoperative American Orthopaedic Foot and Ankle Society

(AOFAS) score of 90 (range, 73-100). Gobbi et al.<sup>22</sup> also showed good results with microfracture at a mean follow-up of 53 months. In the previously mentioned article by Takao et al.<sup>23</sup> significant 2-year improvements in AOFAS scores were shown in addition to 93.1% improvement of repair infill at 1 year via second-look arthroscopy. Becher and Thermann<sup>24</sup> prospectively evaluated 30 patients for 2 years following microfracture surgery and reported 83% of patients to have a good or excellent outcome. Schuman et al.<sup>25</sup> found 82% good to excellent results following drilling at an average 4.8-year follow-up, while Van Buecken et al.<sup>26</sup> reported good to excellent results in 87% of patients at an average 26-month follow-up.

There has been a distinct paucity of literature reporting long-term results following bone marrow stimulation techniques about the talus. Hunt and Sherman<sup>27</sup> found that 54% of their cohort had fair or poor results at a mean of 66 months following arthroscopic drilling, with pain noted in 52% of patients at follow-up examination. Kumai et al.<sup>28</sup> also reported only 72% good results at a mean 4.6-year follow-up. While Schuman, Struijs and van Dijk<sup>25</sup> reported good functional scores following surgery, only 55% had resumed sporting activities and the remaining 45% were either limited or had not resumed activity at all. In addition, Ferkel et al.<sup>29</sup> reported only 64% to 72% good to excellent results at a mean follow-up time of 71 months, with 35% deterioration of outcome scores in patients who had been seen 5 years prior. Preoperative to postoperative comparison of plain radiographs showed that 34% decreased by at least one grade of arthritis at follow-up. The authors also noted the possibility of persistent pain in patients with unstable defects at the time of arthroscopy. Similarly, Robinson et al.<sup>30</sup> reported 47.7% fair or poor results at a mean 3.5-year follow-up time period.

In our study with a follow up period of 15 months (mean) the results of bone marrow stimulation is quite good in terms of VAS score and AOFAS score and comparable to other literatures, but the long term result needs further evaluation. In our series only two patients are followed up for more than 36 months without having any significant deterioration of pain and functional aspects. Both of them are non-athletes and belonging to age group <25 years. So it will be premature to compare our results with other studies on long term follow up.

The present study has some limitations. First, we retrospectively evaluated prospectively followed patients. Secondly, we did not have postoperative MRI evaluation, second look arthroscopy or biopsy. Thirdly, we operated on highly selective patient group within a specific range with the same technique, thus it is quite difficult to obtain a larger patient group. More over the follow up duration is not quite long to comment upon long term result.

## CONCLUSION

Arthroscopic management of osteochondral lesions of the talus has the advantages of better cosmetic results, less pain, and less surgical trauma. This technique is technically

demanding and should be reserved for the experienced foot and ankle arthroscopist. Use of 3D FSPGR sequence in MRI makes quantitative assessment of cartilage thickness more accurately to advocate microfracture pre operatively and that's why the results in our study is quite promising. Nevertheless, the results of research in this area are sporadic and despite a number of promising future directions for the treatment of OCD, more scientific evidence is needed to obtain a treatment that demonstrates adequate safety and efficacy.

## REFERENCES:

1. Konig A. Uber freie Körper in den Gelenken. Dtsch Z Chir. 1888;27:90-103.
2. Bauer M, Jonsson K, Lindén B. Osteochondritis dissecans of the ankle. A 20-year follow-up study. J Bone Joint Surg Br. 1987;69:93-96.
3. Flick AB, Gould N. Osteochondritis dissecans of the talus (transchondral fractures of the talus): review of the literature and new surgical approach for medial dome lesions. Foot Ankle. 1985;5:165-185.
4. Alford JW, Cole BJ. Cartilage restoration, part 1: basic science, historical perspective, patient evaluation, and treatment options. Am J Sports Med 2005; 33: 295-306.
5. van Bergen CJ, de Leeuw PA, van Dijk CN. Potential pitfall in the microfracturing technique during the arthroscopic treatment of an osteochondral lesion. Knee Surg Sports Traumatol Arthrosc. 2009;17:184-7.
6. Chen H, Sun J, Hoemann CD, Lascau-Coman V, Ouyang W, McKee MD, et al. Drilling and microfracture lead to different bone structure and necrosis during bone-marrow stimulation for cartilage repair. J Orthop Res. 2009; 27:1432-8.
7. Mithoefer K, McAdams T, Williams RJ, Kreuz PC, Mandelbaum BR. Clinical efficacy of the microfracture technique for articular cartilage repair in the knee: an evidence-based systematic analysis. Am J Sports Med. 2009;37:2053-63.
8. Hannon CP, Smyth NA, Murawski CD, Savage-Elliott I, Deyer TW, Calder JD, et al. Osteochondral lesions of the talus: aspects of current management 2014.
9. Murawski CD, Kennedy JG. Operative treatment of osteochondral lesions of the talus. J Bone Joint Surg Am 2013; 95: 1045-54.
10. Zwingmann J, Südkamp NP, Schmal H, Niemeier P. Surgical treatment of osteochondritis dissecans of the talus: a systematic review. Arch Orthop Trauma Surg 2012; 132: 1241-50.
11. Van Bergen CJ, Kox LS, Maas M, Siersevelt IN, Kerkhoffs GM, van Dijk CN. Arthroscopic treatment of osteochondral defects of the talus: outcomes at eight to twenty years of follow-up. J Bone Joint Surg Am 2013; 95: 519-25.
12. Badekas T, Takvorian M, Souras N. Treatment principles for osteochondral lesions in foot and ankle. Int Orthop 2013; 37: 1697-706.
13. McCullough CJ, Venugopal V. Osteochondritis dissecans of the talus: the natural history. Clin Orthop Relat Res 1979; 144: 264-8.
14. Cuttica DJ, Smith WB, Hyer CF, Philbin TM, Berlet GC. Osteochondral lesions of the talus: predictors of

- clinical outcome. *Foot Ankle Int* 2011; 32: 1045-51.
15. Lee KB, Bai LB, Yoon TR, Jung ST, Seon JK. Second-look arthroscopic findings and clinical outcomes after microfracture for osteochondral lesions of the talus. *Am J Sports Med.* 2009;37 Suppl 1:63S-70S.
  16. Zengerink M, Struijs PA, Tol JL, van Dijk CN. Treatment of osteochondral lesions of the talus: a systematic review. *Knee Surg Sports Traumatol Arthrosc.* 2009 Oct 27 [Epub ahead of print].
  17. Chuckpaiwong B, Berkson EM, Theodore GH. Microfracture for osteochondral lesions of the ankle: outcome analysis and outcome predictors of 105 cases. *Arthroscopy* 2008; 24: 106-12.
  18. Giannini S, Vannini F. Operative treatment of osteochondral lesions of the talar dome: current concepts review. *Foot Ankle Int.* 2004;25:168-75.
  19. Choi WJ, Park KK, Kim BS, Lee JW. Osteochondral lesion of the talus: is there a critical defect size for poor outcome? *Am J Sports Med.* 2009;37:1974-80.
  20. Saxena A, Eakin C. Articular talar injuries in athletes: results of microfracture and autogenous bone graft. *Am J Sports Med.* 2007;35:1680-7.
  21. Lee KB, Bai LB, Chung JY, Seon JK. Arthroscopic microfracture for osteochondral lesions of the talus. *Knee Surg Sports Traumatol Arthrosc.* 2009 Sep 25 [Epub ahead of print].
  22. Gobbi A, Francisco RA, Lubowitz JH, Allegra F, Canata G. Osteochondral lesions of the talus: randomized controlled trial comparing chondroplasty, microfracture, and osteochondral autograft transplantation. *Arthroscopy.* 2006;22:1085-92.
  23. Takao M, Uchio Y, Kakimaru H, Kumahashi N, Ochi M. Arthroscopic drilling with debridement of remaining cartilage for osteochondral lesions of the talar dome in unstable ankles. *Am J Sports Med.* 2004;32:332-6.
  24. Becher C, Thermann H. Results of microfracture in the treatment of articular cartilage defects of the talus. *Foot Ankle Int.* 2005;26:583-9.
  25. Schuman L, Struijs PA, van Dijk CN. Arthroscopic treatment for osteochondral defects of the talus: results at follow-up at 2 to 11 years. *J Bone Joint Surg Br.* 2002;84:364-8.
  26. Van Buecken K, Barrack RL, Alexander AH, Ertl JP. Arthroscopic treatment of transchondral talar dome fractures. *Am J Sports Med.* 1989;17:350-5, discussion 355-6.
  27. Hunt SA, Sherman O. Arthroscopic treatment of osteochondral lesions of the talus with correlation of outcome scoring systems. *Arthroscopy.* 2003;19:360-7.
  28. Kumai T, Takakura Y, Higashiyama I, Tamai S. Arthroscopic drilling for the treatment of osteochondral lesions of the talus. *J Bone Joint Surg Am* 1999; 81: 1229-35.
  29. Ferkel RD, Zanotti RM, Komenda GA, Sgaglione NA, Cheng MS, Applegate GR, Dopirak RM. Arthroscopic treatment of chronic osteochondral lesions of the talus: long-term results. *Am J Sports Med.* 2008;36:1750-62.
  30. Robinson DE, Winson IG, Harries WJ. Arthroscopic treatment of osteochondral lesions of the talus. *J Bone Joint Surg Br.* 2003;85:989-993.

**Source of Support:** Nil; **Conflict of Interest:** None

**Submitted:** 02-05-2020; **Accepted:** 30-05-2020; **Published:** 21-06-2020