

Diagnosis of Spinal Tuberculosis -A Computed Tomography Study

Sayar Ahmad Taley¹, Kifayat Hussain Ganaie², Mohammad Saleem Dar³

ABSTRACT

Introduction: Tuberculosis is an infectious disease, mainly caused by Mycobacterium tuberculosis and its incidence have increased across the globe. Objective: This was a hospital based retrospective study and was used to determine the role of CT in establishing the definitive diagnosis of spinal TB.

Material and Methods: The patient data was retrieved from the digital database of the hospital. Out of 120 patients, 14 patients were included in this study. Patients age, sex, symptoms and signs were noted down. CT scan with axial, coronal and sagittal sections were studied. Axial, coronal and sagittal sections of CT were reviewed by an expert radiologist.

Results: Fourteen (11.4%) adults with spinal tuberculosis were found among 120 patients during this study period. The mean age (\pm SD) in our cases was 46.5 (\pm 22.0) years. Out of 14, 8 were males and 6 were females, with male: female ratio of 1.4. The mean duration was 1.25 years. The most common feature was rachialgia which was seen in 93% of cases, followed by segmental spinal stiffness (50%). The diagnosis in these cases was based on history, physical examination, vertebral radiographs, CT scan and response the medications. On vertebral imaging, lumbar lesions (57%) were seen in most of the cases, followed by dorsal (36%) and cervical (7%) involvement. The prognosis was good in all these cases except in two patients with medullary compression.

Conclusion: In the recent years, the incidence of spinal TB has increased in both the developed and developing nations and is difficult to diagnose as histopathology is not done straight away in such cases. The presence of back pain associated with major radiological signs of spondylosis on CT can be used to diagnose this condition

Keywords: Spinal, TB, CT, Pott's

INTRODUCTION

Tuberculosis is a Global Health Problem and the main causative organism is Mycobacterium Tuberculosis. Spinal tuberculosis (also called Potts's Spine), is one of the oldest diseases known to mankind. Sir Percival Pott in his monograph in 1779 was the first person to mention about the spine tuberculosis. Most of the cases which he diagnosed were children and young adults. Tuberculous infection of spine is called Pott's Spine and the paraplegia resulting from this, is called Pott's Paraplegia.¹ Around 1-2% of all the TB belong to Spinal TB.²⁻⁴ Spinal TB is the most common skeletal TB, followed by hip. The true incidence and prevalence of Pott's Spine in the world is not known. Pott's spine is a serious complication as it could result in permanent neurological damage.⁷ Computed tomography (CT) scan can be used to diagnose and assess the severity of injury and can also be used to monitor the treatment response.⁸ The exact incidence and prevalence of spinal TB

is still unknown. So the primary aim of this study was to determine the prevalence, radiological features and spjnal CT in establishing a diagnosis of Potts spine.

MATERIAL AND METHODS

This is a retrospective analysis of 120 TB patients admitted in the Department of Internal Medicine, SKIMS over a period of 2 years. The clinical and demographic details were recorded along with information about their clinical features, imaging and treatment provided.

The spinal TB diagnosis was determined on the basis of clinical features, radiological findings and treatment responses (antituberculosis treatment). The cases were not diagnosed on the basis of bacterial culture and histopathology. Vertebral CT scan were performed in all patients with suspected spinal TB. The antituberculosis medications were administered in all the cases by combing the following 4 medications (Standard treatment for Tuberculosis): rifampicin (10 mg/kg/day), isoniazid (5 mg/kg/day), ethambutol (20 mg/kg/day), and pyrazinamide (30 mg/kg/day), for 2 months, followed rifampicin and isoniazid (dual therapy) at the same doses for 10 months. Treatment was started in all those patients who had a radiological confirmation of Pott's Spine. The response to the treatment was based on as the recovery of the body weight, disappearance of pain and fever, and evidence of radiological improvement. Each patient was seen subsequently for at least 2 times after completion of the full anti-TB treatment course.

RESULTS

During the 2-year study period, 14 (11.6%) cases of spinal tuberculosis (Fig. 1 and 2) were diagnosed among 120 patients with all forms of TB. The mean (\pm standard deviation [SD]) age of 14 patients was 46.5 \pm 21.0 years old. The sex ratio (M/F) was 1.4 (Fig. 3). 8 out of 14 patients (57%) came from suburban areas, and 6 out of 14 patients (43%) were jobless.

Pulmonary or extrapulmonary TB excluding Spinal TB was diagnosed in 36% of cases (5 patient s) in our hospital.

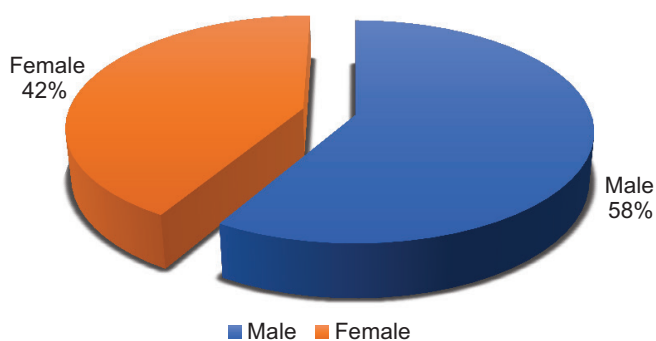
¹Senior Resident, Department of Radiodiagnosis, AIIMS, New Delhi, ²Senior Resident, Department of Radiodiagnosis, SKIMS, Srinagar, ³Senior Resident, Department of Radiodiagnosis, SKIMS, Srinagar

Corresponding author: Mohd. Saleem Dar, Senior Resident, Department of Radiodiagnosis, SKIMS, Srinagar

How to cite this article: Sayar Ahmad Taley, Kifayat Hussain Ganaie, Mohammad Saleem Dar. Diagnosis of spinal tuberculosis -a computed tomography study. International Journal of Contemporary Medical Research 2020;7(6):F1-F4.

DOI: <http://dx.doi.org/10.21276/ijcmr.2020.7.6.7>





Graph-1:

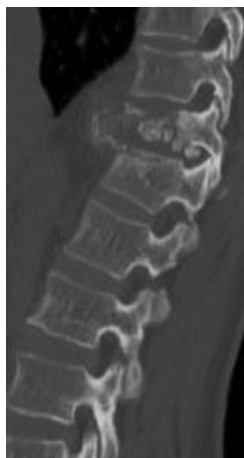

Figure-1:

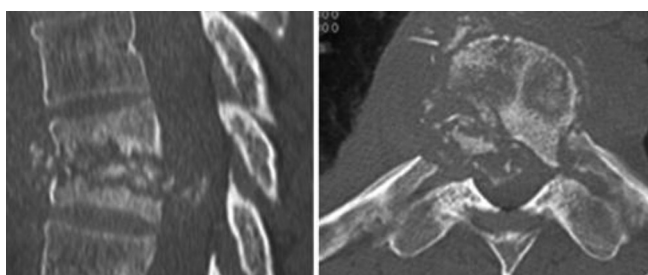


Figure-2:

3 patients were concomitantly suffering from: Type II Diabetes, RA (rheumatoid arthritis), and gout. The mean (\pm SD) time to diagnose from first clinical signs attributable to vertebral TB was 13.8 ± 4.0 months. The main presenting features included rachialgia in 93% of the cases, followed by spinal stiffness in 7 out of 14 patients (50%) and signs spinal compression in 7 out of 14 patients (50%). The diagnosis of TB was based on vertebral CT in all the 14 cases. The findings were perilesional osteocondensation in 14 out of 14 patients (100%) and 5 out of 14 cases showed sequestrum (5/14; 36%). According to the topography of these lesions, there was a clear predominance of lumbar lesions (8 out of 14 patients; 57%), followed by dorsal (5 out of 14 cases; 36%) and cervical lesions (1 out of 14 cases; 7%). The anti-TB medications consisting of 4 drugs rifampicin, isoniazid, pyrazinamide and ethambutol) were prescribed for the initial first two months, followed by two drugs (isoniazid and rifampicin) for the next 10 months. 43% of patients were at high risk, so a corset immobilization was given in such

patients. 2 out of 14 patients (14.2%) developed neurological complications, corticosteroid treatment in combination anti-TB medications resulted in clinical amelioration. 1 patient developed spinal abscess in thoracic region which was treated with antibiotics. Out of 14 cases, 11 recovered completely after 12 month of anti-TB chemotherapy, 1 patient underwent surgery and 2 patients died.

DISCUSSION

Pott's Spine is commonly observed in developing countries where the incidence and prevalence of TB is very high and in recent years has also been seen in developed countries due to unknown reasons.^{2,3} Skeletal TB usually involves spine followed by hip and knees. The epidemiology of musculoskeletal Tb remains unknown.⁴ In our study, the average age at the time of diagnosis was 46.5 years, which was similar to Fedoul et al., Johansen et al., N'Dri Oka and Colmenero et al.^{7, 9-11} A slight male preponderance of the disease has often been reported in the literature.^{8,12} Many studies reported patients with spinal TB belonged to lower social group^{8,13}, and many among them did not present with any signs of pulmonary TB.¹⁰ The risk factors that have been associated with spinal T include diabetes, nephropathy, and recent spine surgery.⁷ In this study, some cases had comorbid conditions like Type II diabetes, RA (rheumatoid arthritis), or gout. There are no characteristic signs and symptoms of Potts spine which makes delay in the initial diagnosis ranging from 1 to 26 months.^{6,8,14} In this study, the average delay in months was 13.8 months, which may be due to the initial excessive use of traditional medicine, not any access to health care facilities, and poverty. Most of the cases were afebrile during their initial visit, and routine laboratory results were not helpful in establishing the proper diagnosis. Inflammatory rachialgia in combination with spinal stiffness was the most common presenting features of Potts's Spine. In 12-50% of patients there are no signs of inflammation which means total absence of an inflammation does not preclude the diagnosis of spinal TB.¹⁵ One half of our cases had neurological complication which is similar to other studies.^{7,8,16} The neurological complications of spinal TB arise due to compression and extension of infectious process¹⁷

Standard vertebral X-ray may be normal in spinal TB and therefore is not an investigation of choice.¹⁸ CT scan is an essential diagnostic tool, especially in detecting abscess in vertebral canal. CT scan is used to visual bony destruction. The lesion in bones with sequestrum formation and peritoneal abscess containing bony fragments is, in some cases, pathognomonic of Skeletal tuberculosis.^{7,19} The presence of the following features have been reported by many authors as important diagnostic features: bony sequestrum, osteosclerosis, and epidural or soft tissue abscess.^{19,20} In this study, thoracolumbar region is most commonly affected, which is similar to other previous studies.^{6-8,21,22} This finding could be explained by the dispersion of TB from the initial pulmonary lesion via the lumbar, vertebral and intercostal vessels.²³ Involvement of cervix is very rare accounting

for 5% of all the Pott's Spine cases involved.^{7,24} Cervical involvement was observed in one patient in our study. Spinal TB usually involves one or more than one vertebrae. The involvement of more than 2 vertebral bodies is rare. Pain with Pott's spine usually affects 2 vertebral segments: cervico-lumbar, dorso-lumbar, or cervicodorsal segments.²⁵ Involvement of all the 3 spinal segments together is rarely reported in the world literature.²⁶ 93% of Spinal TB in this study was characterized by a single location. Other studies have also reported single involvement in more than 70% of cases.^{8,27} In this study, the diagnosis of Spine TB was based on clinical and radiological findings, especially vertebral CT and confirmed by response of lesion to anti-tubercular medications. The bacterial culture was not performed in our study. However, in developed countries with modern technological advances, the definitive diagnosis of spinal TB is based on bacterial culture of the organism. In the absence of sophisticated lab facilities for culture in developing countries, Vertebral CT is the best diagnostic method to detect spine TB. If MRI is available, it is more accurate in diagnosing spinal TB.

Surgery was performed in a single patient in this study. Since there are many risks associated with surgery and drug therapy alone may be adequate to cure Pott's Spine, Indications for surgery were as follows: failure of drug therapy, in paraplegic patients when surgery is the only option; acute compression due to bulky abscess and fistula or compression by sequestrum; or paraplegia with kyphosis. In this study, surgical intervention was performed in 7% of cases only. Other studies from the developing nation has a similar low rate of surgical treatment for spinal TB as was seen in our study.^{5,7,9,13,23,25,28}

The role of surgical intervention is controversial in case Pott's spine.^{23,24} Most of the authors do not recommend surgery but few advocates it, in case of nerve compression leading to neurological deficit. It may be beneficial in this subset of patients. In this study, screws were used for stable fixation and an osteosynthesis plate spanning the posterior pedicular D11-L2. Our results were similar other studies.^{13,18,25} A double anterior approach followed by posterior intervention is practiced in many developed countries which provides additional plaster and allows early mobilization. Despite surgery providing less kyphosis and more rapid pain relief, there are no evidence-based studies which show surgical intervention being better than medical management. Until then, a non-invasive medical management is preferred over surgical approach. As there are no clear guidelines to follow, the management will depend on case to case basis

The treatment for spinal TB is medical management and the drugs should be continued for 12 months.^{1,5,14,16,24,28-30}

Apart from drugs, immobilization and rest prevent the serious sequelae and alleviate the pain sequelae. 6 patients in our study had been immobilized and improved the case management in all of our patients. The complications of spinal TB include kyphosis, neurological deficit (motor and sensory impairment), spinal deformity, and abscess. Braces can be used to protect spine from the complication

of kyphoscoliosis. Neurological and spinal deficits can be avoided with effective anti-TB therapy. Abscess also gets reduced by antitubercular drugs.

CONCLUSION

CT scan can be used as an adjunctive tool besides history and physical examination for the initial diagnosis of spinal TB. Early diagnosis and prompt treatment can considerably improve the final outcome of spinal TB.

REFERENCES

1. World Health Organization, Global Tuberculosis Report 2014, WHO, Geneva, Switzerland, 2015.
2. R. N. Dunn and M. BenHusien. Spinal tuberculosis. *The Bone & Joint Journal*, 2018;100:425-431.
3. C. Ben Taarit, S. Turki, and H.Ma'iz, "La tuberculose ostéoarticulaire en Tunisie: étude rétrospective de 180 cas," *Médecine et Maladies Infectieuses*, 2003;33:210-214.
4. M. F. G. Held, S. Hoppe, M. Laubscher et al. Epidemiology of musculoskeletal tuberculosis in an area with high disease prevalence. *Asian Spine Journal*, 2017;11:405-411.
5. M. P. Gautam, P. Karki, S. Rijal, and R. Singh. Pott's spine and paraplegia. *J Nepal Med Assoc*, 2005;44:106-115.
6. H. Annabi, M. Abdelkafi, and M. Trabelsi. La tuberculose ostéo-articulaire. *Tun Orthop.*, 2008;1:7-17.
7. B. Fedoul, K. Chakour, and M. El Faiz Chaoui. Le mal de Pott: à propos de 82 cas. *Pan African Medical Journal*, 2011;8:22.
8. M. Gban'è-Kon'è, B. Ouattara, M. Diomand'è et al. Apport de la tomodensitométrie dans le diagnostic de la tuberculose vertébrale à propos de 496 cas à Abidjan. *Pan African Medical Journal* 2015;20:201.
9. I. S. Johansen, S. L. Nielsen, M. Hove et al. Characteristics and clinical outcome of bone and joint tuberculosis from 1994 to 2011: a retrospective register-based study in Denmark. *Clinical Infectious Diseases*, 2015;61:554-562.
10. D. N'Dri Oka, M.-A. N'Dri-Yoboue, G. Varlet, A. Haidara, and V. Ba Zeze. Spinal tuberculosis. Epidemiologic and diagnostic aspects: A study of 28 clinical observations. *Cahiers/Santé*, 2004;14:81-84.
11. J. D. Colmenero, M. E. Jim'enez-Mej'ias, J. M. Reguera, J. Palomino-Nic'as, J. D. Ruiz-Mesa, J. M'arquez-Rivas et al., "Tuberculous vertebral osteomyelitis in the new millennium: still a diagnostic and therapeutic challenge," *European Journal of Clinical Microbiology & Infectious Diseases*, 2004;23:477-483.
12. Y. Toloba, S. Diallo, Y. Maiga et al. Spinal tuberculosis (Pott's disease): epidemiological, clinical, radiological and evolutionary aspects at the University Hospital of Point G. *Le Mali Médical*, 2011; 26:8-11.
13. V. Narayan, N.Mohammed, A. R. Savardekar, D. P. Patra, and A. Nanda. Tuberculous spondylolisthesis: a reappraisal of the clinicoradiologic spectrum and surgical treatment paradigm. *World Neurosurgery* 2018;114:361-367.
14. N. Meddeb, N. Rammeh, M. Chahed, H. Sahli, M.

- Elleuch, E. Cheour et al. Aspects actuels du mal de Pott en Tunisie. A propos d'une s'erie de 29 cas. *Bull Soc Pathol Exot* 2002;95:269–271.
15. V. Barrière, P. Gepner, F. Bricaire, O. Bl'etry, and E. Caumes. Aspects actuels de la tuberculose vert'ebrale α propos de 16 observations. *Ann Med Interna*, 1999;150:363–369.
 16. E. Eti, J. C. Daboiko, K. F. Brou, B. Ouali, B. Ouattara, K. D. Koffi et al., "Tuberculose vert'ebrale Notre exp'erieence `a partird'une `etude de 147 cas dans le service de rhumatologie duCHU de Cocody (Abidjan, C^ote d'Ivoire)," *M`ed Afr Noir*, 2010;57:287–292.
 17. F.Z.BensalahandC.Dziri.Placedelam`edecinephysique et de r`eadaptation fonctionnelle dans le traitement des spondylodiscites. *Journal de R`eadaptation M`edicale: Pratique et Formation enM`edecine Physique et de R`eadaptation*, 2005;25:119–121.
 18. A. Zaoui, S. Kanoun, H. Boughamoura et al. Patients with complicated Pott's disease: Management in a rehabilitation department and functional prognosis. *Annals of Physical and Rehabilitation Medicine*, 2012;55:190–200.
 19. R. Jain, S. Sawhney, and M. Berry. Computer tomography of vertebral tuberculosis: Patterns of bone destruction. *Clinical Radiology*, 1993;47:196–199.
 20. H. S. Sharif and J. L. Morgan. Role of CT and MR imaging in the management of tuberculous spondylitis. *Radiol Clin North Am*, 1995;33:787–804.
 21. A. Cotten, R. M. Flipo, M. H. Drouot, F. Maury, P. Chastanet, B. Duquesnoy et al. La tuberculose vert'ebrale: `etude des aspects cliniques et radiologiques `a partir d'une s'erie de 82 cas. *J Radiol*, 1996;77:419–426.
 22. N. Cherif Idrissi El Ganouni, M. Khalil, M. Hiroual et al. Apport de l'IRM dans les compressions m`edullaires lentes d'origine tumorale et infectieuse. *Feuillets de Radiologie* 2009;49:251–262.
 23. R. K. Garg and D. S. Somvanshi. Spinal tuberculosis: a review. *The Journal of Spinal CordMedicine* 2011;34:440–454.
 24. M. Gban'e-Kon'e, B. Ouali, A. K. Coulibaly, M. Diomand'e, J. C. Yao, E. Eti et al. Cervical spine in Pott's disease: Epidemiological, clinical and radiological aspects concerning 26 cases Mali M`ed, 2015;30:15–18.
 25. E. S.Nussbaum, G. L. Rockswold, T.A. Bergman,D. L. Erickson, and E. L. Seljeskog. Spinal tuberculosis: A diagnostic and management challenge. *Journal of Neurosurgery*, 1995;83:243–247.
 26. B. Eljebbouri, H. Baallal, O. Naama, M. Gazzaz, and M. Boucetta. Spondylodiscite tuberculeuse multifocale non contigu`e. *Rev Mar Rhum*, 2012;20:42–44.
 27. A. Ousehal, A. Gharbi, W. Zamiaty, A. Saidi, and R. Kadiri. Imaging findings in 122 cases of Pott's disease. *Neurochirurgie* 2002;48:409–418.
 28. J. Yilboudo, S. C. Da, S. I. Nacoulma, and E. Bandre. Tuberculous spondylodiscitis with neurologic problems: results of surgical treatment. *Med Trop* 2002;62:39–46.
 29. T. Degen and T. Bregenzer. The treatment of tuberculosis. *Praxis* 2016;105:457–461.
 30. F. Tritar, H. Daghfous, S. Ben Saad, and L. Slim-Saidi.

Management of multidrug-resistant tuberculosis. *Revue de Pneumologie Clinique* 2015;71:130–139.

Source of Support: Nil; **Conflict of Interest:** None

Submitted: 31-03-2020; **Accepted:** 12-05-2020; **Published:** 18-06-2020