

The Functional Outcome Volar Barton Fracture Treated by Open Reduction and Internal Fixation with T Plate – A Prospective Study

Harikrishnan Balakrishna Pillai¹, Suraj Sankar², Surendra Singh Rawat³, Samarth Arya⁴, Pradeep Jadhav⁵

ABSTRACT

Introduction: Barton's fracture is fracture-dislocation of radiocarpal joint with the intra-articular fracture involving the volar or dorsal lip. These injuries are inherently unstable demanding open reduction and internal fixation. We present our experience with buttress plate fixation for volar Barton's fracture with Ellis T-plate. Aims: To evaluate the functional outcome and complications in volar Barton's fracture treated by open reduction and internal fixation with T plate.

Material and methods: This case series study was conducted between January 2012 and November 2012 at Department of Orthopaedics, Government Medical College Thiruvananthapuram. The patients in the age group 18 -75 years who were treated by ORIF for volar Barton fractures were included in the study. During follow up, subjective and objective assessments were done and the patient's functional status was evaluated with modified clinical scoring system of Green and O'Brien. The 32 patients involved were followed up for eleven months. The descriptive data were analysed using 'SPSS' and conclusions were made based on it.

Results: Wrist functions as assessed by Green and O'Brien score showed 84.4% patients with excellent to good results. Five patients had either fair or poor outcome. None of these variables were found to have any significant effect on the final outcome.

Conclusions: Ellis T plate is a simple and cheap implant which provides effective volar distal buttressing in treatment of volar Barton fractures. Our study shows encouraging results with good functional results. Also, there is a relatively short learning curve and the implant is cost effective.

Keywords: Volar Barton, Fracture, Open Reduction and Internal Fixation, T Plate

fixation (ORIF). Conservative treatment of these injuries result in complications, such as osteoarthritis, mal-union, subluxation, and instability.^{4,5} Open reduction and internal fixation is the preferred method as this allows reduction under direct vision, stable internal fixation, shorter period of immobilization, and fast return of function.⁶ The use of the T-plate in the management of these fractures is a simple, effective method in achieving union and good hand function. We present our experience in the use of this buttress plate in this paper and try to determine the functional outcome of patients with volar Barton's fracture treated surgically with a small buttress T plate.

Aims and objectives

Aims of the present study is to evaluate the functional outcome in volar Barton's fracture treated by open reduction and internal fixation with T plate. Additionally, we try to determine the demographic profile of this type of injury and the complications with this treatment.

MATERIAL AND METHODS

This prospective case series study was done between January 2012 and November 2012 at the Department of Orthopaedics, Government Medical College, Trivandrum.

Study was done on patients admitted with volar rim fracture of distal end radius coming to Orthopaedics, outpatient clinics and Emergency department.

Sample Size: A total of 33 patients were assessed and one of them lost to follow up due to unknown reasons, the rest of 32 patients were followed up for eleven months.

Inclusion Criteria: The patients of age between 18 – 75

INTRODUCTION

Barton's fracture is fracture-dislocation of radiocarpal joint with the intra-articular fracture involving the volar or dorsal lip. However, in this type of injury, the radiocarpal integrity is maintained as there is no disruption of radiocarpal ligaments.^{1,2,3} High velocity trauma results in this fracture in the young adults, while the reason in the elderly majority are due to falls.

Displaced intraarticular fractures of distal radius have a worse prognosis than extra-articular fractures because of the potential for incongruity and arthrosis of the radiocarpal and distal radioulnar joints, carpal subluxation, and associated inter-carpal ligament injuries. Variety of treatment approaches are being described for intra-articular distal radial fractures from closed reduction and casting, percutaneous pinning, external fixator and open reduction and internal

¹Consultant Orthopaedician, Padmavathi Hospital, Kollam, Kerala, India, ²Speciality Registrar, Trauma and Orthopaedics, Wrightington, Wigan and Leigh NHS Foundation Trust, UK, ³Speciality Registrar, Trauma and Orthopaedics, Wrightington, Wigan and Leigh NHS Foundation Trust, UK, ⁴Speciality Registrar, Trauma and Orthopaedics, Wrightington, Wigan and Leigh NHS Foundation Trust, UK, ⁵Senior Resident, Trauma and Orthopaedics, B J Government Medical College, & Sassoon General Hospital, Pune, India

Corresponding author: Suraj Sankar, 13 Clifton Crescent, Wigan, UK, WN1 2LB

How to cite this article: Harikrishnan Balakrishna Pillai, Suraj Sankar, Surendra Singh Rawat, Samarth Arya, Pradeep Jadhav. The functional outcome volar Barton fracture treated by open reduction and internal fixation with T plate – a prospective study. International Journal of Contemporary Medical Research 2020;7(6):F7-F11.

DOI: <http://dx.doi.org/10.21276/ijcmr.2020.7.6.6>



years of either gender presenting within 48 hours of the injury were included in the study.

Exclusion Criteria: The following patients were excluded from the study: open fractures (Gustilo classification >1), previous fractures of the distal end radius, die punch fractures, dorsal Barton fractures and all patients who were not willing to give consent to take part in the study.

Study Procedure

This case series study was conducted between January 2012 and November 2012 at Department of Orthopaedics, Government Medical College Thiruvananthapuram. In all the cases, pre-operative diagnosis was made with X-ray. In patients who fulfilled the inclusion criteria, ORIF with T-plate was done by Ellis approach to distal end radius. All surgeries were done under Regional Anaesthesia by brachial plexus blockade and was performed by an Orthopaedic consultant or Resident with more than two years' experience. Post-operative X-rays were taken to evaluate the adequacy of reduction. Patients were treated by immobilization with a short arm slab for 3 weeks. During further follow up, subjective and objective assessments were done. Subjective assessment included pain, return to previous occupation, functional outcome and patient satisfaction. Objective assessment included deformity, wrist movements and loss of grip strength (measured with handheld dynamometer by comparing with contralateral wrist) and neurovascular function. On final follow up, the patient's functional status was evaluated with Modified Clinical Scoring system of Green and O'Brien (Table 1). This score is compared most favourably with the widely used Disabilities of the Arm, Shoulder, and Hand (DASH) questionnaire.⁷ Radiological parameters were evaluated for fracture union, radiocarpal alignment, volar angulation, radial inclination, ulnar variance, articular step and arthritic changes.

STATISTICAL ANALYSIS

A total of 33 patients were assessed and one of them lost to follow up due to unknown reasons, rest of 32 patients were followed up for a period of eleven months. The descriptive data were analysed using 'SPSS' and conclusions were made based on it. Mean and standard deviation were calculated for age, gender, mode of injury, associated injuries, fracture type, wrist movements, radiological parameters and complications, comparisons were made with the final outcome using Chi square test (p <.05).

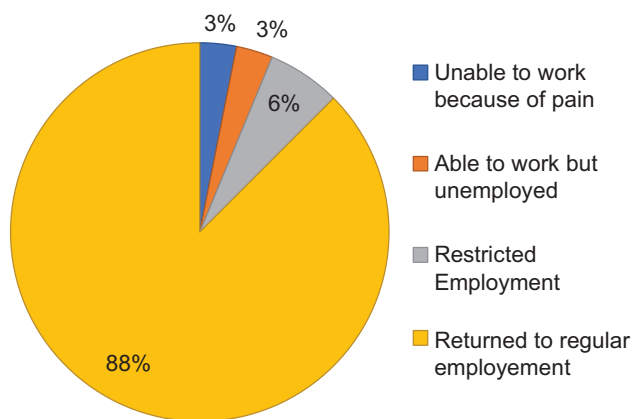
RESULTS

In the present study, 93.7% of the patients with volar Barton's fracture belonged to the age group less than 50 years. Only two patients in this study were more than 50 years. Most of the patients were males, only two were females. This sex predilection for males could be due to a high association of volar Barton's fracture with their level of activity. There was no particular job predilection for this fracture but, were found to be more common in students (28.1%) and other young people susceptible to motor vehicle accidents. 78.1% of patients had motor vehicle accident as the mechanism of

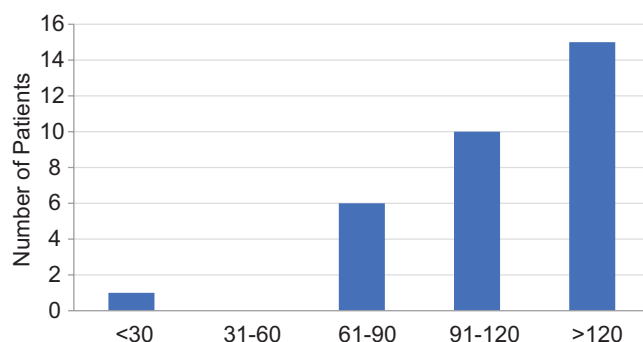
injury. 71.9% of the patients had fracture of the right wrist. 62.5% patients had AO type B3:3 and 34.4% had type B3:2 volar Barton's fracture. Of the many associated injuries sustained along with this fracture, ipsilateral ulnar styloid fracture was the most common.

During the final follow up, 75% of the patients did not have any pain. 21.9% patients had mild pain but most of them returned to their regular employment. One patient had moderate pain affecting wrist movements. Majority of the patients (90.1%) returned to their regular employment. Two patients had restricted employment, one with moderate stiffness of the wrist joint and other due to mild pain and stiffness. One patient was unable to work because of the pain and stiffness due to infection (Graph 1).

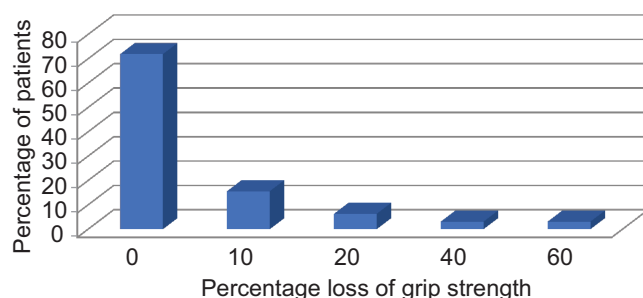
Palmar flexion dorsiflexion arc was an important outcome variable found to be above 90° in 78.2% of patients. In this, 47% patients had above 120° range. Only one patient had a range less than 30° which was due to the stiffness followed by the infection (Graph 2). Grip strength of both hand



Graph-1: Functional status



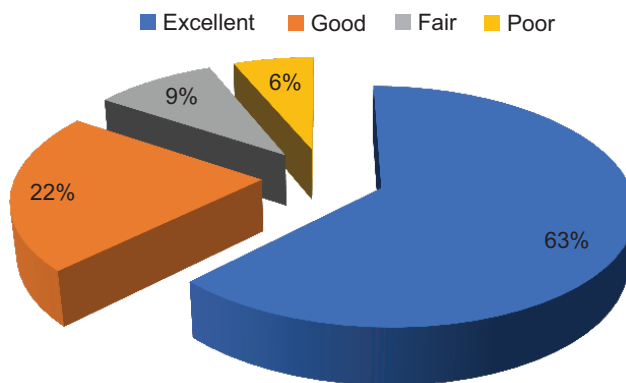
Graph-2: Palmar flexion – dorsiflexion ARC



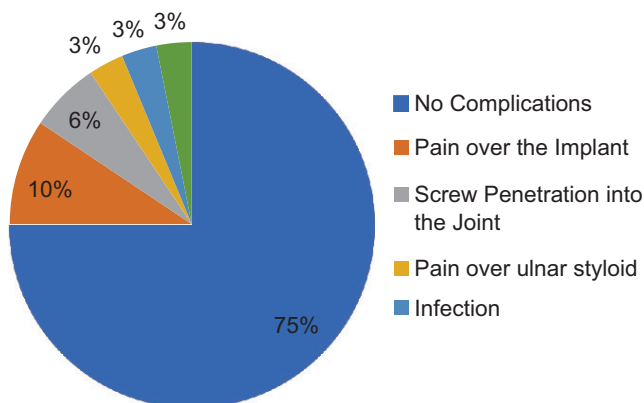
Graph-3: Grip strength

Parameter	Points	Grading
Pain	25	None
	20	Mild, occasional
	15	Moderate, tolerable
	0	Severe, intolerable
Functional Status	25	Returned to employment
	20	Restricted employment
	15	Able to work but unemployed
	0	Unable to work
Range of Motion		DF- PF arc
	25	>120 degrees
	15	91-120
	10	61-90
	5	31-60
	0	<30
Grip Strength		Percentage of normal
	25	100
	15	75 - 99
	10	50 - 74
	0	0 - 24
Score		
Excellent	90 -100	
Good	80 - 89	
Fair	65 -79	
Poor	< 65	

Table-1: Modified clinical scoring of Green and O'Brien



Graph-4: Modified green and O'Brien scoring



Graph-5: Summary of complications

	Outcome				Total	
	Excellent to Good		Fair to Poor			
Complication	N	%	N	%	N	%
Absent	22	91.7	2	8.3	24	100
Present	5	62.5	3	37.5	8	100
Total	27	84.4	5	15.6	32	100
Pearson Chi- Square	3.872	1	0.049			

Table-2: Association of complications and functional outcome

measured with a hand-held dynamometer and loss of grip strength was calculated. 71.9% of the patient regained their normal grip strength. Two patients had 40 to 60% loss of their grip strength which affected daily activities (Graph 3). Wrist functions as assessed by Green and O'Brien score showed 84.4% patients with excellent to good results. Five patients had either fair or poor outcome. In this one patient had pain and stiffness of the wrist due to the infection and two cases with screw penetration into the joint. Two patients had fair outcome due to the stiffness of the wrist joint (Graph 4). The study shows good range of wrist movements in all patients belonging to good to excellent results. Mean palmar flexion – dorsiflexion arc was 116.7°, mean ulnar deviation was 39.8°, mean radial deviation was 18.3°, mean pronation and supination was 78.1° and 81.3° in 84.4% patients. Age, sex and mode of injury showed no significant association with final outcome as per Chi square analysis. Majority of the cases were due to motor vehicle accident. There was no significant association between associated injuries and final outcome. Most common associated injury in the patient was the fracture ulnar styloid on the same side,

which did not have any influence on functional outcome. In this study, there was no significant association found between the type of the volar Barton and final outcome. Most of the fracture belonged type B3:3 and showed 85% excellent to good result. No patients had any arthritic change or other long-term complication. Radiological variables studied were radio ulnar variance, volar angulation, ulnar angulation and the articular step and their influence in the final outcome. None of these variables were found to have any significant effect on the final outcome. Over all 25% of patients had some complications (Graph 5). Most common complication was found to be pain over the implant site (9.4%). Other complications found were screw penetration into the joint, pain over the ulnar styloid, infection, injury to the sensory branch of median nerve. Pearson chi square test showed, there was significant association between complications and final outcome. Out of five patients with fair to poor outcome three had some complications. They were due to pain and stiffness of the wrist joint caused by two cases of screw penetration and one case of infection (Table 2).

DISCUSSION

Volar Barton fractures are unstable injuries that constitute 1.5 – 10.5% of distal radial fractures.⁸ Closed reduction manoeuvres become unsuccessful because of the fracture obliquity, inadequate carpal bone support and due to the proximal pull exerted by the flexor muscle mass. Early studies have proven the superiority of open reduction and internal fixation in these types of fractures compared to conservative treatment.^{9,10} Most recent literature advocates the use of variable angle locking plates to address the fracture comminution and instability.¹¹ However, in many parts of the world, these implants remain inaccessible for routine use due to the cost factors involved. Ellis T plate is a simple and effective implant which can provide good functional outcome in these circumstances.

In the present study 93.7% of the patients belong to the age group of less than 50 years. This signifies that volar Barton's fractures are more common in young age group those who have relatively good bone stock. This finding is supported by previous studies.¹² The increase in incidence of road traffic accidents which is more common in young people may also be a contributing factor for this increase in incidence. Since this is an age group in which majority are earning members of the family, economic impact of this type of fracture in the society will be high.

Volar Barton's fracture in this study is more common in males (93.8%) as compared to females. This may be due to their increase in the level of activity. Males are more susceptible to high energy trauma, which is the usual cause of this fracture. 72% of the patient have fracture on the right wrist, which may be due to the increase incidence of right-hand dominance in the general population. As a reflex mechanism, people generally using their dominant hand to protect themselves, could explain this. Motor bike accidents are the most common mode of injury (65.6%). As suggested by Thompson and Grant¹³, this is due to compressive forces acting on wrist locked in flexion while holding the handle of bike. Volar Barton fracture with comminution (type B3:3) is the most common fracture type observed in this study. The violent trauma which is the usual culprit of this type of fracture may account for this. Fifty percent of volar Barton's fracture has some associated injury. Fracture of ipsilateral ulnar styloid is the most common type of injury associated with volar Barton's fracture. In the final analysis, there is no significant association between fracture ulnar styloid and final functional outcome. This is supported by an earlier study.¹⁴

In this study, 84.4% of patient have either excellent or good outcome. This result is comparable with many other similar studies.^{7,15,16,17} All patients in this study show good bony union and normal radiocarpal alignment in the final follow-up. Volar angulation, ulnar angulation and radioulnar variance in the final follow-up are acceptable in all patients which do not show any influence in the final functional outcome. Even though the articular step is more than 2mm in some patients, there is no osteoarthritis in any patients. This could

be because of the short-term nature of the study and further follow up may be needed to identify these changes. 75% of the patients in this do not show any complications. Pain over the implant is the most common complication seen in this study (9.4%). Two patients had infection seriously affecting their wrist function. Patients with these two complications have either fair or poor outcome in this study. Loss of reduction, sympathetic mediated pain, extensor pollicis rupture and deep vein thrombosis are the other complications described with volar buttress plating in earlier studies.⁸ But these complications are not seen in any patient in this study. There are limitations in this study. Firstly, this is a case series study and the number of patients involved are less to draw definite conclusions. Secondly, the better results might be due to the short follow up period as we are unaware of the long-term outcomes. In addition to this, recent literature emphasises the importance of fragment specific fixation in case of comminuted fractures.^{18,19}

CONCLUSION

Ellis T plate is a simple and cheap implant which provides effective volar distal buttressing and gives good functional outcomes in treatment of volar Barton fractures. The assessment of function is demonstrated using the Modified Clinical Scoring System of Green and O'Brien showing 84.4% good outcomes. Moreover, 75% patients do not have any complications in this study. Our study shows encouraging results. Also, there is a relatively short learning curve and the implant is cost effective.

REFERENCES

1. Barton DW, Griffin DC, Carmouche JJ. Orthopedic surgeons' views on the osteoporosis care gap and potential solutions: survey results. *J Orthop Surg Res.* 2019;14:72.
2. Mauck BM, Swigler CW. Evidence-Based Review of Distal Radius Fractures. *Orthop. Clin. North Am.* 2018;49:211-222.
3. Wæver D, Madsen ML, Rölfing JHD, Borris LC, Henriksen M, Nagel LL, Thorninger R. Distal radius fractures are difficult to classify. *Injury.* 2018;49 Suppl 1:S29-S32.
4. Caporrino FA, Belotti JC, Ulson HJR, Toledo LFF. Fractures da extremidade distal do rádio e da ulna. In: Pardini Júnior AG, Freitas A. *Traumatismos da mão.* Rio de Janeiro: MedBook. 2008; 4:411-45.
5. Nana AD, Joshi A, Lichtman DM. Plating of the distal radius. *J Am Acad Orthop Surg.* 2005;13:159-71
6. Chung KC, Watt AJ, Kotsis SV. Treatment of unstable distal radial fractures with the volar locking plating system. *J Bone Joint Surg Am.* 2006; 88:2687-94.
7. Kwok I, Leung F, Yuen G. Assessing Results After Distal Radius Fracture Treatment. *Geriatric Orthopaedic Surgery & Rehabilitation.* 2011;2:155-160.
8. Mehara AK, Rastogi S, Bhan S, Dave PK. Classification and treatment of volar Barton fractures. *Injury* 1993; 24: 55.
9. Keating JF, Court-Brown CM, and McQueen MM. Internal fixation of volar-displaced distal radial

- fractures. *J. Bone and Joint Surg*, 1994;76: 404- 405.
10. van Leeuwen PA, Reynders PA, Rommens PM and Broos PL. Operative treatment of Smith-Goyrand fractures. *Injury* 1990;21: 358-360.
 11. Pedersen J, Mortensen S, Rölfing J, Thorninger R. A protocol for a single-center, single-blinded randomized-controlled trial investigating volar plating versus conservative treatment of unstable distal radius fractures in patients older than 65 years. *BMC Musculoskeletal Disorders*. 2019;20(1).
 12. Arora S. Outcome of Intra-Articular Fractures of the Distal End of the Radius Managed Using Volar Variable Angle Locking Plate. *Journal of Orthopedics & Bone Disorders*. 2017;1(8).
 13. Thompson G, Grant T. Barton's Fractures-Reverse Barton's Fractures. *Clinical Orthopaedics and Related Research*. 1977; 122: 210-221.
 14. Kim J, Koh Y, Do N. Should an Ulnar Styloid Fracture Be Fixed Following Volar Plate Fixation of a Distal Radial Fracture?. *The Journal of Bone and Joint Surgery - American Volume*. 2010;92:1-6.
 15. Aggarwal A, Nagi O. Open Reduction and Internal Fixation of Volar Barton's Fractures: A Prospective Study. *Journal of Orthopaedic Surgery*. 2004;12:230-234.
 16. Pattee AG, and Thompson GH. (L988) Anterior and posterior marginal fracture-dislocation and the distal radius. *C/ill. Orfflop*. 231: 183.
 17. Zoubos A, Babis G, Korres D, Pantazopoulos T. Surgical treatment of 35 volar Barton fractures. *Acta Orthopaedica Scandinavica*. 1997;68:65-68.
 18. Lenz M, Wahl D, Gueorguiev B, Jupiter J, Perren S. Concept of variable angle locking-evolution and mechanical evaluation of a recent technology. *Journal of Orthopaedic Research*. 2015;33:988-992.
 19. Martineau D, Shorez J, Beran C, Dass AG. Biomechanical performance of variable and fixed angle locked volar plates for the dorsally comminuted distal radius. *Journal Iowa Orthop J*. 2014; 34: 123–28.

Source of Support: Nil; **Conflict of Interest:** None

Submitted: 20-04-2020; **Accepted:** 18-05-2020; **Published:** 14-06-2020