

# Surgical Treatment of Cardiac Tumors: A Single Institutional Experience Over 12 Years

Kallol Dasbaksi<sup>1</sup>, Mohammad Zahid Hossain<sup>2</sup>, Suranjan Haldar<sup>3</sup>, Plaban Mukherjee<sup>4</sup>

## ABSTRACT

**Introduction:** Tumors of the heart represent an exceedingly rare entity in cardiac surgery and literature regarding management and outcome is less in comparison to other fields of cardiac surgery. 12 years of our experience in both diagnosis and optimal surgical treatment of this small but rare collection of patients was formed into a detailed analysis of patient prognosis, mean survival and risk of tumor relapse matched to the corresponding pathology. The overall objective of the present study was a thorough characterization of both primary cardiac tumor or tumor like mass and secondary malignant tumor mass in cardiac chambers, their nature as well as age and gender distribution and management.

**Material and methods:** 17 patients with cardiac tumors, who underwent open-heart surgery at Medical College and Hospitals, Kolkata, for tumor excision between 2007 and 2019 were analyzed retrospectively. Mean follow-up was from 11 to 1 years.

**Results:** There were 2 males and 15 female patients ranging in age from 7 years to 60 years, median age being 47 years. 12 of these tumors were primary left atrial myxoma, 2 were right atrial myxoma, 1 was right ventricular fibroma, 1 was intravenous extension into right atrium of renal cell carcinoma and 1 was multiple inflammatory pseudo tumors in left ventricle. Overall operative survival was 88.3%. Operative mortality was 11.7%.

**Conclusion:** Cardiac tumors remain challenging in the clinical setting. Early operation is recommended after echocardiographic diagnosis as such patients can have sudden death or severe cardiac failure during preoperative waiting period. Follow up should be maintained based upon the histopathological diagnosis.

**Keywords:** Primary Cardiac Tumors, Left Atrial Myxoma, Right Atrial myxoma, Right Ventricular Fibroma, Inflammatory Pseudo Tumor

and bears fairly decent prognosis.<sup>6</sup> Primary tumors in children are mostly cardiac rhabdomyoma (CR) followed by cardiac fibroma (CF), teratomas etc.<sup>7</sup> CR and CFs are often located in the wall of ventricles while exclusive intracavitary locations like LAM or RAM are rare in young children. First cardiac neoplasm was described in 1559 by Realdo Colombo (circa. 1510-1559), Vesalius' successor at Padua, Italy.<sup>2</sup> The first reports on intracavitary mass formation of the heart was from Belgium in 1685 when Zollicoffer wrote "de polypo cordis". Later it was also reported by Theophy Boneti (1700).<sup>1</sup> Based upon the data of 22 large autopsy series, McAllister et al reported the frequency of primary cardiac tumors to be approximately 0.02%, corresponding to 200 tumors in 1 million autopsies.<sup>8,9</sup> Primary cardiac tumors in the pediatric age group are even rarer with a prevalence of 0.0017 to 0.28%. Most of those cases reported are CR, CF and teratomas.<sup>7</sup>

Bahnon and Newman performed the first open surgical excision of a primary RA tumor using the inflow obstruction technique for 1 minute, without hypothermia, through right lateral thoracotomy in 1952. 2 years later Crafoord et al. reported the first successful atrial myxoma excision using cardio pulmonary bypass (CPB) in a 40 year old lady.<sup>2,10</sup>

Unless obstructing the intracardiac flow or interfering with the valvular function, cardiac neoplasms do have the potential to remain clinically silent until they reach an advanced stage<sup>10</sup>, thereby limiting therapeutic options especially for those with malignant transformations.<sup>11</sup> The majority of primary cardiac tumors are benign with more than 80% being myxomas in various locations and dyspnea being the most common reason for initial clinical consultation.<sup>12</sup> Clinical presentation mostly depends on the cardiac chamber involved. The overall objective of the present study was a thorough characterization of both primary cardiac tumor

## INTRODUCTION

Cardiac tumors, both benign and malignant represent rare diseases and literature on both management and outcome were quite limited till the era of open heart surgery in 1952.<sup>1,2</sup> While most common benign primary cardiac tumor is left atrial (LA) myxoma (LAM), myxomas in ventricles are rare.<sup>3</sup> But right atrial (RA) myxomas (RAM) are more common than ventricular myxoma.<sup>4</sup> Metastases from breast carcinoma, or direct extension from adjacent lung carcinoma are more common than primary cardiac tumors, both benign and malignant<sup>5</sup> and are often deemed inoperable. But, extension of renal cell carcinoma (RCC) into adjacent inferior vena cava (IVC) and right atrium (RA) are often resectable

<sup>1</sup>Associate Professor, <sup>2</sup>Assistant Professor, <sup>3</sup>Assistant Professor, <sup>4</sup>Professor and HOD, Department of Cardiothoracic Surgery, Medical College Kolkata, 88, College Street, Kolkata-700073, India

**Corresponding author:** Dr. Kallol Dasbaksi, Associate Professor, Department of Cardiothoracic Surgery, Medical College Kolkata, 88, College Street, Kolkata-700073, India

**How to cite this article:** Kallol Dasbaksi, Mohammad Zahid Hossain, Suranjan Haldar, Plaban Mukherjee. Surgical treatment of cardiac tumors: a single institutional experience over 12 years. International Journal of Contemporary Medical Research 2020;7(2):B1-B6.

**DOI:** <http://dx.doi.org/10.21276/ijcmr.2020.7.2.15>



or tumor like mass and secondary malignant tumor mass in cardiac chambers, their nature as well as age and gender distribution, and specific management to circumvent the adverse pathophysiology in more advanced cases.

## MATERIAL AND METHODS

From 2007 to 2019, we performed operations on 17 patients with cardiac tumors in Medical College and Hospitals, Kolkata. Records of these patients were retrieved for the study from 1st January 2007 to 31st December, 2019. This study was approved by the ethics committee of our institution and being retrospective in nature, consent of patients were waived off. Diagnosis was confirmed by echocardiography. Other investigations like ultrasonography and contrast enhanced computerized tomogram (CECT) were done when required. All these data are compiled in Table No.1.

**Inclusion criteria:** All patients admitted with diagnosis of cardiac mass which were fit for resection.

### Exclusion criteria

1. Patients with untreated primary malignant tumor with metastasis in the heart.
2. Patients with treated primary malignant tumor treated but cardiac tumor diagnosed to be non resectable.

**Data collection:** A detailed history was taken to extract baseline demographic characteristics like age, sex, presenting symptoms, duration of presenting illness, any preexisting medical illness, treatment history of the cardiac ailments in all the patients. Diagnostic workup with ECG and USG of abdomen, X-ray of chest, to assess the localization of tumor and to rule out any primary abdominal malignancy were done. In case of RCC invasion of IVC and RA, resectability of primary malignant tumor in kidney was determined by contrast enhanced computed tomogram (CECT) and USG abdomen (Figure-4A and B). In most of the patients with

preoperative provisional LA and RA myxoma, trans atrial approach was done under CPB to excise the tumors with the attached portion of inter atrial septum. The tumor was delivered from RA cavity. Left atrial approach in addition was done in larger tumor masses. The typical myxoma tumors are soft, pedunculated and have polypoid projections. Some of these projections are villous soft and friable (Figure-1). TCA was done in the case of tumor extension of RCC into RA through IVC. In case CF in right ventricle (RV), pulmonary arterial incision was made (Figure-3B) to excise the tumor. Perioperative data were collected. Standard postoperative management in the ITU was done with initial ventilator and inotropic support. Tissue biopsy of the tumor was obtained in all cases.

## STATISTICAL ANALYSIS

All the datas were processed in Microsoft XL, tabulation done, and statistical averages and relevant proportion were calculated. No further statistical tests could be done due to small numbers of these cases.

## RESULTS

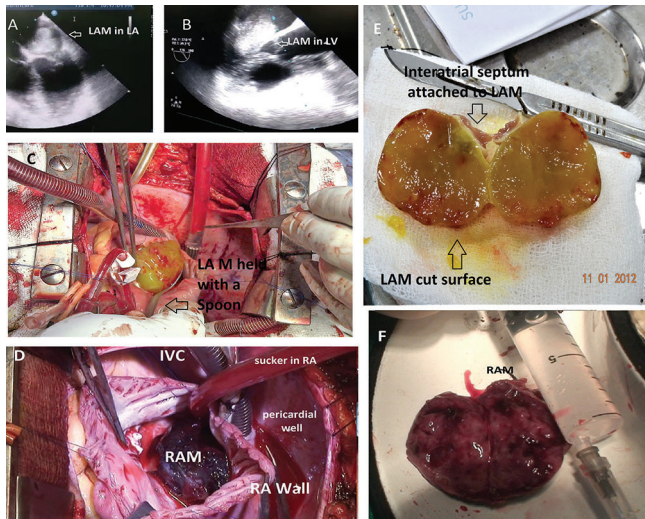
**Sex distribution:** Out of the total of 17 patients there were 2 males and 15 females.

**Age distribution:** The maximum numbers of patients were in the age group of 35-60 (69.23%), median age being 47 years. Youngest patient was 7 while the oldest patient was 60 yrs. Average age was 42.52 years. There were 2 (11%) males and 15 (89%) females. The majority of patients were adult females (34-60) years. All adult females with LA or RA mass were diagnosed as benign myxoma, being LAM (70.5%) in 12 and RAM (29.5%) in 2. One LAM recurred after 2 years and was reoperated successfully. A single case of RV mass in a 8 year old female child was confirmed as CF, and multiple LV mass in another 7 year old male child was

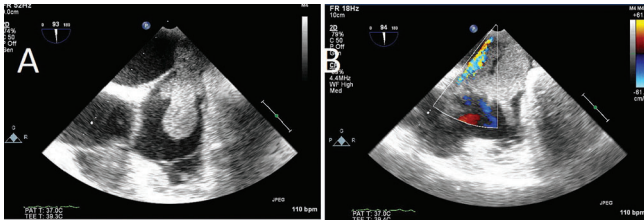
Sl no	Age	Sex	Presentation	Pathology	Status	Follow up
1	52	F	CCF	LA Myxoma	Survived	doing well
2	52	F	CCF	LA Myxoma	Survived	doing well
3	47	F	CCF	LA Myxoma	Recurrence	doing well
4	8	F	Syncope	RV fibroma	Survived	doing well
5	54	F	Femoral TE	LA Myxoma	Survived	doing well
6	57	M	IVC obstruction	Renal cell CA	Survived	doing well
7	60	F	CVA	LA Myxoma	Survived	doing well
8	7	M	SOB	LV multiple IPT	Died	
9	48	F	Orthopnea	LA Myxoma	Survived	doing well
10	48	F	Orthopnea + ARF	LA Myxoma	Died	
11	43	F	Rt heart failure	RA myxoma	survived	doing well
12	35	F	CCF	LA Myxoma	Survived	doing well
13	46	F	CCF	LA Myxoma	Survived	doing well
14	38	F	Orthopnea	LA Myxoma	Survived	doing well
15	45	F	CCF	LA Myxoma	Survived	doing well
16	34	F	Rt heart failure	RA myxoma	Survived	doing well
17	49	F	CCF	LA Myxoma	Survived	doing well

CCF = congestive cardiac failure, TE = thromboembolism, CVA = cerebro vascular accident, Rt = right, RV = right ventricle, RA = right atrium, LA = left atrial, LV = left ventricle, IPT = Inflammatory pseudo tumor, SOB = shortness of breath, ARF = acur renal failure, IVC = inferior vena cava, CA = carcinoma.

**Table-1:** Baseline characteristics, presentation, histopathology, results of operation of patients with intra cardiac mass



**Figure-1:** LA and RA MYXOMA intra operative pictures. TEE in A, shows LAM in the LA during systole and B, prolapsing through the mitral valve into LV in diastole. C, the LAM before being excised. E, show LAM after excision. D shows RAM before being excised. F shows excised



**Figure-2:** TEE shows RAM in RA during diastole in A and B shows prolapse of the RAM into RV in systole

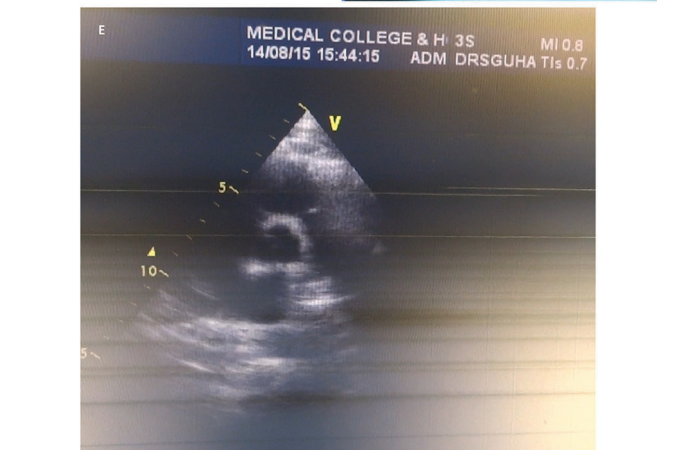
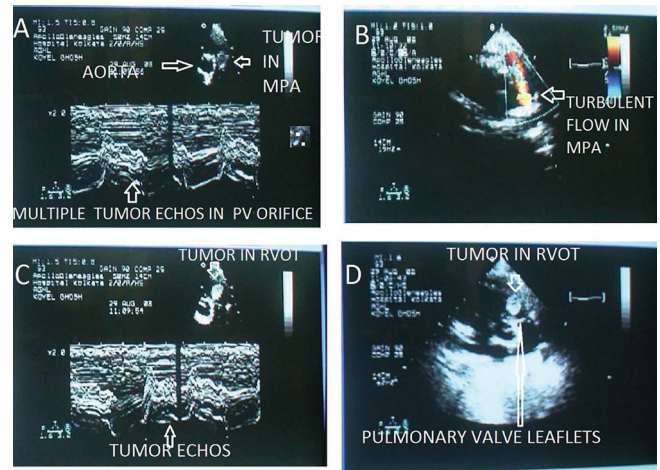
diagnosed as IPT. One adult 60 year old male had extension of RCC through IVC to RA.

Overall operative survival was 88.3%. Operative mortality was 11.7%.

### Specific presentation of some cases

**Left atrial myxomas (LAM) presenting with mitral valve inflow restriction:** 10 female patients, all adults (Sl No. 1,2,3,9,10,12,13,14,15,17), presented with slowly growing myxoma in left atrium. Symptoms included typically gradually increasing shortness of breath and chronic cough for 4 to 6 years, followed by congestive heart failure for 1 year. Most of the patients on admission had dyspnea, NYHA class II to III. There were NYHA class IV disability with orthopnea in 2 patients (Sl.No.9,14). These patients had high pulmonary arterial systolic pressure (PASP) more than 90 mm Hg. and had to be intubated in sitting posture for anesthetic intubation. The raised PASP took 1 month to settle down after operation. One such patient (Sl No. 10) with high PASP and orthopnea presented with acute renal failure on admission and underwent emergency excision of LA myxoma under CPB. Though she came off bypass, she needed hemodialysis for anuria. However she expired due to post operative sepsis.

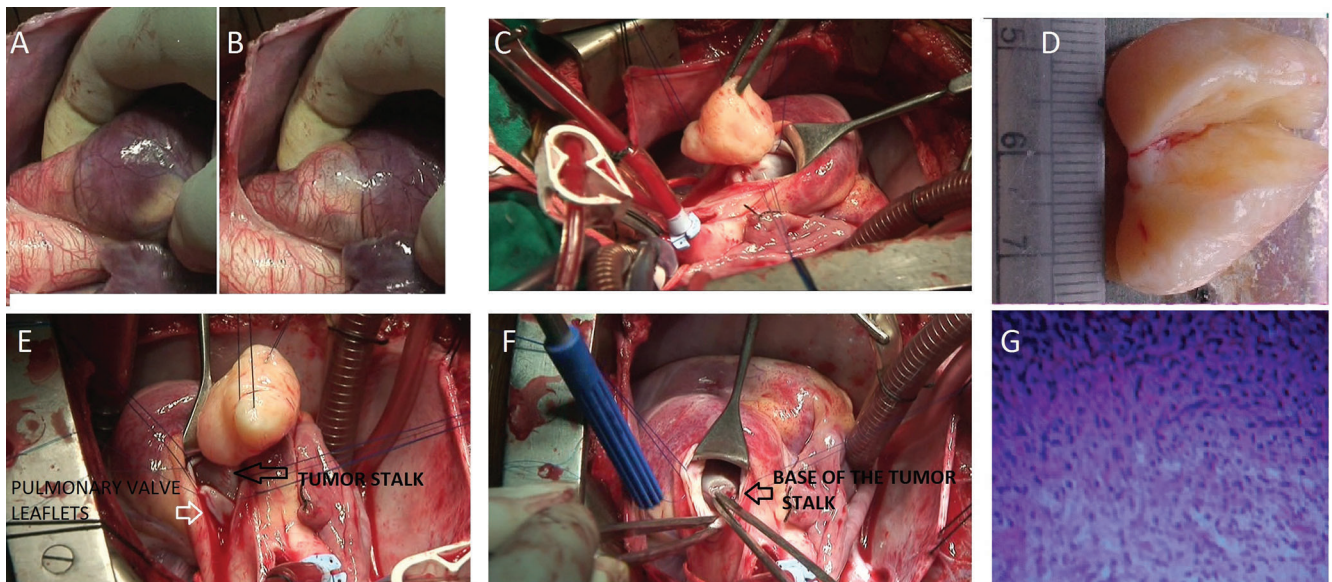
**LAM presenting with distal embolization:** 1 adult female (Sl No. 5) patient, who was asymptomatic without



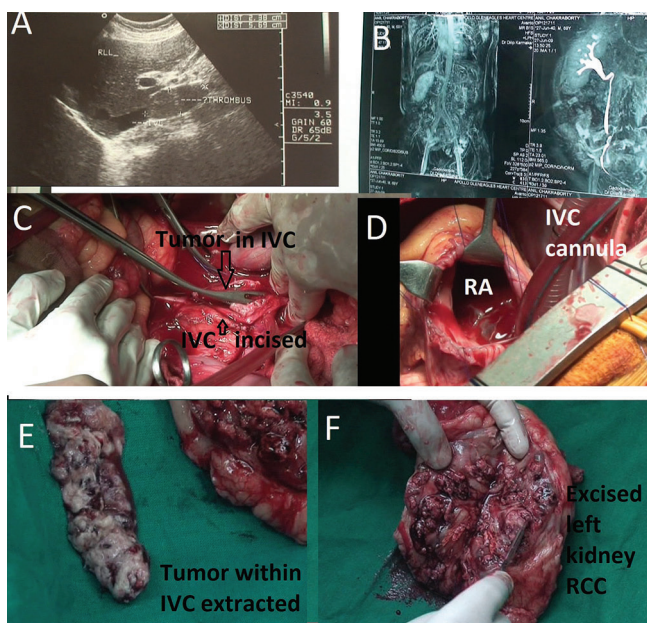
**Figure-3A:** Parasternal short-axis view of the RVOT at the level of the aortic valve, reveals the freely mobile pedunculated tumor mass (A,C and D). A and C shows the M Mode with multiple echoes produced by the tumor. B, turbulent flow into the MPA during systole and D shows the 2D echocardiogram. RVOT-right ventricular outflow tract, PV-pulmonary valve, MPA-main pulmonary artery. E shows echocardiography after 7 years showing RVOT free of any tumor in 2015.

any atrial fibrillation (AF) presented with features of thromboembolism to the left femoral artery. After emergency thromboembolism the specimen was reported on histopathology to be a myxoma. Another elderly 60 year old female (Sl. No. 7) patient had embolic cerebrovascular accident (CVA) on left internal carotid artery territory. Routine echocardiography in both showed presence of pedunculated mass conforming to a diagnosis of LA myxoma which was confirmed histologically after successful excision.

**LV multiple masses:** A 7 year old male (Sl. No. 8) presented with history of malaise and dyspnea. He was asthenic. On echocardiography and also exploration, 4 to 6 small tumor masses in left ventricles were found, some sessile, some pedunculated. The tumors were firm and on incising semisolid materials were found. Though the patient came off bypass, he did not gain consciousness due to undetected thromboembolism after release of aortic cross clamp. The patient expired after a week after prolonged ventilation. Histology revealed the rare diagnosis of inflammatory pseudo tumor (IPT)



**Figure-3B:** Intra operative pictures showing the mass within RVOT in diastole (A) and main pulmonary artery in systole (B). The pedunculated tumor mass with its stalk (C and E). D, white tough tumor mass. F shows the RVOT after clearance, while G shows the photomicrograph of the fibroma containing fibroblasts and connective tissue matrix. (Reproduced with permission from publishers<sup>27</sup>)



**Figure-4:** A, shows the Doppler duplex USG of IVC mass, B shows the CECT showing left sided RCC with right sided functioning kidney. C shows the IVC being emptied of the tumor mass by a ovum holding forceps. D shows the RA incised under Total circulatory arrest and E shows the IVC and RA mass removed on the left and F shows the excised left kidney with RCC mass extracted from IVC.

**RCC extending into RA:** 1 male patient, (SI No. 6), with clinical diagnosis of hypernephroma was referred for involvement of IVC and RA by the suspected tumor cells diagnosed by CECT and USG of abdomen and chest (Figure-4A and B). There were no lung and distant metastases. The abdomen was entered by a roof top incision and thereafter joined by median sternotomy. While the urosurgeons dissected the involved kidneys, IVC with tumor mass was dissected by us and the heart was prepared for required cannulation of the SVC and Aorta for CPB. The

abdominal portion of IVC below the renal veins was used for drainage. Since IVC (with contained tumor mass) snaring was not possible, total circulatory arrest (TCA) at 22 degree centigrade was established. RA was incised and the atrial extension of tumor was excised. RV was found to be free of any tumor. Next, rest of the tumor mass adhered to the IVC was dissected out and removed by incising the great vein (vide Figure-4). RCC was confirmed on histopathological examination. The patient died after living a healthy life for 3 years due to brain metastasis.

Two adult female (SI No. 11,16) patients with RAM had presented with history of gradually increasing leg edema not responding to increasing doses of diuretics. Hepatomegaly was present despite treatment with diuretic. Echocardiography clinched the diagnosis of RAM (Figure-2A and B). One of the patients, (SI 11) had acromegaly, hirsutism which was more consistent clinically with Carney’s syndrome. But there was no endocrine tumor. After excision of RAM under CPB (Figure-1 D and F), both the patients recovered and did not recurrence.

An eight year old female patient (SI No.4) presented with history of gradually increasing chest pain. She was initially treated symptomatically until she had an episode of syncope from which she survived. An echocardiography (Figure-3A) revealed RV fibroma in the RVOT. It was excised under CPB by incision in the main pulmonary artery. HP report revealed it to be a fibroma (Figure-3B).

**Recurrence:** There was one recurrence in one patient (SI. No.3) 2 years after primary LAM removal. Recurrent LAM was excised by redo sternotomy under CPB.

All the patients of LAM including the recurrent LAM, RAM, CF were doing well on follow up. Patient with RCC expired after 3 years of surgery.

**DISCUSSION**

Our study was conducted on patients who presented with

intracavitary tumor mass in the heart. The majority of patients with myxoma were adult females in their late forties and fifties and presented with LAM (70.5%) followed by RAM (29.41%). This finding is agreeable to generally agreed female preponderance and location of cardiac myxomas.<sup>5</sup> Occurrence of myxoma in the ventricles is uncommon; only 1.7% and 0.6% of myxomas occur in the left ventricle and the right ventricle, respectively. The majority (>90%) of myxomas are solitary, although multiple synchronous cardiac myxomas can occur, especially in the setting of Carney complex.<sup>13,14</sup> All our patients with LAM had solitary tumor in LA. There was one case of RA myxoma with acromegaly, but there was no pituitary or other endocrine tumor and no positive family history of any cardiac tumor or sudden cardiac death. There was no recurrence in this RAM. Though the features of acromegaly fits into the description suggestive of Carneys complex, other features were negative and no genetic study was conducted. Cardiac myxomas are the leading cause of mortality in Carneys complex patients who, in addition, often develop growth hormone (GH) excess.<sup>15</sup> There was a single recurrence after LAM tumor excision after 2 years which was excised by redo surgery in our series. But probability of recurrent tumor due to local tissue tumor seeding or incomplete removal can not be ruled out.<sup>16</sup>

While LAM can lead to systemic embolism, being 50% intracranial, causing cerebro vascular accident (CVA), right-sided tumors, RAM, may be a cause of pulmonary hypertension. Instances of diagnosis by histopathological examination of embolus as described above in our case (Sl No.5) has also been described by others.<sup>17</sup> These cases were asymptomatic without any atrial fibrillation, shortness of breath or chest pain. A few months or years later these patients would have been symptomatic.<sup>5,10</sup> We had to wait for 3 months after hemorrhagic cerebral infarction in the other case of TE (Sl. No.7) before exploration under CPB to reduce the risk of per operative CVA during CPB.

Multiple LV small tumor masses in the child (Sl. No.8) which was diagnosed as IPT the main differentiation would be from non cardiac tumors such as thrombi, infective foci, or infestations. But it was found on histopathology after immunohistochemistry as IPT.<sup>18</sup> IPTs are predominantly composed of degenerating fibrin with central nodular calcium deposits, mild to moderate chronic inflammation, and degenerating blood elements and can even present as large mass.<sup>19</sup>

RCC represents 3% to 4% of all cancers, with about 5% to 10% presenting as extension IVC with tumor thrombus.<sup>20,21</sup> Combined excision of renal mass and its extension into IVC and RA as done by us has also been described by others.<sup>22</sup> 5 years survival in RCC even with IVC involvement is 33% while those without IVC extension it is 52%.<sup>6</sup> In our patient the procedure have provided substantial palliation and useful 3 year survival which was quite acceptable.

Cardiac fibromas are benign tumors, grossly resembling uterine leiomyomas, with a whorled appearance on cut section found mostly in pediatric population. Fibromas occur

almost exclusively within the ventricular myocardium and frequently in the ventricular septum. Children with fibromas coming to surgical treatment tend to have large, bulky tumors that are not infiltrating. Management can be tailored on individual cases. Intracavitary pedunculated cardiac tumors should be excised to avoid ventricular inlet or outlet obstruction or embolization. In cases of intramyocardial tumor, watchful expectancy can be advocated in asymptomatic infants and children since they can be CRs which can regress<sup>4</sup> or CFs which can remain static for a long time.<sup>23,24,25</sup> Arrhythmias and cardiac failure can be controlled by conservative management.<sup>25</sup> But, when such conservative measures fail, hemodynamic abnormalities appear<sup>23,25</sup> or there is thromboembolism<sup>26</sup>, optimal resection should be attempted. We had earlier reported this Intracavitary pedunculated cardiac fibroma (Sl.No.4) in an 8 year old child<sup>27</sup> who has been doing well (Figure 3AE showing the RVOT free of tumor 7 years after excision of CF)). Total resection of CF is ideal<sup>23,24</sup> but not always feasible<sup>25</sup> with a 20% post operative survival.<sup>28</sup>

In cases of unresectable cardiac tumor of any age, cardiac transplantation<sup>23,24,28</sup> may be an option. In cases of partial involvement of inaccessible structures like posterior wall of left atrium, autotransplantation may be an option too.<sup>29</sup> Subtotal resection can be done in some cases of large intramyocardial tumor<sup>23</sup> with reconstruction of ventricular wall by bovine pericardium or Dacron patch because restoration of cardiac function is the most important consideration<sup>26</sup> rather than full tumor clearance during such resection. Bidirectional glenn shunt has been reported to have been done as a rescue procedure after resection of massive right ventricular fibroma to wean off from CPB.<sup>30</sup>

## CONCLUSION

Cardiac tumors are quite unusual. The most important clinical patterns of cardiac tumors are congestive heart failure and syncopal attacks due to obstructive pathology involving valve orifice or embolism. Patients, irrespective of their gender and age, who present with atypical chest pain or dyspnea, must be advised an early two dimensional echo cardiography to exclude any unsuspected cardiac pathology, specially tumors. Cardiac tumors, when diagnosed, need early operation. Although prognosis is related to the resectability, it is good in general. Recurrence is uncommon even after incomplete resection. But, to avoid the risk of recurrence, complete excision of the tumor with large resection of the interatrial septum is recommended in cases of atrial myxomas.

## REFERENCES

1. Barnes AR, Beaver DC, Snell AM, Primary sarcoma of the heart, Report of a case with electrocardiographic and pathological studies. *Am. Heart J.* 9: 480-491, 1934
2. Chitwood WR., Jr Clarence crafoord and the first successful resection of a cardiac myxoma. *Ann Thorac Surg.* 1992;54:997-8.
3. Burke A, Virmani R: Tumors of the Heart and Great Vessels. *Atlas of Tumor Pathology.* 3rd Series,

- Fascicle 16 Washington, DC, Armed Forces Institute of Pathology, 1996.
4. Kuon E, Kreplin M, Weiss W, et al: The challenge presented by right atrial myxoma. *Herz* 2004; 29:702.
  5. Chiles C, Woodard PK, Gutierrez FR, Link KM: Metastatic involvement of the heart and pericardium: CT and MRI imaging. *Radiographics* 2001; 21:439.
  6. Ficarra V, Righetti R, D'Amico A, Rubilotta E, Novella G, Malossini G, Mobilio G. Renal vein and vena cava involvement does not affect prognosis in patients with renal cell carcinoma, *Oncology* 2001;61: 10-15
  7. Yadava OP. Cardiac tumours in infancy. *Indian Heart J.* 2012;64:492–6
  8. McAllister HA, Jr, Hall RJ, Cooley DA. Tumors of the heart and pericardium. *Curr Probl Cardiol.* 1999;24:57–116.
  9. Habetheruer, A., Laufer, G., Wiedemann, D., Andreas, M., Ehrlich, M., Rath, C., & Kocher, A. Primary cardiac tumors on the verge of oblivion: a European experience over 15 years. *Journal of cardiothoracic surgery* 2015;10:56.
  10. Bahnson HT, Spencer FC, Andrus EC. Diagnosis and treatment of intracavitary myxomas of the heart. *Ann Surg.* 1957;145:915–25.
  11. Simpson L, Kumar SK, Okuno SH, Schaff HV, Porrata LF, Buckner JC, et al. Malignant primary cardiac tumors: review of a single institution experience. *Cancer.* 2008;112:2440–6.
  12. Yuda S, Nakatani S, Yutani C, Yamagishi M, Kitamura S, Miyatake K. Trends in the clinical and morphological characteristics of cardiac myxoma: 20-year experience of a single tertiary referral center in Japan. *Circ J.* 2002;66:1008–13.
  13. Pinede L, Duhaut P, Loire R: Clinical presentation of left atrial cardiac myxoma. A series of 112 consecutive cases. *Medicine (Baltimore)* 2001; 80:159.
  14. Ipek G, Erentug V, Bozbuga N, et al: Surgical management of cardiac myxoma. *J Card Surg* 2005; 20:300.
  15. Bandettini WP, Karageorgiadis AS, Sinaii N, Rosing DR, Sachdev V, Scherthaner-Reiter MH, Gourgari E, Papadakis GZ, Keil MF, Lyssikatos C, Carney JA, Arai AE, Lodish M, Stratakis CA. Growth hormone and risk for cardiac tumors in Carney complex. *Endocr Relat Cancer.* 2016;23:739-46.
  16. McCarthy PM, Piehler JM, Schaff HV, Pluth JR, Orszulak TA, Vidaillet HJ Jr, et al. The significance of multiple, recurrent, and “complex” cardiac myxomas. *J Thorac Cardiovasc Surg* 1986;91: 389.
  17. Koikkalainen K, Kostiaainen S, Luosto R. Left atrial myxoma revealed by femoral embolectomy. A case report and review of the literature. *Scand J Thorac Cardiovasc Surg* 1977;11:33.
  18. Sunbul M, Cagac O, Birkan Y. A rare case of inflammatory pseudotumor with both involvement of lung and heart. *Thoracic Cardiovasc Surg.* 2013;61:646–8.
  19. Bhagwat K, Hallam J, Shivanand G, Brooks M, Atkinson V, Goldblatt J. Expanding cardiac pseudotumor, *J Thorac Cardiovasc Surg.* 2011; 141:e41-2.
  20. Hevia V, Ciancio G, Gomez V, et al. Surgical technique for the treatment of renal cell carcinoma with inferior vena cava thrombus: Tips, tricks, and oncological results. *Springerplus* 2016;5:132.
  21. Gaudino M, Lau C, Cammertoni F, et al. Surgical treatment of renal cell carcinoma with cavoatrial involvement: A systematic review of the literature. *Ann Thorac Surg* 2016;101:1213–21.
  22. Spelde A., Steinberg T., Patel P.A., Garcia H., Kukafka J.D., MacKay E., Gutsche J.T., Frogel J., Fabbro M., Raiten J.M., Augoustides J.G.T. Successful Team-Based Management of Renal Cell Carcinoma With Caval Extension of Tumor Thrombus Above the Diaphragm *Journal of Cardiothoracic and Vascular Anesthesia, Volume 31, 2017*
  23. Uzun O, Wilson DG, Vujanic GM, Parsons JM, Giovanni JV. Cardiac tumors in children. *Orphanet J Rare Dis.* 2007;2:11.
  24. Kohut J, Krzystolik-Ladzińska J, Szydłowski L, Smoleńska-Petelenz J, Giec-Fuglewicz G, Pajak J. The diagnosis, clinical course and follow-up of children with cardiac tumours—a single centre experience. *Kardiologia Pol.* 2010;68:304–9.
  25. Varlamis GS, Chalemis Z, Haritandi A, Gerakaris L, Fotiades N, Vassilicos V. Primary intramural fibroma of the left ventricle with a late apparent symptomatology. *Hellenic J Cardiol.* 2005;46: 362–5.
  26. Darwazah AK, Shoeb J, Eissa SS. Pedunculated endocardial left ventricular fibroma presenting with cerebral and bilateral peripheral embolization. *Ann Thorac Surg.* 2010;89:965–7.
  27. Dasbaksi, K., Hossain, M.Z., Haldar, S. et al. *Indian J Thorac Cardiovasc Surg* 2017;33: 261.
  28. Srivyas RC, Xavier J, Devanand NS, Gowda N. A case of cardiac fibroma obstructing the right ventricular outflow tract. *Indian J Thorac Cardiovasc Surg.* 2002;18:167–9.
  29. Cooley DA, Reardon MJ, Frazier OH, Angelini P. Human cardiac explantation and autotransplantation: application in a patient with a large cardiac pheochromocytoma. *Tex Heart Inst J,* 1985;12:171-6.
  30. Dasbaksi K, Mukherjee K, Saha E, Mukherjee P. Salvaging an accidental superior vena caval transection during a right pneumonectomy by creating a Glenn shunt: a case report and review of the literature. *J Thorac Cardiovasc Surg.* 2014;148:147–9.

**Source of Support:** Nil; **Conflict of Interest:** None

**Submitted:** 01-01-2020; **Accepted:** 29-01-2020; **Published:** 17-02-2020