

Association of Squamous Cell Carcinoma with Nonfunctioning Kidney due to Renal Stone Disease

Yogesh Torkadi¹, Rahul Devraj², Ramchandriah³, Raghuv⁴, Charan Kumar⁵, Ram Reddy CH⁶

ABSTRACT

Introduction: Squamous cell carcinoma accounts for 0.5-0.8% of all renal tumour. Squamous cell carcinoma (SCC) of the renal pelvis is a rare neoplasm and is usually associated with long standing renal stone disease. There is lack of definite clinical presentation and inconclusive imaging finding, these tumors are high grade, highly aggressive with poor prognosis. Histopathology report is hallmark for diagnosis.

Material and methods: Our study is Retrospective study with sample size of 5 patient (3 male and 2 female), presenting complaints of all patients had a chronic history of renal stone disease with loin pain presented during last 2 year of period in Urology department. All patient were evaluated with routine preoperative blood investigation, DTPA renogram, and NCCT (KUB), found to have nonfunctioning kidney underwent simple nephrectomy.

Result: In our study mean age is 52 year, 3 male and 2 female, mean operative time- 2hr,during postoperative period 3 patient have uneventful postoperative course,1 patient have atrial fibrillation,1 patient have a suture site infection, average hospital stay 4.5 days. Postoperative histopathology report confirmed presence of squamous cell carcinoma, 3 patient on regular follow up with no evidence of recurrence, 1 patient dies during follow up and 1 patient lost follow up.

Conclusion: Primary squamous cell carcinoma of kidney are rare aggressive tumour with poor prognosis. As this tumor is associated with renal stone and non functioning kidney, they should be evaluated with newer imaging technology for early detection of tumour.

Keywords: Nonfunctioning Kidney,Squamous Cell Carcinoma, Renal Stone, Simple Nephrectomy.

INTRODUCTION

Primary carcinoma of renal pelvis account for 4-5% of all urothelial tumour. Among this squamous cell carcinoma accounts for 0.5-0.8% of all renal tumour. Squamous cell carcinoma (SCC) of the renal pelvis is a rare neoplasm and is usually associated with long standing renal stone disease.^{1,2} The lack of definite clinical presentation and inconclusive imaging features result in advanced stage of presentation. Solid mass, hydronephrosis, and calcification are common but nonspecific radiological finding that explain why this tumor is not diagnosed before histopathological examination of resected surgical specimen.^{3,4} These tumors are high grade, highly aggressive with poor prognosis. Histopathology report is hallmark for diagnosis. Aim of our study was to prove association of squamous cell carcinoma with nonfunctioning kidney due to stone disease and other risk factors.^{4,5} It is must to get histopathological examination

in nephrectomy specimen and have high suspicion in such cases during preoperative evaluation. Here we present five cases of squamous cell carcinoma of kidney, due to its rarity and also to highlights the silent presentations of these tumors and the need to keep in mind the association of this tumor in patients having nephrolithiasis. This report highlights the rarity and aggressiveness of squamous cell carcinoma.

MATERIAL AND METHODS

We report here five cases of incidentally diagnosed primary renal squamous cell carcinoma, treated at our hospital over a span of 2 year. Interestingly, renal carcinoma was unsuspected clinically in all patients. All underwent nephrectomy for nonfunctioning kidney. Some of retrospectively observed features studied here. Our study was a retrospective study with sample size of 5 patients. Among 5 patients, 3 were male and 2 were female. Among 5 patients 3 were more than 50 years old. In Symptomatology 4 patient had loin pain, 1 patient had loin pain with hematuria. Average duration of symptoms was 8 months. In Imaging finding 2 patients had a single calculi (case 1 -Staghorn calculi with right renal hydronephrosis, case 2- Single calculi with small size kidney) and 3 patient had multiple calculi, (case 3 - Multiple calculi with hydronephrosis, case 4- Multiple Calculi with pyelonephritic changes, case 5- Multiple calculi with hydronephrosis) (table-1,2,3,4) (fig-1,2).

All preoperative routine investigation were within normal range. Serum creatinine of all patient was within normal range. DTPA Renogram finding of all patients suggestive of nonfunctioning kidney. Among 5 patient 3 patient had prior history of tobacco addiction and urinary tract infection. Other relevant finding presented in following table format. In our study population 3 patient underwent right simple nephrectomy and 2 underwent left simple nephrectomy and in postoperative follow up period histopathology report found to have squamous cell carcinoma which was associated

¹Resident, ²Professor, ³Associate Professor, ⁴Assistant Professor, ⁵Assistant Professor, ⁶HOD, Department of Urology, Nizam Institute of Medical Sciences, Hyderabad, Telangana, India

Corresponding author: Dr Rahul Devraj, Professor, Department of Urology, Nizam Institute of Medical Sciences, Hyderabad, Telangana, India

How to cite this article: Yogesh Torkadi, Rahul Devraj, Ramchandriah, Raghuv⁴, Charan Kumar, Ram Reddy CH. Association of squamous cell carcinoma with nonfunctioning kidney due to renal stone disease. International Journal of Contemporary Medical Research 2020;7(1):A6-A9.

DOI: <http://dx.doi.org/10.21276/ijcmr.2020.7.1.44>



finding in our study that we retrospectively analysed.

RESULT

Mean age of our sample size population 52 years, mean operative time- 2hr, during postoperative period 3 patient have uneventful postoperative course. 1 patient had atrial

Age group	No. of patients
30-40years	01
40-50years	01
50-60years	02
>60years	01
Total no.of patients	05

Table-1: Age Distribution

Presentation	No of patients
loin pain + hematuria	01
loin pain	04
Total patients	05

Table-2: Presentations

Imaging finding	No of patients
Single calculus with pyelonephritis	01
Single calculus with small kidney	01
Multiple calculi with hydronephrotic kidney	03

Table-3: Imaging finding

Case no.	1	2	3	4	5
Gross finding	Growth in pelvis 1.5 x 1cm	No visible growth	No visible growth	No visible growth	Growth in pelvis 2 x 1 cm
Grading	pT3NxMx	pT1NxMx	pT3N1Mx	pT3N2Mx	pTaNxMx

Table-4: Gross finding and grading in our study

Name of Authors	No of patients
Shah et al	02
Yeh et al	02
Li MK, Cheung WL	11
Hassan M1, Qureshi A	02
Mathur et al	01
Verma et al	01
Our study	05

Table-5: Various study showing association squamous cell carcinoma with nonfunctioning kidney with stone disease^{1,3,5,6}

Our study	M	39	Right flank pain	Staghorn calculi with right renal hydronephrosis	Nephrectomy	NR
	M	60	Left Flank Pain	Single calculi with small size kidney	Nephrectomy	NR
	F	59	Left flank pain	Multiple calculi with hydronephrosis	Nephrectomy + Adj chemoRx	NR
	M	68	Right flank pain	Multiple Calculi with pyelonephritic changes	Nephrectomy	Died in f/u
	F	40	Right flank pain and hematuria	Multiple calculi with hydronephrois	Nephrectomy	Lost in f/u

Summary of our cases

fibrillation, 1 patient had a suture site infection, average hospital stay in our study was 4.5 days. Postoperative histopathology report confirmed presence of squamous cell carcinoma, 3 patient on regular follow up with no evidence of recurrence, 1 patient lost follow up and 1 patient died during follow up. Gross histopathological findings of our cases are shown in table-4, fig-3.

Histopathological findings

TNM staging of renal pelvic carcinoma(AJCC 8 edition)

Primary tumor (pT)

- **pTX:** cannot be assessed
- **pT0:** no evidence of primary tumor
- **pTa:** noninvasive papillary carcinoma
- **pTis:** carcinoma in situ
- **pT1:** invades subepithelial connective tissue
- **pT2:** invades muscle
- **pT3:** invades peripelvic fat or renal parenchyma
- **pT4:** invades adjacent organs or perinephric fat

Regional lymph nodes (pN)

- **pNX:** cannot be assessed
- **pN0:** no regional lymph node metastasis
- **pN1:** 1 lymph node with tumor deposit \leq 2 cm
- **pN2:** 1 lymph node with tumor deposit $>$ 2 cm or metastases in multiple nodes

Notes: Regional lymph nodes include hilar, paracaval, aortic and retroperitoneal

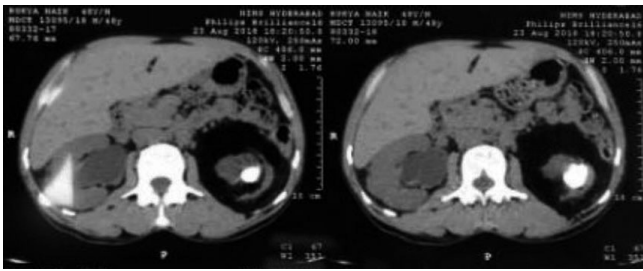


Figure-1: CT scan suggestive of left renal calculi with pyelonephritic changes.

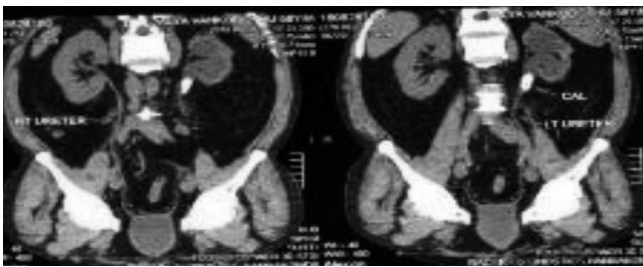

Figure-2: CT scan suggestive of left p. calculi with gross hydronephrosis

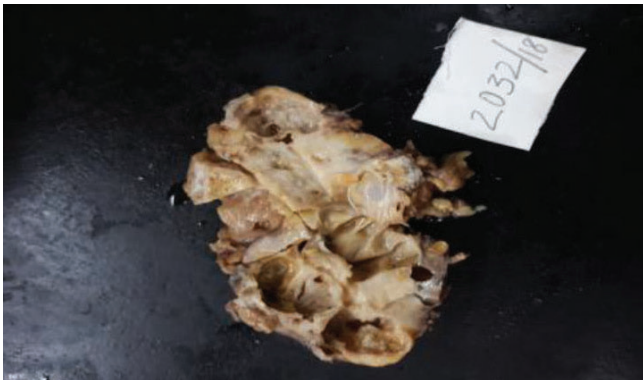

Figure-3: Gross specimen showing growth in pelvis.

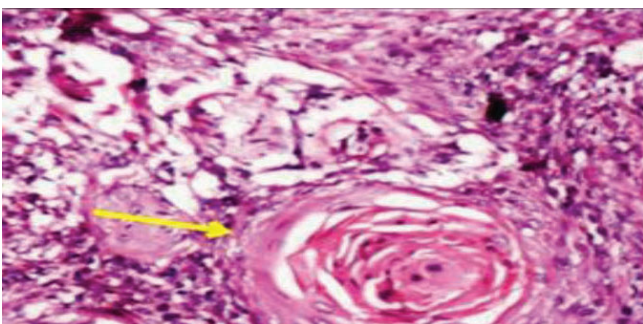


Figure-4: HPE showing pearl formation.

Distant metastasis (pM)

pM1: distant metastasis

Microscopic finding

In our study the Microscopic finding in all specimen s/o following characteristic features Extensive Squamous differentiation, Pearl formation, Intercellular bridge s and keratotic cellular pattern seen (fig-4).

DISCUSSION

Squamous cell carcinoma of urinary tract more frequently

in urinary bladder and urethra. In kidney incidence of transitional cell carcinoma > squamous cell carcinoma > Adenocarcinoma.^{6,7,8} Common etiological factors are renal stone, infection, vit A deficiency schistosomiasis, smoking, irritation and infection leads to metaplasia precursor for malignant change. Hypercalcemia, leukemia and thrombocytosis reported as Paraneoplastic syndrome in squamous cell carcinoma. The fact that the urothelium normally does not have squamous cells renders the pathogenesis of these tumors interesting. The process is assumed to begin with an urothelial metaplasia resulting from a reaction to chronic irritation, leading to dedifferentiation, dysplasias, and in the end, to a squamous cell carcinoma. Radiologically, primary squamous cell carcinoma (SCC) of the renal pelvis may appear as a solid mass, with hydronephrosis, calcifications, or as a renal pelvic infiltrative lesion without evidence of a distinct mass. The radiologic differential diagnosis includes primary and secondary renal neoplasms and xanthogranulomatous pyelonephritis (XGP) associated with renal calculi. XGP is an uncommon form of chronic pyelonephritis, typically occurring as a result of chronic obstruction, which leads hydronephrosis, causing destruction of renal parenchyma. XGP is commonly associated with lithiasis however, rarely causes keratinizing squamous metaplasia and its manifestations closely mimic renal neoplasm, leading to misdiagnosis of malignancy. The radiologic findings of SCC are variable and may present with diffuse enlarged non-functional kidney with renal calculi, perirenal infiltration, and low density or echogenity in the renal parenchyma. The primary renal SCC cannot be distinguished from XGP or other malignant neoplasms of the kidney. A large transitional cell cancer with both renal pelvis and parenchymal involvement may present with similar CT and MR imaging findings. MR imaging features of renal SCC have been rarely described in literature. Recently, Imbriaco et al., reported renal SCC within a horseshoe kidney associated with renal stones with non-specific CT and MRI findings. The non-specific clinical and radiologic features in renal SCC may cause diagnostic confusion and histopathology is needed for confirmation. Histopathological examination is hallmark for diagnosis as lack of characteristic on clinical and imaging feature.^{9,10} Renal SCC usually presents at an advanced stage-pT3 or higher. Because of advanced stage at presentation, the prognosis is generally poor, as surgical resection is rarely curative and adjuvant chemoradiotherapy is usually ineffective. Surgery is the standard of care even in the faces of metastasis to establish a histological diagnosis, to control symptoms or to eliminate the source of infection. Cisplatinium based chemotherapy and radiotherapy are usually given in advanced cases but failed to show any survival benefit. However, because of less number of cases no fixed treatment guideline is present. The prognosis is dismal with a 5-year survival rate of less than 10%. Mean age was 56 years with male to female equal prevalence, our study have mean age 52 year with slightly more prevalence in male. Most of squamous cell carcinoma are moderately to poorly differentiated with more deep invasion.

As per other study finding our study also suggestive of high pathological grade and advanced stage. Lee et al¹¹ study found out squamous cell carcinoma with central component have more intraluminal component with lymph node mets and it have a worst prognosis, with peripheral component have prominent parenchymal thickening invading perirenal fat tissue before lymph node and distant mets.¹¹ Radical nephrectomy considered as primary treatment it also helps to control symptoms and eliminate source of infection in some cases.^{12,13} Raghavendran et al reported a case series of stones associated renal pelvic malignancies and they suggested that a patient with long standing stone disease and associated poor functional kidney or hematuria necessitates a screening CT.¹⁴ Lee et al.¹¹ found that the most helpful features in CT of renal SCC was presence of enhancing extra-luminal and exophytic mass and in some cases, with an intraluminal component. They further suggested that as it is impractical to perform CT for every patient with renal stone, instead of CT, intravenous urography (IVU) should be carried out periodically, especially, in patients with long standing stones, and should be read as a split function test for all portions of renal parenchyma. Because the filling defects, delay in appearance of pyelogram, or renal parenchymal thickening in IVU may indicate a renal tumor despite the absence of mass effect and preservation of renal contour, warranting further studies. Based on available studies (table-5), it is suggested that every patient with long standing renal stone disease should undergo ultrasound and IVU, depending upon finding such as filling defect, delayed excretion of contrast and parenchymal thickening needs additional imaging study needs such as CT urogram or USG guided FNAC if any suspicious soft tissue lesion noted.³

CONCLUSION

Primary squamous cell carcinoma of kidney are rare aggressive tumour with poor prognosis. This tumour associated with long standing renal stone with Non functioning kidney. As most of this patient diagnosed retrospectively after histopathological examination so patient with renal stone disease should be intervened even if they are nonobstructive and having long duration association. If renal stone associated with nonfunctioning kidney should be investigated with additional imaging investigation. CT and MRI can play a crucial role in diagnosis and staging of these tumors. Biopsy from the renal pelvis or calyceal wall should be considered during the treatment of stone disease in patients having long standing renal calculi as this patient are prone to harbor occult malignancies.

REFERENCES

1. Li MK, Cheung WL. Squamous cell carcinoma of the renal pelvis. *Journal of Urology*. 1987;138:269–271.
2. Kalayci OT, Bozdag Z, Sonmezgoz F, et al. Squamous cell carcinoma of the renal pelvis associated with kidney stones: radiologic imaging features with gross and histopathological correlation. *J Clin Imaging Sci* 2013;3:14.
3. Verma N, Yadav G, Dhawan N, Kumar A. Squamous

cell carcinoma of kidney co-existing with renal calculi: a rare tumour. *BMJ Case Rep*. 2011;2:34-39.

4. Ayushi Jain, Deepti Mittal, Arpita Jindal, Ranjana Solanki, Suman Khatri, Archana Parikh, Kamlesh Yadav. Incidentally Detected Squamous Cell Carcinoma of Renal Pelvis in Patients with Staghorn Calculi: Case Series with Review of the Literature. *ISRN Oncol*. 2011; 2011: 620574.
5. Hassan M, Qureshi. Incidental squamous cell carcinoma of the renal pelvis in a non functioning kidney that was missed on two non-contrast CT-scans. *J Ayub Med Coll Abbottabad*. 2017;29:489-492.
6. Mathur S, Rana P, Singh S, Goyal V, Sangwan M. Incidentally detected squamous cell carcinoma in non-functioning kidney presenting as multi-cystic mass. *J Surg Case Rep*. 2011;9:8.
7. P Kaur, AChauhan, G Singh, S Kataria, R Kalra. Primary Squamous Cell Carcinoma Of Kidney - A Case Report And Review Of Literature. *The Internet Journal of Nephrology*. 2009; 6:7-10.
8. Jain A, Mittal D, Jindal A, Solanki R, Khatri S, Parikh A et al. Incidentally Detected Squamous Cell Carcinoma of Renal Pelvis in Patients with Staghorn Calculi: Case Series with Review of the Literature *ISRN Oncol*. 2011; 2011: 620574.
9. Tyagi N, Sharma S, Tyagi SP, Maheshwari V, Nath P, Asharf SM, et al. A histomorphologic and ultrastructural study of the malignant tumors of the renal pelvis. *J Postgrad Med* 1993;39:197-201
10. Reuter VE. The urothelial tract: Renal pelvis, ureter, urinary bladder and urethra. In: Mills SE, Carter D, Greenson JK, Oberman HA, Reuter V, Stoler MH, Sternberg's *Diagnostic Surgical Pathology*, Philadelphia Lippincott Williams and Wilkins; 2004; 4th edition: p. 2058-9.
11. Lee TY, Ko JF, Wan YL, Wan YL, Cheng YF, Yang BY et al. Renal squamous cell carcinoma: CT findings and clinical significance. *Abdom Imaging* 1998;23:203-8.
12. Blacher EJ, Johnson DE, Abdul-Karim FW, Ayala AG Squamous cell carcinoma of renal pelvis. *Urology*. 1985; 25: 124-26.
13. Rosai J. *Urinary tract, surgical pathology* MOSBY, st. louis USA 2004; 9th ed. Vol 1, PP-1274.
14. Raghavendran M, Rastogi A, Dubey D, Chaudhary H, Kumar A, Srivastava A, et al. Stones associated renal pelvic malignancies. *Indian J Cancer*. 2003;40:108–12.

Source of Support: Nil; **Conflict of Interest:** None

Submitted: 06-12-2019; **Accepted:** 01-01-2020; **Published:** 30-01-2020