

Rehabilitation of an Orbital Defect with Silicone Orbital Prosthesis: A Case Report

Ronauk Singh¹, Parag Dua², Poonam Prakash³, S K Bhandari⁴

ABSTRACT

Introduction: Loss of eye, apart from impaired vision has a detrimental effect on psychosocial wellbeing of an individual. The replacement of the lost eye as soon as possible after the surgery is necessary to improve social acceptance and quality of life. Multidisciplinary management and team approach between surgeon and prosthodontist are essential in providing accurate and effective rehabilitation and follow-up care for the patient.

Case report: This case report describes a simplified method for the fabrication of a custom silicone orbital prosthesis retained with spectacles for rehabilitation of a residual defect post exenteration of left eye. It highlights the importance of indepth analysis & comparison of the defect with the normal contralateral eye which was used as an anatomical guide for fabrication of an aesthetic prosthesis.

Conclusion: Advanced digital technology like rapid prototyping and CAD/CAM have made fabrication of complex prosthesis like orbital prosthesis simpler and quicker. However, these contemporary methods are technique sensitive, equipment dependent and may not be available easily. Thus, a maxillofacial prosthodontist should be able to read the available anatomical guides and use them to fabricate an aesthetically acceptable prosthesis using conventional technique to rehabilitate patients and improving quality of life as soon as possible.

Keywords: Custom Silicone Orbital Prosthesis, Orbital Exenteration, Anatomic Guide.

INTRODUCTION

Maxillofacial defects compromise appearance and function making individual incapable of leading a relatively normal life. An acceptable replacement of anatomical parts is a challenge faced by maxillofacial prosthodontists.

Loss of an eye may be caused due to congenital defect or acquired reasons resulting from tumours, midfacial trauma or orbital radiation necrosis. The disfigurement associated with the loss of an eye can cause significant functional, physical and emotional problems thus affecting psychosocial well being of an individual. Objective of rehabilitation of orbital defect should aim at improving the total quality of life. This article describes a customized fabrication of a silicone orbital prosthesis highlighting the significance of various anatomical measurements as a guide to deliver aesthetically acceptable prosthesis.

CASE REPORT

A 41-year-old male patient reported to the Division of Prosthodontics with a chief complaint of compromised

appearance due to loose and worn out left artificial eye. The patient gave a history of loss of the eye post splinter injury during road traffic accident 3years ago. Multiple surgeries were carried out along with exenteration of left eye subsequent to the accident. He was rehabilitated with a silicone orbital prosthesis in 2017 which over time had worn out and presented with marginal tear, discoloured silicone portion and was ill fitting (Fig 1).

On examination of the defect, the left globe and eye lids were found to be missing. A saucer shaped defect in relation to left eye measuring 4 cm mediolaterally and 3 cm superoinferiorly with an insufficient negative volume having greatest depth portion of 8mm/0.8cm was observed (Fig 2). Patient's neuromotor and neurosensory function with relation to the defect area were found to be within normal limits as was checked by making him do various exercises like lifting eyebrows, forceful closure of eye, blinking action etc. This also showed possible mobility of tissue bed during normal facial movements. On palpation of the defect, implants (plate and screw) were felt in superolateral and inferomedial region of left orbital rim.

Thus, the greatest challenge faced while rehabilitation in this case was to deliver an aesthetic prosthesis with perfect blend of margins with good retention inspite of limited negative volume and a mobile tissue bed.

On ophthalmologic evaluation, normal vision of right eye was ascertained. Position of globe of right eye was measured to be 8 mm in front of lateral orbital rim and 9 mm deep to supraorbital rim. An engineer's grid scale, customised, so that it could be placed on patient's nasal bridge was used for grid wise measurement of normal eye (Fig 3).

Based on the history and clinical examination, a diagnosis of residual defect due to left orbital exenteration was arrived at. The treatment plan involved fabrication of a customized silicone orbital prosthesis using stock shell and retained using spectacle as mechanical aid. The treatment plan was discussed in detail with the patient and an informed written

¹Graded Specialist Prosthodontics, INHS Sanjivani, ²Associate Professor, Department of Dental Surgery, AFMC Pune, ³Reader & Instructor, Department of Dental Surgery, AFMC Pune, ⁴Professor & HOD, Department of Dental Surgery, AFMC, Pune, India

Corresponding author: Col Parag Dua, Associate Professor, Department of Dental Surgery, AFMC Pune, India

How to cite this article: Ronauk Singh, Parag Dua, Poonam Prakash, S K Bhandari. Rehabilitation of an orbital defect with silicone orbital prosthesis: a case report. International Journal of Contemporary Medical Research 2019;6(11):K16-K19.

DOI: <http://dx.doi.org/10.21276/ijcmr.2019.6.11.30>

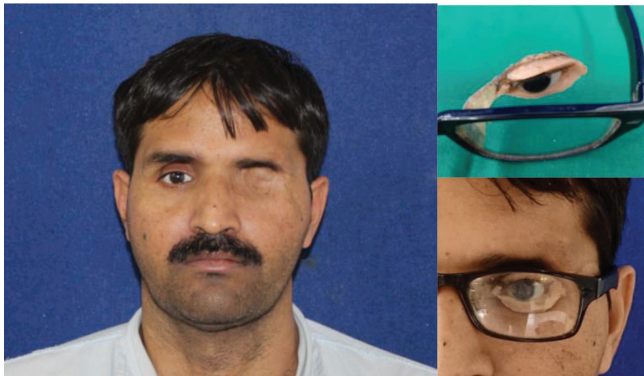

Figure-1: Pre-treatment with old prosthesis

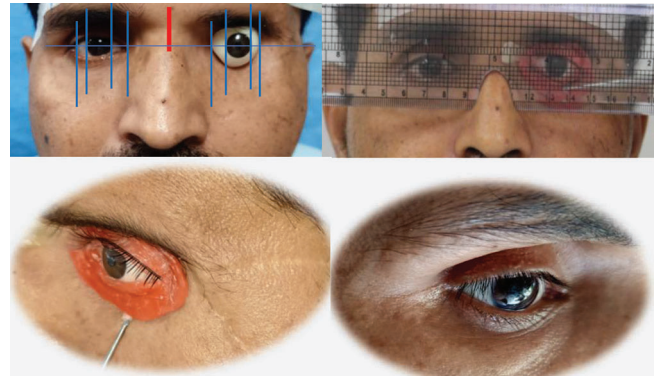


Figure-5: Stock Shell Selection and Wax trial

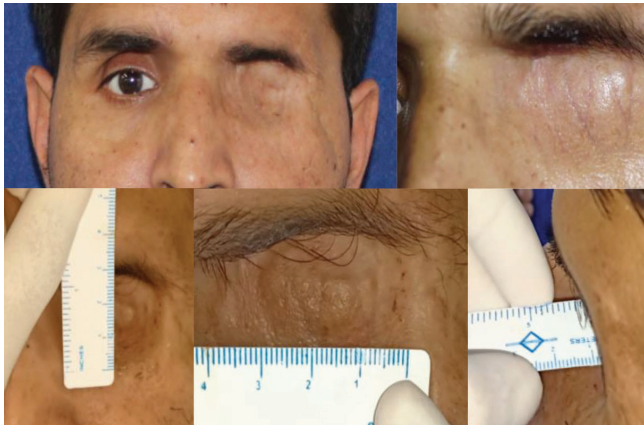

Figure-2: Examination of the defect




Figure-6: Orbital prosthesis in situ

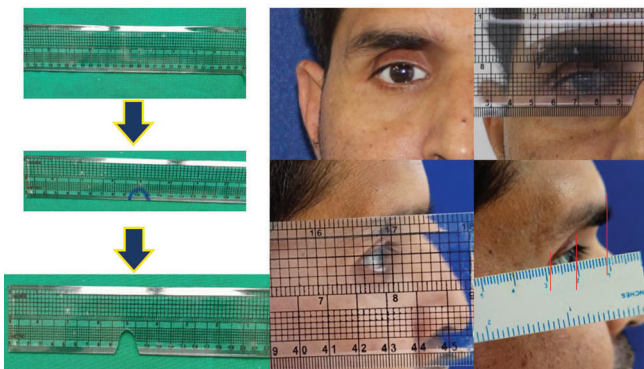


Figure-3: Customization of Grid scale and Measurement of the normal eye



Figure-7: Orbital prosthesis retained with spectacles



Figure-8: Pre-treatment & Post-treatment comparison

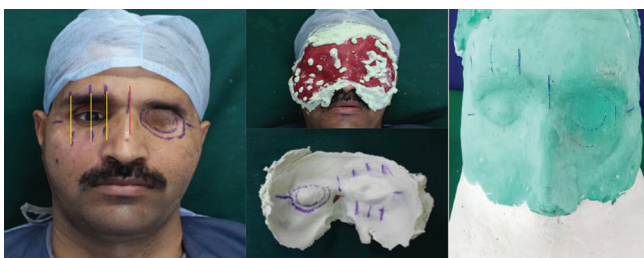

Figure-4: Moulage Impression

consent was taken.

Fabrication Process

Facial markings were made prior to impression making. Facial landmarks such as facial midline, inner canthus, middle of iris, outer canthus and horizontal plane of centre

of eye were utilized for facial markings. A facial impression-moulage was prepared from irreversible hydrocolloid (Tropicalgin; Zhermach Inc. products, California) along with reinforcement by Impression compound (Pyrax, Roorkee UK) (Fig 4). Subsequently, a cast was poured in the dental stone (Gem Stone, Shruti Products, India) and working model with transferred facial marking was thus achieved. Markings on the working model as well as facial markings aided in fabrication of prosthesis in harmony and symmetry with the contralateral normal eye. Stock eye of appropriate size, shape, iris shade and scleral colours, matching that of the normal right eye, was selected. The stock ocular prosthesis was placed on the cast as well as on patient and its size & shape was ascertained comparing it to the markings. The periphery of stock shell was arbitrarily trimmed to match the

socket border extensions on the cast. (Fig 5)

Acrylic sub-structure which formed future base for silicone ocular prosthesis as well as functioned as connector, connecting the final prosthesis to spectacles was fabricated using heat cure acrylic. Stock shell was positioned on acrylic substructure using modelling wax, to simulate the position of the right eye, with the patient focusing on the distant point directly ahead. An engineer's grid scale was used for verification of the mediolateral placement of stock shell as compared to right eye (fig 5). The pupils were used as reference points for evaluation. Accurate mediolateral, anteroposterior and superoinferior positioning of the prosthesis was done to exactly mimic the position of the normal contralateral eye.

The periorbital tissues were then sculpted using modelling wax as sculpting material. The lid contours and periorbital tissues were mimicked to those of the right eye as precisely as possible using the anatomic measurements as noted earlier. The lines of the juncture were feathered, and limited so that they do not extend beyond the area covered by the eyeglass frame. This aided in camouflaging the prosthesis margins. The wax pattern was tried on model as well as on patient to confirm the orientation (Fig 5). Final trial in of the wax pattern was done with the spectacle (not attached) to check whether the borders were not extending beyond the frame. Once acceptable aesthetic symmetry and extensions were achieved, mould was fabricated following investing of the wax pattern and dewaxing was done.

Silicone being a translucent and colourless material, appropriate shade was obtained by mixing different intrinsic shades to the silicone material (Technovent Ltd, South Wales, UK). Shade matching was done in natural daylight, the best time for which was between 11 am and 1 pm. Once most appropriate shade was selected silicone was packed using layering technique and was left for 24 hrs to bench cure. Cured/ vulcanized silicone prosthesis was retrieved, trimmed and finished. It was further custom characterized using extrinsic staining according to the needs of the patient – to obtain a perfect aesthetic match with the facial skin contours, colour and appearance of the contralateral eye. Artificial eyelashes were attached to the upper lid and lower lid with utmost care.

The final prosthesis was tried on the patient and checked for aesthetics, colour matching and blending with facial contour from various views including frontal, profile, worm eye and bird eye view (Fig 6). Once both patient and clinician were satisfied spectacles which were planned of mechanical retention, were attached to the prosthesis by means of acrylic substructure using acrylic resin (DPI-RR Cold Cure, Mumbai, India) and checked (Fig 7&8).

DISCUSSION

There are three surgical procedures which are generally used; one is 'evisceration', which consists of the removal of the contents of the globe, leaving the sclera and on occasions the cornea in place; second is 'enucleation' where the eyeball is completely removed and finally 'exenteration' is removal of

all the content of the eye socket, including the globe, eyelids, conjunctiva and entire orbital content including periorbital. Depending on the type of surgery and the defect thus produced, eye prostheses are of two types, orbital prosthesis which artificially restores the eye, eyelids and adjacent hard and soft tissues and ocular prosthesis which replaces an eye globe.^{1,2}

The rehabilitation of the orbital defect is a complex task and if reconstruction by plastic surgery is not possible or not desired by the patient, orbital prosthesis offers an attractive and viable option. An orbital prosthesis should be aesthetic, durable, light weight, economical, and most importantly retentive.³ Choice of material and retentive aid depend upon patient's esthetic demands, size and type of defect. Whenever possible surgery should be prosthetically driven.⁴ This helps in achieving positive prosthetic features like creating undercuts behind supra or Infra-orbital rim, skin grafts to be placed giving sufficient negative volume and building up of bone adequately to receive endosseous implants.³

Most commonly used materials for fabrication of facial prosthesis are RTV silicone elastomers. They are preferred, as they provide better marginal adaptation, more life-like appearance and most important is ease of fabrication.⁵

The need for an artificial eye can many a times be satisfied by stock ocular prosthesis that are available in standard sizes, shapes and colours. These are relatively less technique & equipment sensitive and can be delivered quickly. Often, however, a custom-made ocular prosthesis is indicated. Advantages include improved adaptation to the underlying tissues, increased mobility of the prosthesis, improved facial contours and enhanced esthetics gained from the control over the size of the iris and pupil and color of the iris and sclera. Nevertheless, a custom-made prosthesis is more expensive than a stock prosthesis and several steps are required for its fabrication.^{1,6} In orbital prosthesis, artificial eye is a part of silicone prosthesis while in ocular prosthesis it needs to be customized according to tissue bed and available space. Thus, a stock shell fulfilling the requirement of shade and size if available may be a more acceptable option.

Accurate alignment of the artificial eye is one of the major prerequisites as well as a challenge for aesthetic success of the orbital prosthesis.^{7,8} Facial measurements and various devices such as engineer grid scale have been proposed for orienting the ocular portion of the orbital prosthesis. Facial measurements compared to just visual estimation provides a more accurate numbers which acts as a guide to mimic size shape and symmetry of contralateral eye.

The retention of the orbital prosthesis can be achieved using adhesives, attachments to eyeglasses or using osseointegrated implants and magnets.^{2,3} Eyeglasses are the mechanical retentive aid most chosen for orbital prosthesis as they help in camouflaging the defect and is a simple and non-invasive substitute vis-à-vis orbital implants. Magnets are mostly used as a superstructure attachment for implants or as a connector for two piece orbital prosthesis in complex defects involving intraoral extension. The use of osseointegrated implants may offer improved retention compared to the existing alternatives

however various factors, including systemic conditions and financial constraints, limit the use of osseointegrated implants in many patients. Also, controversy regarding the placement of implants in the orbit has been documented. Studies show a higher failure rate because of higher chances of soft tissue infections, decreased vascular perfusion, poor remodelling capacity of bone-implant surface and lack of stabilizing bone volume in proximity to the frontal sinus. Implants placement in present case required multiple surgeries which included bone remodelling and reconstructive plate removal. Implants were not placed as patient was unwilling to undergo any additional surgeries.^{9,10,11}

Recent advances in rehabilitation using orbital prosthesis includes introduction of two new dimensions. One is blinking eye, where EMG patterns from orbicularis oculi of normal eye is used in replicating eye lid blinking action in orbital prosthesis using 8 probe EMG receptors and mini-motors.¹² Other dimension is adding vision through the prosthesis by using Bionic eye which utilizes nano technology using nano cameras, encoders and transducers which relay signal to retinal tract and visual cortex thus producing vision. Current prototypes produce vision which is black & white and hazy. Advanced researches are underway to have a bionic eye with coloured and accurate vision.¹³

CONCLUSION

Goal and objective of maxillofacial prosthetics as quoted by Tweed is “When replacing a missing body part, we must strive for maximum harmony and balance as near to normal as conditions will allow.”

Proper diagnosis and reading the receptor site anatomy through various impressions techniques and measurements is the basis for any successful prosthetic rehabilitation. In present case, various measurements of defect as well as normal side anatomy were used as reference in each step, including stock shell selection, wax pattern fabrication and final prosthesis trial. This helped in overcoming challenges of limited negative volume and tissue bed mobility and thus producing a prosthesis with satisfactory aesthetic and retentive results.

REFERENCES

1. Ju Yon Sophie Yi, Eric J Dierks, Larry Michael Over, Matthew J Hauck; Prosthetic Reconstruction of the Orbit/Globe; Den Clin North America 2013; 7:697-712
2. Challian VA, Drane JB, Standish SM. Maxillofacial Prosthetics. Multidisciplinary Practice.
3. Beumer J, Curtis TA, Marunick MT. ed 2. St Louis: Ishiyaku Euroamerica; 1996. Maxillofacial rehabilitation: Prosthodontic and Surgical Considerations
4. Thomas D. Taylor. (2000). Clinical Maxillofacial Prosthesis. Quintessence Publishing Co. Chicago, pp 236
5. Montgomery P, Kiat-amnuay S. Survey of Andreas CJ. Survey of currently used materials for fabrication of extra-oral maxillofacial prosthetics. J Prosthodont 2010;19:482-490

6. Lontz JF. State of the art materials used for maxillofacial prosthetic reconstruction. Dent Clin North M 1990; 34:307-325.
7. Wang RR, Andres CJ. Hemifacial microsomia and treatment options for orbital replacement: a review of literature. J Prosthet Dent 1999;82:197-204.
8. Binit Shrestha, Sita Thaworanunta. Orbital prosthesis fabrication: Current challenges and future aspects Open Access Surgery 2016;9n21-28
9. Curi MM, Oliveira MF, Molina G, et al. Implants in the rehabilitation of craniofacial defects: Implant and prosthesis survival rates peri-implant soft tissue evaluation. J Oral Maxillofac Surg. 2012;70:1551–1557.
10. Granström G, Bergström K, Tjellström A, Brånemark PI. A detailed analysis of titanium implants lost in irradiated tissues. Int J Oral Maxillofac Implants. 1994;9:653–662.
11. Nishimura RD, Roumanas E, Moy PK, Sugai T, Freymiller EG. Osseointegrated implants and orbital defects: U.C.L.A. experience. J Prosthet Dent. 1998;79:304–309.
12. Tadashi Akamatsu, Noriwichi Kawashima. A blinking periorbital prosthesis using surface electromyographic signals of the orbicularis oculi muscle. Eur J Plast Surg. 2015; 38: 371–376.
13. Lotfi B. Merabet. Building the Bionic Eye: An Emerging Reality and Opportunity. Prog Brain Res. 2011; 192: 3-15

Source of Support: Nil; **Conflict of Interest:** None

Submitted: 11-10-2019; **Accepted:** 11-11-2019; **Published:** 24-11-2019