

Clinical and Histopathological Correlation of Cutaneous Leishmaniasis in Pir Panjal region of Jammu and Kashmir, India

Mohd Ramzan Bhatti¹, Shabnam Sarfraz², Parvaiz Anwar Rather³

ABSTRACT

Introduction: Cutaneous leishmaniasis has a wide distribution, spreading from the Indian subcontinent, across Central and South-Western Asia, to the Mediterranean Basin, the northern half of the African continent, and Central and South America. In India, it is endemic to the Thar Desert of Rajasthan. Some cases have been reported from the north western region of Indo-Gangetic plain. The present study was aimed to see the correlation of clinical features and histopathological findings in clinically diagnosed cases of cutaneous leishmaniasis in Pir Panjal region of Jammu and Kashmir which is nonendemic area.

Material and Methods: It was an observational and descriptive study and was conducted over a period of 1 year from June 2016 to May 2017 in Pir Panjal region of Jammu and Kashmir. 62 patients with clinically suspicious lesions of CL were studied with particular reference to different histological patterns. Clinical features were correlated with histological patterns. 56 of these were diagnosed as true clinical cases on the basis of criteria for clinical diagnosis and therapeutic response. There were 37 males and 25 females with an age range of 2 to 78 years. These cases were then subjected to slit skin smear and histopathological examination.

Results: Out of 62 suspected cases, 38 (61.2%) were smear-positive and 24 (39%) demonstrated Leishman Donovan (LD) bodies in histological sections. 29 of the remaining cases showed one of the recognizable histological patterns seen in CL, 6 did not reveal any suggestive histology but responded to antimonial compound, and 1 turned out to be a case of Discoid lupus erythematosus.

Conclusion: Keeping in view the magnitude of problem and limited resources, clinical features may be reliable for diagnosis but this health problem needs further epidemiological studies to know the vectors and parasite strains.

Keywords: Cutaneous Leishmaniasis, Histopathology, Pir Panjal

endemic zones are Deserts of Rajasthan and certain parts of Gangetic plains including the states of Punjab, Himachal Pradesh, National Capital Region, and parts of Uttar Pradesh; however new endemic zones are being reported within and outside these regions. Presently Pir Panjal region of Jammu and Kashmir is showing increased number of cases of cutaneous leishmaniasis. Cutaneous Leishmaniasis can be diagnosed by clinical features in endemic areas but in non-endemic areas and in atypical clinical variants of disease various other diagnostic techniques such as slit skin smear, culture and skin biopsy are required. Slit skin smear and histopathological examination gives a reasonably high yield if properly performed. Giemsa or Leishman stained smears obtained from the lesions are a rapid means of diagnosis. A smear can be made by different methods. For example, touch preparation or impression method, a slit skin smear, fine needle aspiration, or by scalpel scraping.^{6,7,8} Several previous studies have established the value of histopathological examination in the diagnosis of CL and different histological patterns have been reported.⁸ It is important to search for amastigotes, which are diagnostic.⁹⁻¹¹ Modern methods for diagnosis of leishmaniasis are sophisticated and sensitive methods. Some of them can even pick up a trace of antigen in a tissue specimen.^{12,13,14} These include immunofluorescence, immunohistochemistry, polymerase chain reaction, use of monoclonal antibodies, electron microscopic studies, DNA probes. Most of these sophisticated laboratory techniques are very costly and patients cannot afford it. These methods are used to confirm the diagnosis in doubtful cases. In endemic areas, various serological techniques have also been used for diagnosis of CL,¹⁵⁻¹⁶ but in non-endemic areas like Pir Panjal region the clinical diagnosis of a dermatologist remains the mainstay of diagnosis. This study aimed to see the correlation of clinical features and histopathological findings in clinically diagnosed cases in Pir Panjal region which is nonendemic area of Jammu and Kashmir.

INTRODUCTION

Leishmania causes different type of clinical manifestations ranging from cutaneous leishmaniasis and mucosal leishmaniasis to potentially fatal visceral leishmaniasis.^{1,2} According to World Health Organisation, the annual incidence of cutaneous and visceral leishmaniasis is 1-1.5 million and 500,000 cases, respectively.^{3,4} Cutaneous Leishmaniasis is a vector borne parasitic infection of the skin and is transmitted by bite of infected female sandfly Phlebotomus, of which more than 600 species have been identified. The disease presents mostly on face and extremities in the form of nodules, ulcers, plaque or nodulo-ulcerative lesions as relatively painless skin lesions.⁵ In India, the well known

¹Dermatologist, Department of Dermatology, ²Pathologist, Department of Pathology, ³Assistant Professor, Department of Dermatology, GMC, Rajouri, J & K, India

Corresponding author: Shabnam Sarfraz, GMC, Rajouri, J&K, India

How to cite this article: Mohd Ramzan Bhatti, Shabnam Sarfraz, Parvaiz Anwar Rather. Clinical and histopathological correlation of cutaneous leishmaniasis in Pir Panjal region of Jammu and Kashmir, India. International Journal of Contemporary Medical Research 2019;6(6):F15-F17.

DOI: <http://dx.doi.org/10.21276/ijcmr.2019.6.6.16>

MATERIAL AND METHODS

The study was conducted in District hospital Rajouri over a period of 1 year (2016- 2017) which includes 62 patients. A detailed history was taken, onset and duration of lesions, history of associated itching or pain, outdoor sleeping history, insect bite, type of housing, history of similar lesions in the family or neighbourhood were noted followed by clinical examination. Patients were diagnosed using clinical criteria proposed by Bari and Rahman. Consent was taken from the patients. After a detailed history and clinical examination, they were subjected to a slit-skin smear from the margins of lesions and a skin biopsy. Slit skin smear were stained by Leishman stain for LD bodies demonstration. The biopsy was taken from the peripheral part of a skin lesion within the inflammatory active outline in the form of elliptical sections as well as punch biopsies. After processing, the paraffin embedded sections were stained with hematoxylin and eosin (H and E) and then studied under microscope.

Patients who were diagnosed as CL on histopathology, were treated with intramuscular injections of sodium stibogluconate 20 mg/kg/day once daily for 4 weeks in case of multiple lesions and lesions on the face or near the joints, and twice weekly intralesional injections stibogluconate in the remaining patients. In some patients intralesional Injection of Amphotericin B 50mg/ml twice weekly was given for 4 weeks.

RESULTS

A total of 62 patients of cutaneous leishmaniasis were studied. A slight male predominance was seen, 37(59.6%) were males and 25 (40.4%) were females. The ages of patients ranged from 2 to 78 years (mean age 31.5 years). Majority of patients belongs to 25 to 38 years age group. All patients belong to rural areas. The duration of illness varied from 6 weeks to 1.5 years, majority between 3-6 months. Most common occupation was farmers, housewives, students. Majority of patients have single lesion 48 (77.4%) whereas multiple lesions were seen in 14 (22.6%) cases. The most common site of the lesions was the face 52 (83.8%) and the lesions were mainly confined to cheeks, nose, lips, and forehead, followed by upper limbs, neck and trunk Figure 1. 14 patients had multiple lesions involving more than one anatomical region. Nodulo-ulcerative types of lesions were common 43 (69.3%) followed by erythematous plaques 12 (19.3%), combined lesions 5 (8.0%) and nodules 3 (4.9%). These lesions are non-itchy and painless, frequently covered by adherent crusts.

Out of the 62 patients registered as clinical cases, slit skin smear was positive in 38 (61.2%) patients. On histopathological examination Leishman- Donovan bodies were present either intracellularly or extracellularly in 24 (38.7%) patients. 39 (62.9%) demonstrated Leishman Donovan (LD) bodies either in slit skin smears or in histological sections, 13 (20.9%) patients were only smear-positive (histology negative), and 1 (1.6%) patient was only positive on histology (smear negative). 23 (37.1%) cases were negative on slit skin smear as well as on histology. Of the remaining 23 (37.1%), 16

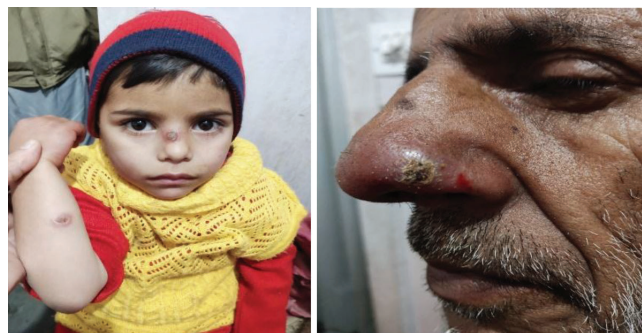

Figure-1: Clinical presentation of cutaneous leishmaniasis

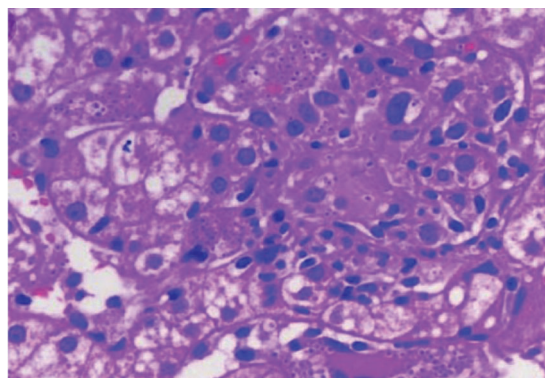


Figure-2: Histopathology showing granulomatous infiltrate and numerous intra- as well as extracellular LD bodies (H and E, x100)

showed one of the recognizable histological patterns seen in CL, three patients had nonsuggestive histology but responded to a therapeutic trial of pentavalent antimony compound, one turned out to have DLE on histology, another turned out to have sporotrichosis, two patients were lost to follow up.

The following two histological patterns were seen.

- Mixed inflammatory pattern with presence of LD bodies 24(39%)
- Granulomatous pattern with more plasma cells and lymphocytes but absence of LD bodies 29(46.8%).

Results with H and E and Leishman stains were similar. All the clinically diagnosed and histopathologically supported cases responded satisfactorily and showed significant to marked healing at the end of 4 weeks.

DISCUSSION

CL, is an important public health problem in developing countries, such as India. Initially it was confined to certain areas and now it is spreading to areas that were previously nonendemic and new focus of infection are regularly being encountered in India as well as Pakistan¹⁷⁻²⁰. Cutaneous Leishmaniasis in the Old World is caused by *Leishmania tropica*, *L. Major* and *L. aethiopica*. New World Leishmaniasis is caused by *L. Mexicana*, *L. amazonensis*, and *L. braziliensis*⁵. It is recommended that CL should be included in the differential diagnosis of common diseases such as erysipelas, chronic eczema, herpes zoster and paronychia and uncommon disorders such as lupus vulgaris, squamous cell carcinoma, sporotrichosis, mycetoma and other deep mycosis.²¹ Epidemics of CL have been associated with deforestation, road construction in which humans

intrude in the habitat of the vector. A study by Sharma²² and others reported a higher incidence of cutaneous leishmaniasis during the summer in northern state of Himachal Pradesh in India. This is similar to present study, in which an increased in incidence of cutaneous leishmaniasis during summer is observed. This finding could be caused by the fact that many persons sleep in open during the summer months and thus are exposed to the bites of infected sand flies.

Diagnosis of cutaneous Leishmaniasis largely depends on clinical appearance, especially in endemic areas. However in non-endemic areas diagnosing of CL may be challenging when superadded infection distort the clinical picture, or when any unusual variant is seen. In such cases laboratory-diagnostic techniques such as slit skin smears, impression or touch smears, culture for parasites, and histopathological study of skin biopsy specimens help to reach final diagnosis. Demonstration of parasites in skin smear is specific method of diagnosis. The positivity of smear depends upon age of the lesion; younger lesions being more likely to be positive.²³ Our study was aimed at correlating the clinical features and histopathological findings in Pir Panjal region of J&K, Clinical profiles of the patients including age; duration of illness; number of lesions; distribution, morphology, and progression of the lesions; and major clinical types of the disease were almost similar to those seen in previous studies.^{17,24} Since the disease is more common in the countryside, its diagnosis depends primarily on the clinical acumen of a dermatologist in our part of the world. Therefore, our approach to diagnosis is more clinically oriented with some simple, cheap, and easy tests, such as smears and biopsies, to confirm the diagnosis. When available, sophisticated modern diagnostic tests may be reserved for academic purposes.

CONCLUSION

The present study has highlighted new focus of cutaneous leishmaniasis in Pir Panjal region of Jammu division. Further, epidemiological studies are needed to establish the identity of vector and the strain to control this health problem.

REFERENCES

- Vega-Lopez F, Hay RJ. Parasitic worms and protozoa. In: Burn T, Breathnach S, Cox N, Griffiths C, editors. *Rook's Textbook of Dermatology*. Eight edition. Volume 2. Boston, MA: Blackwell Publishing; 2010;43:37.32-37.
- Desjeux P. Leishmaniasis: current situation and new perspectives. *Comp Immunol Microbiol Infect Dis*. 2004; 27:305-318.
- Bari Arfan UL. Epidemiology of cutaneous Leishmaniasis. *J Pak Assoc of Dermatol*. 2006; 16: 156-162
- World Health Organisation. Control of Leishmaniasis. Geneva: World Health Organisation; 2006. Report of WHO Secretariat, Executive board EB 118/4, 118th Session.
- UL Bari, Ber Rahman S. Correlation of clinical histopathological and microbiological findings in 60 cases of cutaneous leishmaniasis. *Indian J Dermatol Venereol Leprol* 2006; 72: 28-32.
- Grevelink SA, Lerner EA. Leishmaniasis. *J Am Acad Dermatol* 1996; 34: 257-72.
- Sharquie KE, Hassen AS, Hassan SA, Al-Hamami IA. Evaluation of diagnosis of cutaneous leishmaniasis by direct smear, culture, and histopathology. *Saudi Med J* 2002; 23: 925-8.
- Moscella SL, Cropley TG. Diseases of the mononuclear phagocytic system. In: *Dermatology*, Moschella SL, Hurley HJ Eds. WB Saunder. London/Philadelphia. 3rd edn. 1992; 1031-1137.
- Venkataram M, Moosa M, Devi L. Histopathological spectrum in cutaneous leishmaniasis: a study in Oman. *Indian J Dermatol Venereol Leprol* 2001; 67:294-8.
- Ridley DS. A histological classification of cutaneous leishmaniasis and its geographical expression. *Trans R Soc Trop Med Hyg* 1980; 74:515-21.
- Mansour L, el-Marhoumy SM, Eid MM, Gawish K. Histopathological study of different clinical forms of cutaneous leishmaniasis. *J Egypt Soc Parasitol* 1993;23:591-7.
- Safaei A, Motazedian MH, Vasei M. Polymerase chain reaction for diagnosis of cutaneous leishmaniasis in histologically positive, suspicious and negative skin biopsies. *Dermatology* 2002;205:18-24.
- Rab M, Al Rustamani L, Bhutta R, Mahmood M, Evans D. Cutaneous leishmaniasis: iso-enzyme characterisation of *Leishmania tropica*. *J Pak Med Assoc* 1997;47:270-3.
- Singh S, Sivakumar R. Recent advances in the diagnosis of leishmaniasis. *J Postgrad Med* 2003;49:55-60.
- Raj VS, Ghosh A, Dole VS, Madhubala R, Myler PJ, Stuart KD. Serodiagnosis of leishmaniasis with recombinant ORFF antigen. *Am J Trop Med Hyg* 1999;61:482-7.
- Schoone GJ, Hailu A, Kroon CC, Nieuwenhuys JL, Schallig HD, Oskam L. A fast agglutination-screening test (FAST) for the detection of anti-leishmania antibodies. *Trans R Soc Trop Med Hyg* 2001;95:400-1.
- Mujtaba G, Khalid M. Cutaneous leishmaniasis in Multan, Pakistan. *Int J Dermatol* 1998;37:843-5.
- Raja KM, Khan AA, Hameed A, Rahman SB. Unusual clinical variants of cutaneous leishmaniasis in Pakistan. *Br J Dermatol* 1998;139:111-3.
- Rahman SB, Bari AU, Khan AA. A new focus of cutaneous leishmaniasis in Pakistan. *J Pakistan Assoc Dermatol* 2003;13:3-6.
- Sharma RC, Mahajan VK, Sharma NL, Sharma A. A new focus of cutaneous leishmaniasis in Himachal Pradesh (India). *Indian J Dermatol Venereol Leprol* 2003;69:170-2.
- Bari AU, Rahman SB. Many faces of cutaneous leishmaniasis. *Indian J Dermatol Venereol Leprol*. 2008; 74: 23-7.
- Sharma NL, Mahajan VK, Kanga A, Sood A et al. Localized cutaneous leishmaniasis due to *Leishmania donovani* and *Leishmania tropica*: preliminary findings of the study of 161 new cases from a new endemic focus in Himachal Pradesh, India. *Am J Trop Med Hyg*. 2005; 72: 8198-824.
- Schewach- Millet M, Khana M, Rinen M. Mucosal involvement of cutaneous leishmaniasis. *Int J Dermatol*. 1986; 25:113-114.
- Herwaldt BL. Leishmaniasis. *Lancet* 1999; 354: 1191-9.

Source of Support: Nil; **Conflict of Interest:** None

Submitted: 06-05-2019; **Accepted:** 30-05-2019; **Published:** 18-06-2019