

# A Prospective Study of Incidence of Malignancy in Solitary Nodule of Thyroid

S. Muthu<sup>1</sup>, R. Saravanakumar<sup>2</sup>

## ABSTRACT

**Introduction:** Thyroid nodules are common. They can be either benign or malignant. Solitary thyroid nodules have a high likelihood of being malignant. They should be characterized properly for optimum management. Study aimed to find the incidence of malignancy in solitary nodule thyroid.

**Material and Methods:** 54 patients aged between 18 and 75 years who underwent solitary thyroid nodules surgery from January 2018 until December 2018 were included. Data collection by meticulous history taking and clinical examination, appropriate laboratory and radiological investigations, operative findings, histopathological report, and follow-up of cases.

**Results:** the Adenomatous colloid goiters were observed in 16 patients (30%), followed by Nodular goiter in 10 patients (18.5%). In the present series, papillary carcinoma is the commonest malignancy of Solitary Thyroid Nodule 8 (80%) of the total of 10 malignancies.

**Conclusion:** Solitary nodule is more common in females. The most common malignancy in solitary nodule thyroid is papillary carcinoma FNAC is an important investigation in the evaluation of the solitary nodule of thyroid.

**Keywords:** Thyroid, Malignancy, Solitary Nodule

## INTRODUCTION

The solitary thyroid nodule, defined as a palpably discrete swelling within an otherwise apparently normal gland, is usually a benign lesion. Thyroid nodules are common in both hyperthyroid and euthyroid patients; they are present in half of all thyroid glands that are subject to careful pathologic examination.<sup>1</sup> The most obvious indication for surgery is the cytological diagnosis of carcinoma of the thyroid. Patients having a diagnosis of 'suspicious for malignancy' on FNAC should also undergo surgery. Every non-functioning solitary nodule diagnosed as follicular or oxyphilic neoplasia is an indication for surgery since FNAC is unable to distinguish between benign and malignant follicular lesions.<sup>2</sup> Cystic lesions of the thyroid are usually benign. However, complex cystic lesions, cysts larger than 4 cm in diameter, and recurrent cysts after several percutaneous aspirations are indications for resection because of an increased risk of carcinoma within the thyroid gland.<sup>3,4</sup> Also, one should be aware that thyroid cancers, especially those larger than 4 cm in diameter, may necrose and produce cystic components. Due to the low risk of malignancy in nonpalpable nodules that are incidentally detected by thyroid imaging, most patients can be managed by simple follow-up neck palpation.<sup>5</sup> When a thyroid nodule enlarged despite thyroid stimulating hormone (TSH) suppressive therapy with thyroxine, this is

an indication for surgery.<sup>6</sup> Study aimed to find the incidence of malignancy in solitary nodule thyroid

## MATERIAL AND METHODS

This prospective study was conducted in the Department of General Surgery at tertiary care hospital. All adult patients aged between 18 and 75 years who underwent solitary thyroid nodules surgery from June 2017 until May 2018 were included. A nodule was considered solitary if no other nodules in the gland were identified by ultrasonography. The presence of other nodules, irrespective of size, excluded patients from the study. Use of antithyroid drugs, beta-blockers, blood transfusions, or any other medications was prescribed based on individual status and was noted. Sonographic features and cytology and histology data were recorded and analysed. All FNAC was performed by experienced radiologists with cytology technicians in attendance to ensure uniform sample preparation. An assessment of cellularity was not made at the time of aspiration. Every patient was followed up post-operatively during the course of management in the hospital to note the development of and management of complications.

## RESULTS

In this study 54 patients were included. 14% of patients were male and 86% were female. The mean age of the study patients was 41.24 years. All the cases in the present study presented complaint of swelling in the region of the thyroid. Only a few patients presented with pain, discomfort, and dysphagia. All the mentioned additional symptoms were of mild degree. Of 54 cases, four presented with features of thyrotoxicosis, one with hypothyroidism, and rest all were in euthyroid state. (Figure 1) After the final histopathology, the Adenomatous colloid goiters were observed in 16 patients (30%), followed by Nodular goiter in 10 patients (18.5%). There were 9 patients (17%) who had Follicular adenoma. Of the 54 specimens examined, 8 (14.5%) were papillary carcinomas, 2 (3.7%) were follicular carcinomas. (Figure 2)

<sup>1</sup>Associate Professor, Pudukottai Medical College and Hospital, Tamilnadu, <sup>2</sup>Assistant Professor, Pudukottai Medical College and Hospital, Tamilnadu, India

**Corresponding author:** Dr. R. Saravanakumar, Assistant Professor, Pudukottai Medical College and Hospital, Tamilnadu, India

**How to cite this article:** S. Muthu, R. Saravanakumar. A prospective study of incidence of malignancy in solitary nodule of thyroid. International Journal of Contemporary Medical Research 2019;6(5):E24-E26.

**DOI:** <http://dx.doi.org/10.21276/ijcmr.2019.6.5.29>

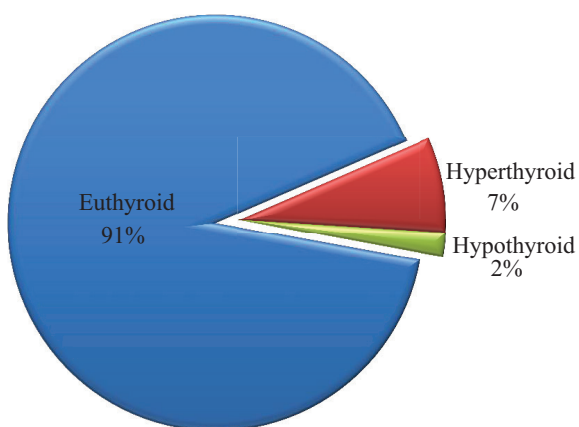


Figure-1: Thyroid functional status

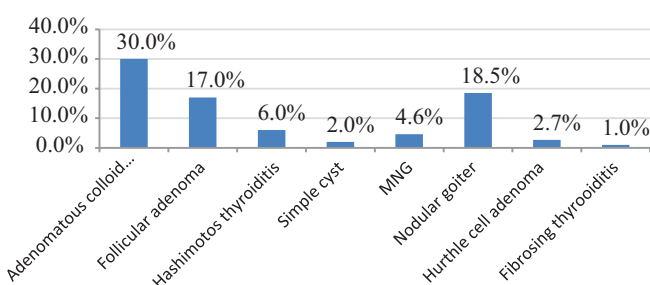


Figure-2: HPE reports

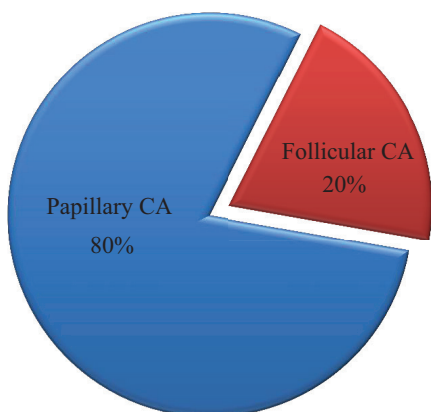


Figure-3: Types of Carcinoma

The incidence of malignancy in the present series is 18.51% which is comparable with other studies. In the present series, papillary carcinoma is the commonest malignancy of Solitary Thyroid Nodule 8 (80%) of the total of 10 malignancies. (Figure 3) Most of the patients presented with the size of about 3-5 cm. In the study, as such there is no correlation between the size of the nodule and the occurrence malignant nodule.

## DISCUSSION

Thyroid nodule refers to a distinct lesion within the thyroid gland that is palpably or radiologically distinct from the surrounding thyroid parenchyma. Benign causes of thyroid nodule include the colloid nodule and the classical multinodular goiter. Occasionally, nodularity is noticed in patients with Hashimoto's thyroiditis and Graves' disease. Malignant causes of nodules include thyroid cancer, lymphoma as well as metastasis to the thyroid gland.

Therefore, it is recommended that all thyroid nodules >1 cm in size should undergo evaluation. This includes both palpable and nonpalpable nodules, detected by imaging.<sup>7</sup> Solitary thyroid nodules are defined clinically as a localized thyroid enlargement with an apparently normal adjacent gland. According to literature, STN has a higher risk of malignancy than multiple nodules.<sup>8</sup> Because of this reason, surgeons tend to treat them with a high degree of suspicion and plan treatment in a systematic manner. Clinically, STNs are common, being present in up to 50% of the elderly population. The majority of STNs are malignant.<sup>8-10</sup> The preliminary investigation should include a careful history and thorough clinical examination and thyroid function tests.<sup>11</sup>

Traditionally discovered thyroid nodules had been shown to harbor a malignancy in about 5% of cases. However, several recent studies have shown a disturbingly high number of malignancies in incidentally discovered thyroid nodules. In 2002, Papini et al evaluated almost 500 patients referred for an incidentally discovered thyroid nodule. After selecting patients for surgical resection based on FNAB results, 31 patients were found to have well-differentiated thyroid cancer (8%).<sup>12</sup> Shetty et al,<sup>5</sup> in the Mass General study, found a rate of primary thyroid malignancy in incidental nodules of 11.3%.<sup>13</sup>

## CONCLUSION

Clinically, solitary thyroid nodules should be investigated thoroughly with a high index of suspicion because there is at least a 10–20 percent probability of malignancy. We have shown a higher rate of malignancy than in other published series but our cases are truly solitary nodules based upon ultrasonography and histopathological examination, rather than oligo-nodular glands. Therefore, a truly solitary nodule should be viewed with greater suspicion and surgery is strongly recommended.

## REFERENCES

1. Hegedus L. Clinical practice. The thyroid nodule. *N Engl J Med* 2004;351:1764–71.
2. Baloch ZW, Sack MJ, Yu GH, LiVolsi VA & Gupta PK. Fine-needle aspiration of thyroid: an institutional experience. *Thyroid* 1998; 8: 565-569.
3. Castro MR & Gharib H. Thyroid nodules and cancer. When to wait and watch, when to refer. *Postgraduate Medicine* 2000; 107: 119-120.
4. Soh EY & Clark OH. Surgical considerations and approach to thyroid cancer. *Endocrinology and Metabolism Clinics of North America* 1996; 25: 115-139.
5. Tan GH & Gharib H. Thyroid incidentalomas: management approaches to nonpalpable nodules discovered incidentally on thyroid imaging. *Annals of Internal Medicine* 1997; 126: 226-231.
6. UpToDate [Internet]. Uptodate.com. 2019 [cited 7 March 2019]. Available from: <https://www.uptodate.com/contents/thyroid-hormone-suppressive-therapy-for-thyroid-nodules-and-benign-goiter>
7. Popoveniuc G, Jonklaas J. Thyroid nodules. *Med Clin*

- North Am. 2012;96:329-49.
8. Tai JD, Yang JL, Wu SC, Wang BW, Chang CJ. Risk factors for malignancy in patients with solitary thyroid nodules and their impact on the management. *J Cancer Res Ther* 2012;8:379-83.
  9. Gupta M, Gupta S, Gupta VB. Correlation of fine needle aspiration cytology with histopathology in the diagnosis of solitary thyroid nodule. *J Thyroid Res* 2010;2010:379051.
  10. Iqbal M, Mehmood Z, Rasul S, Inamullah H, Shah SS, Bokhari I. Carcinoma thyroid in multi and uninodular goiter. *J Coll Physicians Surg Pak* 2010;20:310-2.
  11. Delbridge L. Solitary thyroid nodule: Current management. *ANZ J Surg* 2006;76:381-6.
  12. Papini E, Guglielmi R, Bianchini A, Crescenzi A, Taccogna S, Nardi F, et al. Risk of malignancy in nonpalpable thyroid nodules: predictive value of ultrasound and color-Doppler features. *J Clin Endocrinol Metab.* 2002;87:1941–6.
  13. Shetty S, Maher M, Hahn P, Halpern E, Aquino S. Significance of Incidental Thyroid Lesions Detected on CT: Correlation Among CT, Sonography, and Pathology. *American Journal of Roentgenology.* 2006;187:1349-1356.

**Source of Support:** Nil; **Conflict of Interest:** None

**Submitted:** 29-03-2019; **Accepted:** 18-04-2019; **Published:** 20-05-2019