

Comparative Study between Dynamic Hip Screw and Proximal Femoral Nail in the Management of Trochanteric and Subtrochanteric Fractures

Tanay R. Prabhoo¹

ABSTRACT

Introduction: Proximal femoral Fractures are a subset of fractures that occur in the hip region and occupy large proportion of hospitalization amongst trauma cases. An overwhelming majority of these patients (>90%) are aged above 50 years. These are classified on the basis of anatomic location for example, femur neck fracture; inter trochanteric fracture and subtrochanteric fracture. Each of these fractures require different modes of management and treatment. Therefore, the aim of the present study was to achieve fracture union by using two different kinds of internal fixation modality devices in similar type of fractures.

Material and Methods: This is a randomized prospective study of 40 cases of intertrochanteric fractures, admitted to Pravara Rural Hospital (PIMS), Loni, Ahmednagar. All fractures were classified by the Seinsheimer classification system. The patients were treated with proximal femoral nailing (PFN) and/or dynamic hip screw (DHS) and were categorised randomly into two groups, each of 20 patients, 20 were treated by dynamic hip screw and 20 were treated with proximal femoral nail (PFN).

Results: The intraoperative parameters were in favour of PFN with significantly less duration of surgery, length of incision and blood loss but more fluoroscopy time. Postoperatively also, PFN group patients excelled with significantly less post operative pain, less incidence of deep infection, less mean limb length discrepancy and more patients regaining their pre injury walking capability with also fewer complications.

Conclusion: PFN emerged to be superior to DHS in unstable intertrochanteric fractures. The use of proximal femoral nail is helpful in treating inter trochanteric fractures with comminution and loss of lateral buttress. Intramedullary implants have been quite effective in subtrochanteric fractures and should be preferred better than extramedullary plate fixation systems.

Keywords: Dynamic Hip Screw, Proximal Femoral Nail, Subtrochanteric Fracture, Internal Fixation

Intertrochanteric: - fracture line along greater and lesser trochanter.

Peri- trochanteric fracture: - fracture extends proximally into the greater trochanter. Both of the trochanter may be involved and comminution is present. It is most common type.

Inter-subtrochanteric type: - fracture has both trochanteric as well as subtrochanteric element. It is always comminuted and a difficult fracture to treat. It results from very high velocity injury and usually occurs in younger age group.

Subtrochanteric: - fracture below the lesser trochanter.

It can be classified into intracapsular (femoral head and neck) fractures that are contained within the hip capsule itself and extracapsular (intertrochanteric and Subtrochanteric) fractures. A femoral neck fracture includes subcapital, transcervical and basi cervical fractures. Trochanteric fracture involves the proximal femur between the cervical region and the shaft and is commonly seen in the elderly people. With the rising life expectancy throughout the globe, the number of elderly individuals is increasing in every geographical region, and it is expected that the incidence of hip fracture will rise from 1.66 million in 1990 to 6.26 million by 2050.³

Subtrochanteric typically defined as area from lesser trochanter to 5cm distal to it. Fractures with an associated intertrochanteric component may be called intertrochanteric fracture in which fracture is seen along the base of the femoral neck between the trochanters and pertrochanteric (involving both greater and lesser trochanters). The frequency of these fractures has risen primarily due to the increasing life span and more sedentary life style brought on by urbanization. Trochanteric fractures are most commonly seen in younger population due to high velocity trauma, whereas in the elderly population it is due to trivial trauma. Subtrochanteric

INTRODUCTION

Hip fracture is a major threat and cause of disability, dependency and excess mortality among older adults. Indeed, hip fractures remain a persistent cause of excessive morbidity, reduced life quality and premature mortality among older adults. It can be defined as a break in the continuity in the upper quarter of the femur (thigh) bone.¹ The extent depends on the forces which are involved. Most hip fractures occur in at femoral head, neck and trochanter.² Classification is as follows:

¹Consultant, Department of Orthopedics, Mukund Hospital, Andheri East, Mumbai, Maharashtra, India

Corresponding author: Dr. Tanay R. Prabhoo, 603/B, Everest, Church Road, Marol, Andheri (East), Mumbai -400059, India

How to cite this article: Tanay R. Prabhoo. Comparative study between dynamic hip screw and proximal femoral nail in the management of trochanteric and sub trochanteric fractures. International Journal of Contemporary Medical Research 2018;5(10):J12-J17.

DOI: <http://dx.doi.org/10.21276/ijcmr.2018.5.10.26>

is a fracture with a fracture line running from an area within 5 cm distal to the lesser trochanter where the iliopsoas (hip flexor) attaches.^{4,5}

The trochanteric fractures are managed by conservative methods and there is effective union of the fracture. If appropriate safety measures are not taken the fracture undergoes malunion, which results in external rotation deformity at the fracture site with shortening and limitation of hip movements. In addition, complications related to prolonged immobilization involving bedsores, deep vein thrombosis and respiratory infections may also take place.⁶ Therefore, the aim of the treatment should be prevention of malunion and early mobilization. Surgery by internal fixation of the fracture is an ideal choice. There are different types of internal fixation devices available to treat trochanteric fractures. The most commonly used device is the dynamic hip screw with side plate assemblies. This is a collapsible fixation device, which allows the proximal fragment to settle on the fixation device, around its own position of stability.^{7,8} The current implant for management of trochanteric fractures is proximal femoral nail, which is also a collapsible device with added rotational stability. This implant is a centro medullary device which is biomechanically sound. It has merits like small incision is given with minimal blood loss. Pertrochanteric and subtrochanteric fractures of femur possess clinical, structural, anatomical and biomechanical characteristics that distinguish them from intracapsular fractures.⁹

Various internal fixation devices have been used in subtrochanteric fractures, because of high incidence of complications reported after surgical treatment with each implant. Stable fractures can be well managed with dynamic hip screw alone with good results proven by various studies.^{10,11} It is seen that the unstable fractures are difficult to manage with dynamic hip screw alone. Complications like screw cut out, shortening of limb, deformity of proximal femur, and non-union are found to be higher in unstable fractures as compared with stable fractures.¹² Hence the need of the study was to evaluate the effectiveness and strength of proximal femoral nail and dynamic hip screw in the management of trochanteric and subtrochanteric fractures.

MATERIALS AND METHODS

The present study was conducted in Pravara Rural Hospital (PIMS), Loni, District Ahmednagar from July 2009 to July 2011. The study consisted a total of 40 adult patients of pertrochanteric fractures of femur satisfying the inclusion criteria, who are treated with Proximal Femoral Nail (20 cases) and Dynamic Hip Screw (20 cases). All patients who were above 60 years with intertrochanteric fractures were selected for this study. Patients with pathological fractures due to metastasis, tumours were excluded and also compound fractures were excluded from this study. The permission to conduct study was approved by the ethical committee of the institution. All subjects gave written informed consent to participate in the study. Pre operative measures were also recorded carefully with radiographic evaluation. Harris hip

score was used to assess patient rated outcomes. Results are graded as excellent (90-100), good (80-89), fair (70-79) or poor (<70).

Surgical Procedures

Dynamic Hip Screw with Plate: An incision of 8 cm to 10 cm was taken at the base of the greater trochanter and is extended distally. The iliotibial band was incised to expose the vastus lateralis which was cut in the line of its fibres to expose the underlying bone. The guide wire was passed at a point along the lateral cortex just opposite the lesser trochanter. This should lie in the dead centre or inferior of the head in centre or posterior in lateral views.

Once guide pin position was confirmed, then the reamer was set to within 5 mm of the guide wire length and reaming was done, taking care to prevent entry of the guide pin into the pelvis, taping was done but this step was omitted in severely osteoporotic bone. Screw was inserted and guide wire angle with shaft was confirmed and accordingly angled with four hole-sided plate which was then fixed to the lateral cortex. The wound was closed in layers over a suction drain.

Proximal Femoral Nail: Care was taken for an anatomical reduction before the insertion of the nail. A 5 cm skin incision was given of approx. 2-3 cm from the greater trochanter. A guide wire was passed to hold the reduction to make sure of its presence in the medullary canal. After the entry point was marked and gently reamed then nail was inserted with zig attached to it. Two guided wire was passed using the aiming device. Using appropriate drills, hip pin and the neck screw was inserted. The wound was closed in layers. Postoperatively, antibiotic prophylaxis was given in form of IV for 5 days and then through oral antibiotics for 9 days.

STATISTICAL ANALYSIS

The statistical analysis was done with the help of statistical software SPSS version 21. One way ANOVA test was applied to the data. Chi square test was done to calculate the p value with different variables. The Fischer's exact test was used for the comparison of paired categorical variables. A value of <0.05 was considered to be statistically significant.

RESULTS

In this study, many of the cases i.e. 10 patients were seen in the age group of 50-60 years, Both in PFN and DHS group 5 cases each (25%). Mean age in years of patients treated

Age (Years)	No. of patients in PFN	No. of patients in DHS
20-30	2 (10%)	2 (10%)
30-40	2 (10%)	1 (5%)
40-50	2 (10%)	2 (10%)
50-60	5 (25%)	5 (25%)
60-70	4 (20%)	4 (20%)
70-80	4 (20%)	5 (25%)
80-90	1 (5%)	1 (5%)
Total	20	20

Table-1: Shows age distribution of patients among both the groups

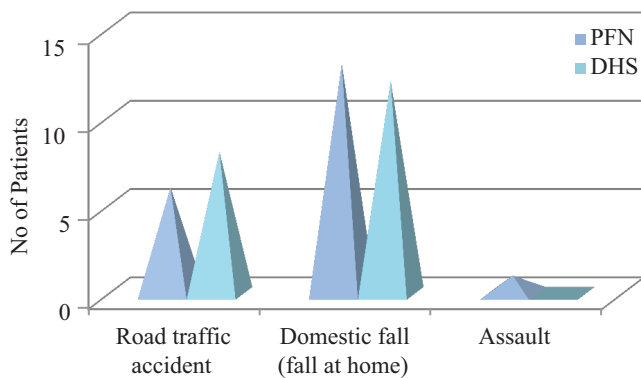


Table-2: Shows the mode of trauma among both the groups

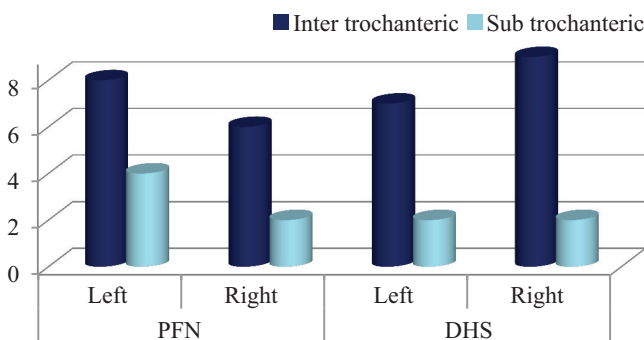


Table-3: Shows side of trauma in both the groups

Type of fracture	Method of Fixation		Total
	PFN	DHS	
Type 1	0(0.0%)	2 (10%)	2 (5%)
Type 2	12 (60%)	10 (50%)	22 (55%)
Type 3	7 (35%)	6 (30%)	13 (32.5%)
Type 4	1 (5%)	2 (10%)	3 (7.5%)
Type 5	0 (0.0%)	0 (0.0%)	0 (0.0%)
Type 6	0 (0.0%)	0 (0.0%)	0 (0.0%)
Total	20 (100.0%)	20 (100.0%)	40 (100.0%)

Table-4: Type of fracture as per the Jensen and Ichealsen's modification of Evans classification in both the groups (p=0.574)

Injuries	No. of patients	
	PFN	DHS
Head injuries	0	2 (50%)
Fracture lower end radius	2 (66.67%)	2 (50%)
Fracture calcaneum	1 (33.33%)	0
Total	3	4

Table-5: Types of associated injuries seen in both the groups

Complications	No. of Patients PFN	No. of Patients in DHS
Chest infection	1 (5%)	1 (5%)
Urinary tract infection	1 (5%)	1 (5%)
Superficial wound infection	1 (5%)	2 (10%)

Table-6: Various types of complications seen in both the groups

with PFN was 56.6. Mean age in years of patients treated with DHS was 58.5. The youngest patient was found to be

Harris Hip Scores	Method of Fixation		Total
	PFN	DHS	
Excellent	7	5	12
Good	12	10	22
Fair	1	4	5
Poor	0	1	1
Total	20	20	40

Table-7: Functional outcomes as per Harris Hip scores in both of the groups (p<0.001)

	PFN	DHS
Blood Loss	80ml±12.40 ml	180ml±36.28 ml
Radiation Exposure	55±1.2 (in no.)	42±4 (in no.)
Duration of Surgery	60 min±21min	90min±34min
Hospital Stay	12.94 days	14.76 days
Sliding	4.5mm	6.4mm
Shortening	4.2mm	7.3mm
Implant Failure	1 (2%)	2 (4%)
Non-Union	0	1 (2%)
Deaths	0	0
GT Splintering	2 (4%)	0

Table-8: Overall functional outcomes seen in both the groups

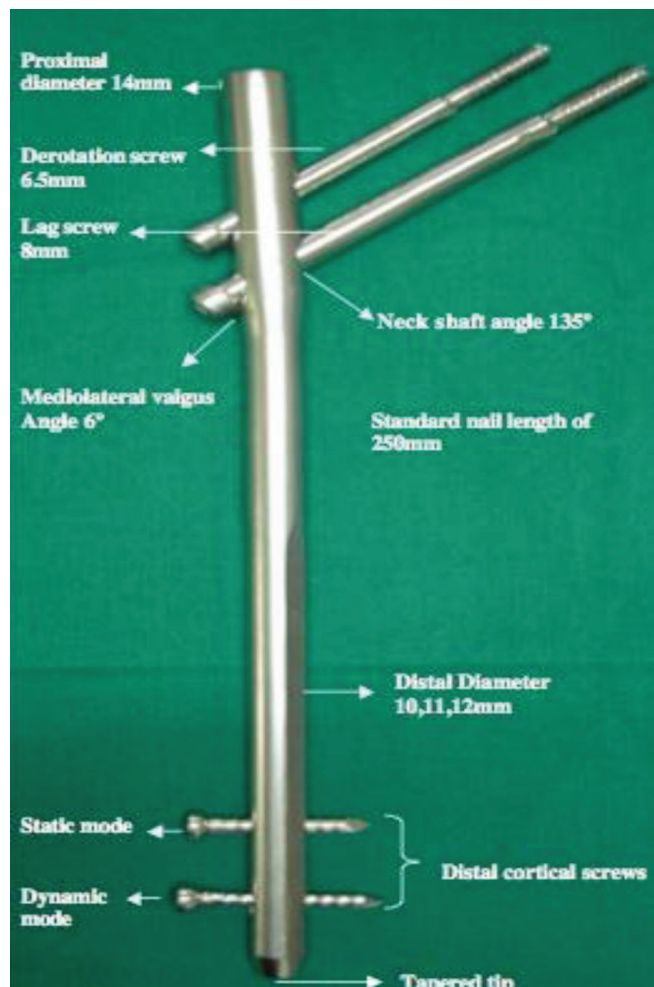


Figure-1: PFN

24 years old while the oldest was 86 years old in this study. Patients with age of more than 50 years constituted 70% of the total subjects and rest constituted of 30% with age of less

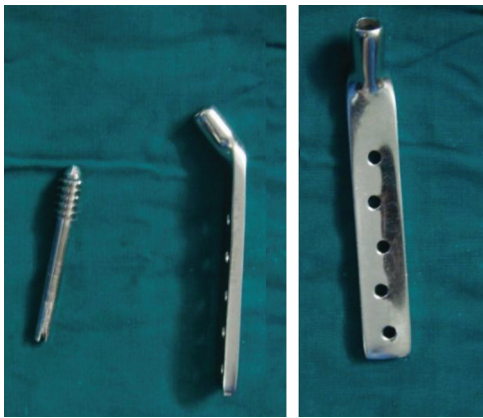

Figure-2: DHS

than 50 years (Table-1). Most of our patients were 50 years and above who had domestic fall (fall at home) and trivial trauma as the main reason behind the fracture while in road traffic accident (RTA), young patients were most commonly affected (Table-2).

In Table-3, out of the 20 cases in PFN, 12(60%) patients were found to have proximal femoral fractures on the left side while 8(4%) patients were having fracture on the right side. Amongst the 20 cases operated by DHS, 9(45%) patients were found to have proximal femoral fractures on the left side while 11(55%) patients were having fracture on the right side. Regarding the side of the fracture, the number of patients in each subgroup as per the Jensen and Ichealsen's modification of Evan's classification were also recorded in this study. (Table-4).

In Table-5, two patients had closed head injury which were managed conservatively (patients operated in the DHS group). In this study, 2 patients (in each group PFN and DHS) had distal radius fracture and 2 patients (DHS group) were treated conservatively with closed reduction and a below elbow cast application while other 2 patients (from PFN group) were treated with open reduction and internal fixation with Ellis (buttress) plating.

In the study, we have 14(70%) intertrochanteric fractures with variable degree of comminution, 6(30%) cases were of subtrochanteric fractures which were treated by PFN. While 16(80%) of intertrochanteric fractures and 4(20%) of subtrochanteric fractures were treated by DHS. As per the Harris hip score, in the DHS group overall, 5 patients had excellent results, 10 patients had good score, and 4 patients had fair results and 1 patient was recognized with poor score results. In the PFN group, 7 patients had excellent results, 12 patients had good score and 1 patient had fair and none had poor score results (Table-7)

In Table-8, blood loss was seen more in patients in DHS group but the radiation exposure was less as compared to the PFN group. Duration of surgery, hospital stay and implant failure was found to be more among patients in DHS group.

DISCUSSION

Fractures of intertrochanteric femur have always been taken as a major challenge by the community of orthopedic surgeons, not only for achieving fracture union, but for restoration of

normal functions in the shortest possible time with minimal side-effects. The goal of management is to provide desired mobilization, rapid rehabilitation and fast reversion of individuals to pre-morbid home and work environment as a functionally and psychologically independent unit.¹²

Internal fixation done through operative procedures allows for maximum rehabilitation and offers the best opportunity for functional recovery, and hence has become the treatment of choice for fractures in the trochanteric region. Different types of implants are available such as fixed nail plate devices, sliding nail/screw plates and intramedullary devices, out of which the compression hip screws are most commonly used and is considered to be gold standard but recently techniques of closed intramedullary nailing have gained popularity.¹³

In the current study, an effort was made to survey and evaluate success in terms of the management of such fractures by using proximal femoral nail (PFN) and dynamic hip screw (DHS) implants and results were compared among both the groups. Most of the patients in present study were from age group of 5th to 7th decade of life i.e. more than 50 years of age. Mean age in years was found to be 56.5 for group operated by PFN. Mean age in years for group operated by DHS was 58.5. Gallagher and Evans et al conducted a study in which they reported an eight fold increase in trochanteric fractures in men over 80 years and women over 50 years of age which is in concordance with the present study.^{14,15}

The PFN nail used in the study was with uniform length of 25 mm. The average barrel plate used in DHS was 4 holed plate with 135° angulation. Diameter of the nail in PFN varied from 9 mm to 12 mm. In four cases, we have used nail of diameter 9 mm, in 15 cases nail of 10 mm diameter while in one case, nail of 11 mm diameter was used.

The trochanteric region is the most common site of senile osteoporosis because as the age advances hip joint being a major joint in the mechanism of weight bearing, this already weakened part cannot withstand any sudden abnormal stress. Additionally, space between bony trabeculae is enlarged and is filled with fat, whilst unshathing compact tissue is dwindled out and calcar is degenerated.¹⁶

Most of the patients in the present study were males. The ratio of males to female was 2:1 in both the study groups. This clearly showed the preference and better acceptance of surgery by males and higher incidence of trochanteric fractures of femur in male population due to their more active lifestyles.

As ours is a rural setup, the majority of the patients in the series were male as they are more outgoing and engaged in activities like agriculture, driving of motor vehicles and are more likely to be involved or prone to accidents/ fall. Females play a more dormant role and are involved more in household activities.¹⁷

Young patients with intertrochanteric or subtrochanteric fractures sustained trauma either as a result of road traffic accident or fall from height, there by reflecting the requirement of high velocity trauma to cause fracture in the young. In a study done by Keneth J. Koval and Joseph D. Zuckerman found that maximum of hip fractures were

seen in the elderly as a result from a simple fall whereas in young adults, fractures were observed most often due to high energy trauma such as vehicular accidents or a fall from height which is also consistent with the present study.^{18,19}

As in present study we have included intertrochanteric fractures of type I, II and III as well as Sub trochanteric fractures according to Boyd and Griffin, Evans and Seinsheimers classification. But we have not included subtrochanteric fractures variable extension in to femoral shaft and also trochanteric and subtrochanteric fractures with ipsilateral fracture shaft femur. So, need for using long length proximal femoral nail was eliminated. The barrel plate used in the cases treated by DHS was generally 135° 4 holed plates. As per the fracture configuration and fracture line extension, the number of holes in the barrel plate increased.²⁰ Blood loss-measured by mop count (each fully soaked mop containing 50 ml blood) more blood loss was seen in patients who require open reduction. In this study, the incisions given in fractures treated by Proximal femoral nailing (PFN) were small, the mean blood loss was relatively lesser as compared to those treated by Dynamic Hip Screw (DHS). But with meticulous dissection and taking care not to damage the perforator we could get a good exposure even in cases operated by DHS. Thus, even in our cases operated by DHS the mean blood loss measured was also comparable to that of PFN.^{21,22}

Average time of union in all our 40 patients was about 16 weeks. There is some controversy regarding criteria for time of fracture union in different studies. Some use radiological union while some use radiological and clinical union. Assessment of early callus formation at fracture site and its subsequent progress was done with the help of ultrasonography in few cases. This was performed at subsequent intervals of 14th and 28th postoperative days. Neo-vascularization and soft callus in early phases and consolidation of callus was noted in follow up ultrasonographic study.^{23,24}

CONCLUSION

Proximal femoral nail (PFN) attempts to combine the advantages of a sliding hip screw with those of intramedullary fixation devices. Cases treated with PFN nail have shown easier rehabilitation, less blood loss, less surgical trauma, early mobilization and early rate of fracture union when compared to those cases treated with dynamic hip screw (DHS) and barrel plate and dynamic condylar screw and barrel plate as per observations in our study. With our sample study Proximal femoral nail (PFN) has given us encouraging results over conventional dynamic hip screw (DHS) and barrel plate and dynamic condylar screw and barrel plate. We recommend proximal femoral nail (PFN) as a better implant for the fixation of subtrochanteric fractures.

REFERENCES

1. Mahavir Jangir, Sudhir Kumar, Sitaram Jindal. A Prospective comparative study of outcome of management of unstable intertrochanteric fracture of femur with dynamic hip screw and proximal femoral nail anti rotation. International Journal of Contemporary

2. Ansari Moein et al. Soft tissue injury related to the choice of entry point in ante grade femoral nailing; pyriform fossa or greater trochanter tip. Injury 2015; 36:1337-1342.
3. Harris WH. Traumatic arthritis of the hip after dislocation and acetabular fractures: treatment by mold arthroplasty. An end-result study using a new method of result evaluation. J Bone Joint Surg Am. 1969; 51:737-55.
4. Shivraj. S. Konde, Santosh.S. Borkar, Abhijit Marathe, Rohit Shinde, Prashant Kamath. Dynamic hip screw and proximal femoral nail as a mode of surgical treatment in intertrochanteric fracture of femur in elderly patients. International Journal of Contemporary Medical Research 2018; 5:4-7.
5. Anne AK, Ekeland A, Odegard B et al. Gamma nail versus compression screw for trochanteric femoral fracture. Acta Orthop Scand 1994; 65: 127-130.
6. Larssoi S, Elloy M, Hansson LI. Fixation of unstable trochanteric hip fractures. A cadaver study comparing three different devices. Acta Orthop Scand. 1988; 59:658-63.
7. Kyle RF, Ellis TJ, Templeman DC. Surgical Treatment of Intertrochanteric Hip fractures with associated femoral neck fractures using a sliding hip screw. J Orthop Trauma. Jan 2005; 19, 1:1-4.
8. Omkarnath Gudapati, Srikanth S. The management of trochanteric fractures of hip using dynamic hip screw fixation. International Journal of Contemporary Medical Research 2016; 3:1946-1949.
9. Banan H, Al-Sabti A, Jimulia T, Hart AJ. The treatment of unstable, extracapsular hip fractures with the AO/ASIF proximal femoral nail (PFN)—our first 60 cases. Injury 2002; 33:401-5.
10. Nue Moller B, Lucht U, Grymer F, Bartholdy NJ. Early rehabilitation following osteosynthesis with the sliding hip screw for trochanteric fractures. Scand J Rehabil Med. 1985; 17:39-43.
11. Baumgaertner MR, Curtin SL, Lindskog DM. Intramedullary versus extramedullary fixation for the treatment of intertrochanteric hip fractures. Clin Orthop Relat Res 1998; 348:87-94.
12. Berman AT, Metzger PC, Bosacco SJ et al. Treatment of the subtrochanteric fractures with the compression hip nail: a review of 38 consecutive cases. Orthop Trans. 1979; 3:255.
13. Bergman GD, Winkist RA, Mayo KA, Hanson SE. Subtrochanteric fractures of the femur: fixation using the Zickel nail. J Bone Joint Surg (Am). 1987; 69: 1032-1040.
14. Gallangher JC, Melton LJ, Riggs BL et al. Epidemiology of fractures of the proximal femur in Rochester, Minnesota. Clinical Orthop 1980; 150:163-171.
15. Evans E. The treatment of trochanteric fractures of the femur. JBJS 1949; 31B 190-203.
16. SF Kumar, VK Bhasme, Akash Hosthota, Mayur Rabhadiya. Functional outcome of proximal femur fracture managed surgically using proximal femoral nail. International Journal of Contemporary Medical Research 2017; 4:22-24.
17. Broos PL, Reynders P. The use of the unreamed AO

- femoral Intramedullary nail with spiral blade in non pathologic fractures of the femur: experiences with eighty consecutive cases. *J Orthop Trauma* 2002; 16:150-4.
18. Boidin C, Seibert F, Fankhauser F et al. The proximal femoral nail (PFN)-A minimal invasive treatment of unstable proximal femoral fractures. A prospective study of 55 patients with a follow-up of 15 months. *Acta Orthop Scand* 2003; 74: 53-58.
 19. Zuckerman JD, *Comprehensive care of orthopaedic injuries in the elderly*, Baltimore: Urban and Schwarzenberg, 1990.
 20. Koval KJ, Zuckerman JD. Hip fractures: I. Overview and evaluation and treatment of femoral-neck fractures. *J Am Acad Orthop Surg*. 1994; 2:141e149.
 21. Baumgaertner MR, Curtin SL, Lindskog DM, Keggi JM. The value of Tip-Apex distance, in predicting failure of fixation of peritrochanteric fractures of the hip. *J Bone Joint Surg (Am)*. 1995; 77:1058-1064.
 22. Boyd HB, Griffin LL. Classification and treatment of trochanteric fractures. *Arch Surg*. 1949; 58:853.
 23. Butt MS, Krikler SJ, Nafie S, Ali MS. Comparison of dynamic hip screw and gamma nail: a prospective randomized controlled trail. *Injury* 1995; 26:615-8.
 24. Borens O et al. Long gamma nail in the treatment of subtrotrochanteric fractures. *Arch Orthop Trauma Surg* 2004; 124:443-7.

Source of Support: Nil; **Conflict of Interest:** None

Submitted: 20-09-2018; **Accepted:** 21-10-2018; **Published:** 02-11-2018