

# CT Anatomy of Paranasal Sinuses – Corelation with Clinical Sinusitis

Shephali S Pawar<sup>1</sup>, Saksham Bansal<sup>2</sup>

## ABSTRACT

**Introduction:** Coronal CT is a wonderful diagnostic tool for detailed evaluation of paranasal sinus anatomy. With the advent of functional endoscopic sinus surgery considerable attention has been directed towards the understanding of osteomeatal complex and its role in the causation of chronic sinusitis.

**Material and Methods:** A total number of 150 patients who came with signs and symptoms of sinusitis at a tertiary care hospital and referred to the department of radio-diagnosis for CT scanning of the paranasal sinus region were studied over a period of 18 months.

**Results:** In our study there were 52% males and 48% females. We found a multitude of anatomic variants of the sino-nasal cavities. A majority of patients in our study had presence of at least one variant, which suggests that the presence of anatomical variants is extremely common in the paranasal sinus region.

**Conclusions:** Prevalence of chronic/ recurrent sinusitis is clearly more in patients with anatomical variants. As some variations like Onodi cells and Haller cells may predispose patients to increased risk of intraoperative complications every patient undergoing invasive procedures like FESS must have a CT study prior to the surgery.

**Keywords:** PNS – Paranasal Sinus, CRS – Chronic Rhinosininitis, OMU – Osteomeatal Unit, CT – Computed Tomography, HRCT – High Resolution Computed Tomography, MRI – Magnetic Resonance Imaging, MDCT – Multi - Detector Computed Tomography, USG – Ultrasonography, EI – Ethmoidal Infundibulum, SMT – Secondary Middle Turbinate

## INTRODUCTION

Multiphase high resolution CT (HRCT) of the paranasal sinuses provides a precise and reliable preoperative roadmap for the endoscopic sinus surgeon. Currently CT scanning is the standard imaging in the evaluation of the paranasal sinuses. It gives an applied anatomical view of the region as well as the anatomical variants and thus optimizes the outcome of surgery in this region. In this study, we have studied the anatomy of paranasal sinuses and its associated variants using Multi-detector CT (MDCT) and have tried to find whether there is any significant correlation between the anatomical variants and sinusitis.<sup>1</sup>

Aims and objectives of our study were to study the anatomy of paranasal sinus region and associated variants using MDCT, to study the prevalence of anatomical variations of paranasal sinuses in patients with clinical sinusitis and to study the correlation between clinical sinusitis and variations in PNS anatomy.

## MATERIAL AND METHODS

After approval from the Ethical Committee of the hospital a cross sectional study of 150 patients who came with signs and symptoms of sinusitis at a tertiary care hospital and referred to the department of Radio-diagnosis for CT scanning of the paranasal sinus region was performed. The duration of the study was 18 months.

### Exclusion criteria

- Pregnant women.
- Patients with history of craniofacial trauma.
- Patients with history of sinonasal malignancy.
- Patients with past history of surgery in paranasal sinus region.
- Patients not willing to give consent for the study.

**Equipment:** Siemens Somatom Definition AS+ Configure (64x2) slice Multidetector CT scan machine was used to scan patients. A digitized lateral scanogram was first obtained. After checking the scanogram for positioning and presence of any artefacts unenhanced CT was performed with the scanning parameters as described below in axial plane.

**Patient position:** Supine

**Superior Extent:** Superior margin of frontal sinus

**Inferior Extent:** Superior Alveolar process of maxilla

**Scan direction:** Craniocaudal

**Collimation:** 128 x 0.6

**kVp:** 120 mAs: 50

**Rotation time:** 1.0 s **Pitch:** 0.8

Multiphase reconstructions were then done from the raw data in bony and soft tissue windows as follows

In all the cases, the existence of the variants was investigated.

## STATISTICAL ANALYSIS

An excel sheet was prepared with the data for all the 150 patients included in the study and statistical analysis was done using SPSS statistical software. The prevalence of individual sinusitis was also studied in each of the anatomical variants, irrespective of whether the sinusitis and variants are unilateral or bilateral in a particular case and p value was

<sup>1</sup>Professor and Head, <sup>2</sup>Resident, Department of Radio diagnosis, B J Government Medical College, Pune, Maharashtra India

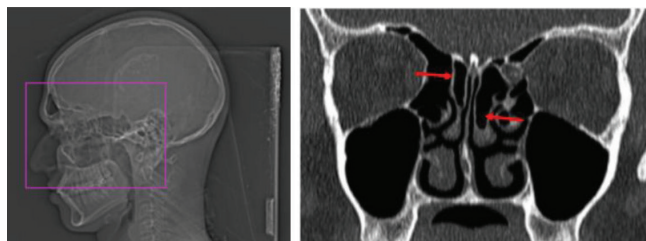
**Corresponding author:** Dr Shephali S Pawar, A-3/ 702, Kumar Pinnacle, Tadiwala Road, Pune, Maharashtra India

**How to cite this article:** Shephali S Pawar, Saksham Bansal. CT anatomy of paranasal sinuses – corelation with clinical sinusitis. International Journal of Contemporary Medical Research 2018;5(4):D1-D3.

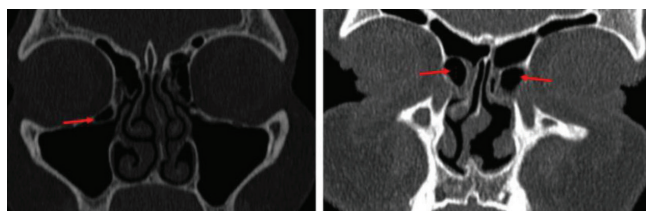
**DOI:** 10.21276/ijcmr.2018.5.4.13

Window	Bone	Soft tissue
Kernel	H70h Sharp	FR H10s very smooth
FOV	200 mm	200 mm
Slice thickness	1 mm	1 mm
Increment	0.7 mm	0.7 mm
Window Level (WL)	400	400
Window Width (WW)	2000	120

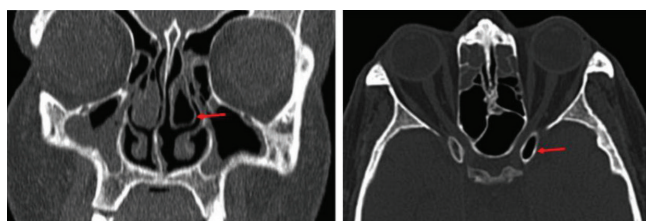**Table-1: Window**



**Figure-1:** Scannogram showing the planning for CT PNS; **Figure-2:** Coronal CT showing bilateral interlamellar cells of Grunwald



**Figure-3:** Coronal CT showing single Haller cell on right side; **Figure-4:** Coronal CT showing prominent Agger Nasi cells on both sides;



**Figure-5:** Showing concha bullosa on left side; **Figure-6:** Showing Onodi cells on left side

calculated using Chi square test.

## RESULTS

Maxillary sinuses were the most commonly involved amounting to 70% cases. This was followed by anterior ethmoid sinuses (50.6%). Deviated nasal septum was seen in 77% and was the most common variation followed by prominent Agger nasi cells (42%). Middle concha bullosa was seen in 51 patients (34%), Pneumatization of uncinata process, a rare anatomical variant was found in 2% patients and was unilateral in all cases (table-1) (figure 1-5).

There was no statistically significant association between the prevalence of maxillary, frontal, anterior ethmoid, posterior ethmoid and sphenoid sinusitis in any of the anatomical variants such as Concha Bullosa, DNS, Haller Cells, Onodi Cells, Prominent Agger Nasi Cells, Aerated Crista Galli, Accessory Maxillary Ostium, Paradoxical Middle Turbinate and Interlamellar Cells Of Grunwald.

## DISCUSSION

Of all the variants we came across in our study DNS was the most common (77%). These findings are similar to the study of Shpilberg et al in which the incidence was 61.4%.<sup>1</sup>

DNS or bony spur causes sinusitis as it results in a decrease in the critical area of the osteomeatal unit.

Concha bullosa or pneumatization of the bulbous portion of middle turbinate has been implicated as a possible etiological factor in the causation of recurrent chronic rhinosinusitis in a lot of studies likely due to its postulated negative influence on paranasal sinus ventilation and mucociliary clearance in the middle meatus region.<sup>2</sup> The prevalence of 34% in our study was comparable with the studies of Zinreich S et al (36%), Liu et al. (34.8%), Azila et al. (40.8%) and Suri et al. (41.5%).<sup>3</sup>

Paradoxical middle turbinate i.e. bent in the reverse direction may lead to impingement of the middle meatus and thus to sinusitis. In our study it was found in (11.3%) cases and was close to the 10% incidence described by Peres et al.<sup>3</sup>

Haller's cells were seen in (10%). Kennedy and Zinreich, 1988 reported a prevalence of 10% as well.<sup>4</sup>

Prominent Agger nasi cells were present in (42%) in our study and was the second most common anatomical variation in our study after deviated nasal septum. It was unilateral in (30%) and bilateral in (12%). This compares well with the 40%, 47% figures obtained by Dua et al.<sup>5</sup>

Onodi cells were found in 6% cases and the incidence was similar to other studies. Similarly, the pneumatized uncinata process a rare variant was found in 2% cases in our study.

Mucosal thickening was seen in all our patients. More than one sinus were involved in 76% cases. Pan sinusitis was seen in 10% cases.

## CONCLUSION

CT helps in assessing the extent of sinusitis and to know the presence of certain critical anatomical variants. Awareness of such variations may help in making surgical decisions beforehand and avoiding possible complications and hence improve success of management strategies. Further, it evaluates the osteomeatal complex anatomy which is not possible with plain radiographs. However, these advantages come at a cost of exposure to radiation. Hence, we feel that CT scan of the paranasal sinuses should be advised for every patient who will undergo invasive procedures like FESS. All the same, with improved imaging techniques, MRI is emerging as a strong contender against CT in evaluation of PNS pathologies, due to advantages like lack of radiation and superior soft tissue resolution.

## REFERENCES

1. Shpilberg KA, Daniel SC, Doshi AH, Lawson W, Som PM. CT of Anatomic Variants of the Paranasal Sinuses and Nasal Cavity: Poor Correlation With Radiologically Significant Rhinosinusitis but Importance in Surgical Planning. *Am J Roentgenol* 2015;204(6):1255–60.
2. Zinreich SJ, Kennedy DW, Rosenbaum AE, Gayler BW, Kumar AJ, Stammberger H. Paranasal sinuses: CT imaging requirements for endoscopic surgery.

- Radiology 1987;163(3):769–75.
3. Azila A, Irfan M, Rohaizan Y, Shamim AK. The Prevalence of Anatomical Variations in Osteomeatal Unit in Patients with Chronic Rhinosinusitis. *Med J Malaysia* 2011;66(3):191–4.
  4. Kennedy DW, Zinreich SJ. The Functional Endoscopic Approach to Inflammatory Sinus Disease: Current Perspectives and Technique Modifications. *Am J Rhinol* 1988;2(3):89–96.
  5. Dua K, Chopra H, Khurana A, Munjal M. CT scan variations in chronic sinusitis. *Indian J Radiol Imaging*. 2005;15:315.

**Source of Support:** Nil; **Conflict of Interest:** None

**Submitted:** 19-03-2018; **Accepted:** 18-04-2018; **Published:** 02-05-2018