

Correlation between Automated Perimetry and Magnetic Resonance Imaging (MRI) in Neuro-Ophthalmic Disorders (Supratentorial Space Occupying Lesions)

Seema Mane¹, Avinash Ingole², Nikunj Patel¹, Aditi Agarwal¹, Swapnil Rathod¹

ABSTRACT

Introduction: Space occupying lesions of the brain manifest usually with visual field defects with impairment of vision and papilloedema. Defects in the Visual field provide requisite information for locating the anatomical site and progression of supratentorial space occupying lesions (SOL) affecting visual pathway. Clinical correlation between automated perimetry and Magnetic resonance imaging (MRI) is vital for anticipation and management of these patients.

Material and Methods: This comparative prospective study was carried out on 50 patients with supratentorial SOLs in tertiary care hospital. Visual fields were performed on Humphrey's automated perimeter using 30-2 SITA standard strategy which were again repeated at 6 and 12 months after completing treatment. Correlation of visual fields with MRI was done to diagnose and localize the lesion.

Results: Homonymous hemianopia was seen in 30% of patients followed by bitemporal hemianopia in 24% of patients. 54.54% patients with chiasmal lesions showed bitemporal hemianopia. Most patients were having pituitary adenoma. Central/paracentral scotomas were found in 15.9%, concentric field contraction in 10% and quadrantanopia was observed in 8% patients. Normal fields were present in 12% of patients. Perimetry could correlate location of lesions in 31 (62%) patients as compared to MRI 50 patients (100%). Out of 20 patients of chiasmal SOLs, 5 patients showed normal visual fields and out of remaining 15 patients, 11 (73.33%) patients showed improvement in visual field after treatment.

Conclusions: Automated perimetry is an excellent tool for early diagnosis of patients with supratentorial SOLs. The correlation of field defects and MRI is helpful in management and follow-up of patients affecting visual pathway.

Keywords: Automated Perimetry, Supratentorial, Space Occupying Lesions (SOL), Magnetic Resonance Imaging

traverses the entire brain anteroposteriorly from retina to the occipital cortex. The anterior pathway is related to the vascular and bony structures at the base of the skull. The posterior pathway is closely related to the ventricular system. Defects in visual pathway can become a great localizer of supratentorial lesions. Visual field assessment along with complete neurological examination can thus localize site of the lesion. The loss of sensitivity at various visual field locations serves as a noninvasive marker for identifying pathology or dysfunction of the visual pathways. The ability of perimetry to provide helpful clinical information has been responsible for its long-term use as a diagnostic procedure. Perhaps the most important role sub served by perimetry is the ability to find afferent visual pathway loss that may not be apparent to the patient.¹ There are number of reports of intracranial space occupying lesions in relation to visual pathway with characteristic field defects, but there are very few reports of distant supratentorial lesions producing field defect. In this study, various types of visual field defects are studied in patients with supratentorial space occupying lesions excluding hemorrhages and comparison between topographical locations of these lesions as assessed by MRI is made with that of automated perimetry. The current study was taken to localize the site of lesion and to monitor progression in patients with supratentorial space occupying lesions using automated perimetry. Correlation between automated perimetry and magnetic resonance imaging (MRI) was done in these patients.

MATERIAL AND METHODS

A prospective study was conducted on 50 patients visiting ophthalmology outpatient department at a tertiary care hospital after due approval of the Institutional Ethics Committee. Patients above 10 years of age and of both sexes with supratentorial space occupying lesion and who are able to understand and perform automated perimetry properly

INTRODUCTION

A space occupying lesion of the brain has its effect as they expand in volume and displace adjacent neural structures. Aetiologically they are divided as primary or secondary due to metastasis from distant organs. Ophthalmological manifestations of these lesions include ocular signs in the form of visual impairment, ocular motility disorder, papilloedema and visual field defects. These are due to compression effect with focal neurological deficit. Among these, visual field defects can provide information about both the likely anatomic locus and disease processes for afferent system abnormalities and it remains a vital part of the neuro-ophthalmologic evaluation.¹ The sensory visual system

¹Senior Resident, ²Associate Professor, Department of Ophthalmology, B.Y.L Nair Hospital and TNMC, India

Corresponding author: Dr Avinash Ingole, Department of Ophthalmology, OPD – 10, OPD Building, 2ndfloor, BYL Nair Hospital, Mumbai Central – 400008, Mumbai, Maharashtra, India

How to cite this article: Seema Mane, Avinash Ingole, Nikunj Patel, Aditi Agarwal, Swapnil Rathod. Correlation between automated perimetry and magnetic resonance imaging (MRI) in neuro-ophthalmic disorders (supratentorial space occupying lesions). International Journal of Contemporary Medical Research 2017;4 (7):1595-1598.

were included in this study over 20 months period. Patients who could not perform perimetry or found it difficult to perform it due to anterior or posterior segment pathologies and patients with any systemic conditions leading to inability to respond to any kind of stimuli (Visual, auditory, verbal, etc) were excluded from the study. Patients with supratentorial hematomas, cerebrovascular accidents were also excluded from study. Patients with posterior segment abnormality in eye like vitreous or retinal detachment, dystrophy, intraocular inflammation, supratentorial hematomas, cerebrovascular accidents were also excluded from study. The aim of the study was to localize the site of lesion in patients with supratentorial space occupying lesions using automated perimetry and to monitor progression of supratentorial space occupying lesions. Also, to assess correlation between automated perimetry and magnetic resonance imaging (MRI) for localization of lesions. Consent of every patient was recorded in the vernacular language understood by the patient and the purpose of the study was explained to every patient. Complete ophthalmological and neurological (performed by neurologists) evaluation was done. All patients were subjected to MRI brain examination on 1.5 TESLA, 8 Channel Magnetic Resonance Imaging equipment to locate, to determine size, nature and progression of space occupying lesions. Evaluation of visual fields using automated perimetry (Humphrey’s visual field analyzer using 30-2 SITA standard strategy) was done with Humphrey field analyzer using a 4 mm² Goldmann size III stimulus. The 30-2 SITA standard strategy was used. Each patient underwent VF tests twice on separate days and the more reliable result was selected for statistical analysis. The reliability criteria used were fixation losses, false positive and false negative errors less than 20%. VF examinations were considered abnormal if pattern standard deviation (PSD) or glaucoma hemifield test was abnormal. Based on either of the following criteria quadrantanopia was defined. A. Depression of thresholds by 5 dB or more, in three or more contiguous points adjacent to the vertical meridian in the involved quadrant as compared to their mirror image points across the vertical meridian. B. The pattern deviation plot showed three or more points adjacent to the vertical meridian in the involved quadrant depressed to the 1% probability level with normal mirror image points across the vertical meridian. For the diagnosis of hemianopia, the diagnostic criteria for quadrantanopia had

to be applicable to both quadrants comprising the hemifield. To quantify the severity of VF defects, results of the mean deviation (MD) and PSD of both eyes were used. All patients were evaluated after medical or surgical treatment at 6 months and after one year of treatment. On follow up complete ocular examination including visual fields was done.

STATISTICAL ANALYSIS

Data was statistically described in terms of mean (±SD), frequencies (number of cases) and percentages where appropriate. MRI was considered the gold standard in detection and localizing intracranial supratentorial tumor. Sensitivity of automated perimetry was calculated based on the number of true positives detected and was calculated for each type of supratentorial tumor.

RESULTS

In our study, 44% patients belonged to the age group of 21-40 years and male to female ratio was 1.27:1. Headache was the most common presenting symptom (74%), followed by diminution of vision (DOV) (70%), seizures (36%) and other symptoms (44%) which included galactorrhea, menstrual disturbances, growth spurt, loss of consciousness, diplopia, nausea and vomiting. Best corrected visual acuity in the range of 6/6-6/12 was seen in 35 (70%) right eyes and 36 (72%) left eyes. 5 patients had unilateral decreased vision of less than 6/60 to the extent of inaccurate perception of light, which was primarily due to optic atrophy. Preoperative automated perimetry with Humphrey field analyzer using 30-2 threshold program showed homonymous hemianopia in majority of patients 15 (30%) followed by bitemporal hemianopia seen in 12 (24%) patients due to large number of cases of pituitary adenoma. Central/paracentral scotomas were found in 7 (15.9%) patients and concentric field contraction in 5 (10%). Quadrantopia was observed in 8% (Table 1). All patients with temperoparietal lesions showed classical homonymous hemianopia. Normal fields were present in 6 (12%) of patients. Neuroimaging by MRI revealed the most common site of SOLs to be chiasmal 22 (44%). Distribution of other SOLs was frontal 10 (20%), frontoparietal 7 (15.9%), temporal 5 (11.4%), temporoparietal 3 (6.8%), and parietal 3 (6.8%) (Table 1). Perimetry could correlate location of lesions in 31 (62%) patients versus all 50 (100%) patients being accurately diagnosed by MRI (Table 2). We could

Sr No	Visual field defect	frontal	Frontoparietal	Temporal	Temporoparietal	Parietal	Chiasmal	Total
1	Homonymous hemianopia	1	5	3	3	1	2	15
2	Bitemporal hemianopia	0	0	0	0	0	12	12
3	quadrantopia	0	0	1(Sup)	0	2(Inf)	1(Sup)	4
4	Concentric contraction	4	1	0	0	0	0	5
5	Central / paracentral scotomas	4	1	0	0	0	2	7
6	Arcuate scotoma	1	0	0	0	0	0	1
9	Normal field	0	0	1	0	0	5	6
	Total	10 (20%)	7 (15.9%)	5 (11.4%)	3 (6.8%)	3 (6.8%)	22 (44%)	50

Table-1: Location of SOL on MRI and Visual field defects

perform visual field analysis in both eyes of 45 patients while only one eye could be assessed of 5 patients as the other eye was having vision less than 6/60 secondary to optic atrophy. Out of the 50 patients we had follow up of 43 patients. Out of 20 patients of chiasmal space occupying lesions 11 (73.33%) patients showed improvement in visual field after treatment (Table 3, Figure-1).

DISCUSSION

We studied 50 patients with supratentorial space occupying lesions to assess the correlation between visual field defect and MRI regarding the site of lesion. Only supratentorial space occupying lesions were included in this study, as previous studies showed that meningiomas, gliomas, pituitary adenomas,metastases and acoustic neuromas account for 95% of all brain tumors.² In adults, two thirds of primary brain tumors are supratentorial, but in children, two thirds of brain tumors are infratentorial.³ Among all 50 patients of supratentorial space occupying lesions 22 patients were of chiasmal lesions only. Other studies have shown that pituitary tumors account for 9 – 12% of primary brain

tumors, making them the third most common primary brain tumors in adults following meningiomas and the gliomas. Pituitary adenomas present more commonly due to hormonal imbalance leading to various symptoms.³ In this prospective study automated perimetry (30-2 SITA fast strategy) was used to test visual fields,and confirmation of pathology was done using MRI brain. In a study by Szatmáry G et al, they compared SITA Fast strategy with Goldmann perimetry in the detection and characterization of VF defects in neuro-ophthalmic practice⁴,They showed that the SITA Fast strategy was useful in detection and quantification of central VF defects, and might be preferable to Goldmann perimetry. In patients with neuro-ophthalmology symptoms,SITA strategy shortens testing time for the standard Humphrey strategy but does not seem to affect variability.⁵ Out of 50 patients, static perimetry showed homonymous hemianopia in 15 (30%) patients followed by 12 (24%) patients showing bitemporal hemianopia due to large number of pituitary adenomas. Central/paracentral scotomas were seen in 7 (15.9%) patients, while 12% of patients had normal visual fields. S Sood et al found similar results.⁶ Seven out of 10 patients of frontal lobe tumors could do visual fields in both eyes while three patients had vision less than 6/60 in one eye secondary to optic atrophy. 8 out of 10 patients had typical defects like, scotomas, concentric field contraction. Ecker AD et al have also shown these defects as typical defects in frontal space occupying lesions.⁷ Sixty percent of patients with space occupying lesions involving temporal lobe showed homonymous hemianopia, coinciding with results of Edmund et al⁸ which showed 56% of patients having homonymous hemianopia. Huber⁹ series showing 66% patients having homonymous hemianopia ,but Classical field defect of superior quadrantanopia was seen in only 1 patient with temporal lobe lesion. In our study patients with parietal lobe tumors showed homonymous hemianopia in 33.33% patients. Huber's⁹ showed 50% patients with homonymous

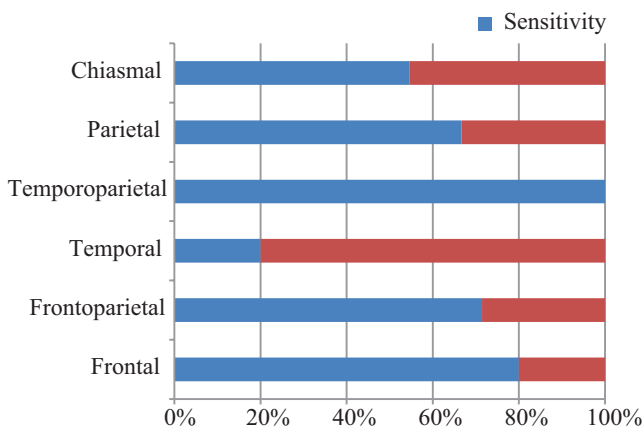


Figure-1: Sensitivity of perimetry in detecting intracranial tumours.

Sr. No.	Location of tumor	Total number of patients (All detected by MRI)	Detection by Perimetry (No.of patients)	Sensitivity
1	Frontal	10	8	80%
2	Frontoparietal	7	5	71.42%
3	Temporal	5	1	20%
4	Temperoparital	3	3	100%
5	Parietal	3	2	66.66%
6	Chiasmal	22	12	54.54%
Total		50	31	62%

Table-2: Correlation of lesions on MRI with automated perimetry.

Site of lesions	Improved fields	Worsened fields	No changes in fields	Total no. of patients
Frontal	2	2	3	7
Frontoparital	4	2	-	6
Temporal	2	-	2	4
Temperoparital	1	2	-	3
Parital	2	-	1	3
Chiasmal	11	-	9	20
Total patients	22	6	15	43

Table-3: Correlation of visual fields with MRI on follow up

hemianopia, while 66.66% patients showed classical defect of inferior quadrantanopia in parietal lobe tumours. In chiasmal lesions (most were pituitary macro adenomas), classical field defects of bitemporal hemianopia were seen in 12 (54.55%) patients. It differs minimally from another study showing 69% defect. This could be because in this study tumors other than pituitary tumors are also included (Gregorious FK).¹⁰ Among chiasmal tumors 77.27% patients of pituitary adenoma had abnormal fields while 22.72% had normal fields, coinciding with the study of Jung Pil Lee, In Won Park, and Yun Suk Chung¹¹ whose values showed 74% with abnormal and remaining with normal fields. Out of fifty patients static perimetry showed visual field defects in 31 as compared to 100% positivity in MRI. Five patients with chiasmal lesion and one with temporal lobe lesion had normal visual field. The reason being the SOL lesions being small to have compressive effect on adjacent visual pathway. Out of 50 patients in this study 43 patients could follow up. (Table 3). Out of 20 patients of chiasmal space occupying lesions, 5 patients showed normal visual fields, and out of remaining 15 patients, 11 (73.33%) patients showed improvement in visual field after treatment. This had coincided with 70-75% of improvement in visual fields shown in other studies.¹³⁻¹⁵

CONCLUSION

In our study, automated perimetry has shown valuable contribution in localizing supratentorial space occupying tumors when combined with MRI. Automated perimetry also can be important prognostic tool, to know response to treatment as field defects improve once compression is relieved, to know progression of disease, as serial fields help in comparing recent fields with old ones. However, despite the advantages, automated perimetry cannot replace MRI in the management of supratentorial space occupying lesions. It acts as an adjunct to MRI in treatment of supratentorial space occupying tumors.

REFERENCES

1. Walsh and Hoyt's Clinical Neuro-Ophthalmology, 6th Edition (Miller, Neil R.; Newman, Nancy J.) 2005 Lippincott Williams and Wilkins
2. Trobe JD, Acosta PC, Krischer JP, Trick GL. Confrontation visual field techniques in the detection of anterior visual pathway lesions. *Ann Neurol*. 1981; 10:28-34.
3. ABTA (American Brain Tumor Association) pituitary tumors-2008
4. Szatmáry G, Biousse V, Newman NJ. Can Swedish interactive thresholding algorithm fast perimetry be used as an alternative to goldmannperimetry in neuro-ophthalmic practice? *Arch Ophthalmol*. 2002;120:1162-1173.
5. Bengtsson B, Olsson J, Heijl A, Rootzén H. A new generation of algorithms for computerized threshold perimetry, SITA. *Acta Ophthalmol Scand*. 1997;75:368-375.
6. S. Sood, N.K. Sharma, M. Nada, A. Dutt, R.C. Nagpal. Correlation Between CT Scan and Automated Perimetry in Supratentorial Tumors *Neurol India* 2002;50:158-61.

7. Ecker AD. Concentric contraction of visual fields associated with tumor of the frontal lobe. *Mayo Clin Proc*. 1937;12:679-682.
8. Edmund J. Visual disturbances associated with gliomas of the temporal and occipital lobe. *Acta Psychiatr Neurol*. 1954;29:291-310.
9. Huber A. *Eye Signs and Symptoms in Brain Tumors* (Blodi FC, editor and translator). Edition 3. St Louis, CV Mosby, 1976.
10. Gregorious FK, Helper RS, Stern WE. Loss and recovery of vision with suprasellarmeningiomas. *J Neurosurg*. 1975;42:69-74.
11. The Volume of Tumor Mass and Visual Field Defect in Patients with Pituitary Macroadenoma (Jung Pil Lee, In Won Park, and Yun Suk Chung)
12. Martin Boglind LM. Computer assisted interpretation of resolution visual fields from patients with chiasmal and retrochiasmal lesions. *Ophthalmologica*. 1993;207:148-154.
13. Findlay G, McFadzean RM, Teasdale G. Recovery of vision following treatment of pituitary tumours: Application of a new system of assessment to patients treated by transsphenoidal operation. *Acta Neurochirurg*. 1983;68:175-186.
14. Kahn SE, Miller JL. Rapid resolution of visual field defects and reduction in macroprolactinoma size with bromocriptine therapy: A case report. *S Afr Med J*. 1982;62:696-699.
15. Kerrison JB, Lynn M, Baer C, et al. Stages of improvement in visual fields following pituitary tumor resection. *Am J Ophthalmol*. 2000;130:813-820.

Source of Support: Nil; **Conflict of Interest:** None

Submitted: 07-07-2017; **Accepted:** 27-07-2017; **Published:** 15-08-2017