

A Study of a Diagnostic Dilemma: Abdominal Cocoon

Singla Mamta¹, Iyengar Madhavan², Attarde Niket³, Zea Md. Iqbal⁴, Singla Sanjeev⁵, Singla Sundeep⁶

ABSTRACT

Introduction: Abdominal tuberculosis is an important cause of recurrent subacute intestinal obstruction. Abdominal cocoon is one of the rare presentations which is usually diagnosed intraoperatively. Study aimed to find incidence of abdominal cocoon secondary to abdominal koch's in endemic area.

Material and methods: In the prospective descriptive study conducted from December 2014 to August 16 over a period of 20 months with a follow up of 6 to 12 months and all patients suspected of having isolated abdominal tuberculosis were included.

Results: Of all cases of abdominal Koch's almost 53% cases needed operative intervention, 9.26% of these presented with abdominal cocoon. 80% of the cocoon cases were detected preoperatively on CECT scanning of the abdomen.

Conclusion: Abdominal cocoon is not that uncommon especially in an endemic region. A high degree of suspicion can help identify cocoon formations early. Conservative surgery is the best way forward with abdominal cocoon. Greater awareness among practitioners in endemic region will lead to early detection and lower morbidity for the patients.

Keywords: Abdominal cocoon, CT scan, Abdominal tuberculosis

INTRODUCTION

Tuberculosis is a life threatening disease which can virtually affect any organ system of the body. It is caused by aerobic bacteria mycobacterium tuberculosis. Pulmonary tuberculosis is the most common form, from which it can get disseminated into other parts of the body.^{1,2} Abdominal tuberculosis is the 6th commonest extrapulmonary TB form after lymphatic, genitourinary, bone and joint, miliary and meningeal tuberculosis. It can involve any part of the gastrointestinal tract, but a majority of the lesions occur in the ileocaecal region.^{3,4} Intestinal TB can present as an acute or a chronic illness. The host's immune system influences the pattern of lesions. It can present in 4 ways.

Tubercular lymphadenopathy 2) Peritoneal tuberculosis 3) Visceral tuberculosis 4) Gastrointestinal tuberculosis⁵

Intestinal obstruction is commonly encountered surgical emergency and one of the most common causes of obstruction is abdominal tuberculosis. It accounts for 3-20% in India and attributed to strictures and adhesion bands. Abdominal cocoon is an exceptionally rare cause of intestinal obstruction which is characterized by the encasement of variable length of small intestine by a fibrocollagenic cocoon like sac.⁶⁻⁹ Hence it is important in identifying these lesions with high index of suspicion especially in endemic region. Accurate diagnosis of this rare cause is challenging and seldom made preoperatively and therefore usually made at laparotomy. It can also be cause of serious morbidity and mortality. Study aimed to find incidence of abdominal cocoon secondary to abdominal koch's in endemic area.

MATERIAL AND METHODS

A prospective descriptive study was carried out in our institution from December 2014 to August 2016 and all cases of intestinal obstruction were studied to search for diagnosis of abdominal tuberculosis. Patients aged between 20 years to 60 years were included in this study, who had strong suspicion of abdominal tuberculosis, abdominal pain of long duration, malaise, evening rise fever, weight loss, loose stools of prolonged duration. All patients with suspicious symptoms underwent evaluation for complete blood count, fasting ESR, chest x-ray to rule out pulmonary koch's. Abdominal USG and CT scan were done where appropriate. Mantoux testing was done in all cases. All cases which responded to anti tubercular treatment that was started empirically for abdominal symptoms were also included. Patients not responding to conservative treatment were explored those with intraoperative findings suspicious of tuberculosis like tubercles, ascitis, mesenteric lymphadenitis, fibrous bands and intestinal strictures in previously unoperated patients. The intraoperative findings were confirmed by histopathology. A total of 102 cases of acute and subacute obstruction secondary to abdominal tuberculosis were encountered. All patients were from poor socioeconomic status. 54 cases needed surgery while the rest were treated conservatively. Patients were followed for an average period of 6 to 12 months. Patients lost during treatment or investigations were not included. Patients having concurrently active tuberculosis of other systems were excluded from the study. Informed consent of patient were taken.

STATISTICAL ANALYSIS

Microsoft office 2007 was used for the statistical analysis. Descriptive statistics like mean and percentages were used for the interpretation of data.

RESULTS

Out of 54 cases explored, total five cases presented with abdominal cocoon formation as the cause of obstruction which is about 9.26% of abdominal TB patients operated and 4.9% of all cases. All five presented with features of subacute obstruction on more than one occasions and were successfully managed conservatively on all previous occasions. All had normal total leukocyte counts, ESR, protein and albumin levels at the time

¹Associate Professor, ²Professor, ³Assistant Professor, ⁴Associate Professor, Muzaffarnagar Medical College, Muzaffarnagar, ⁵Associate Professor, BPS Government Medical College, Sonipat, ⁶Associate Professor, Raj Shree Institute of Medical Sciences, Bareilly, India

Corresponding author: Mamta Singla, H.No.44, Sector – 6, Panchkula, Haryana, India

How to cite this article: Singla Mamta, Iyengar Madhavan, Attarde Niket, Zea Md. Iqbal, Singla Sanjeev, Singla Sundeep. A study of a diagnostic dilemma: abdominal cocoon. International Journal of Contemporary Medical Research 2017;4(4):812-814.

of current presentations. Four of them could be diagnosed by established radiological features on CT scan (figure 1), one was diagnosed on laparotomy ie 80% were diagnosed with CT

On exploration, four were found to have whole of jejunum and ileum encased in a fibrous capsule while the fifth had about 90% of the small bowel encased in the capsule. Three had multiple tubercles in the peritoneum but all showed enlarged mesenteric lymphnodes.

All patients underwent excision of sac and other adhesions intraoperatively without any need for bowel resection. Lymphnode biopsy was done in all cases. All patients showed granulomas with epithelioid cells. Postoperatively they were started on anti tubercular therapy and responded well to it with resolution of subacute obstructive symptoms.

DISCUSSION

Very rarely does a surgeon encounter during exploratory laprotomy for intestinal obstruction a condition where the entire or in part, small bowel is encased within a thick fibrocollagenous membrane, as though it were in a cocoon. 'Abdominal cocoon' term was first described by Foo⁶ in 1978. Description of cocoon is first documented by Owtschinnikow in 1907 who labeled it as Peritonitis chronic fibrosa incapsulata.¹⁰

We now consider both terms under Sclerosing encapsulating peritonitis (SEP). The exact etiology and pathogenesis of SEP is still unknown. It has been hypothesized that increased deposition of fibrin on peritoneum, after the release of fibrogenic cytokines converts fibrinous adhesions to generalized fibrosis.¹¹ SEP can be primary or secondary. Primary or idiopathic is considered to be more common, seen in adolescent females especially in tropics and subtropical countries. Once thought to be due to subclinical primary viral peritonitis or as an immunological reaction to gynaecological infections or due to retrograde menstruation; however, doubts remain due to reports of occurrence in children, postmenopausal females, and males.¹²⁻¹⁴

The secondary form of SEP has been reported in abdominal tuberculosis¹³⁻¹⁶, liver cirrhosis, gastrointestinal malignancy¹⁷, peritoneal chemotherapy¹⁸, continuous ambulatory peritoneal dialysis (CAPD), and automated peritoneal dialysis (APD). It has also been noted in patients who had previous abdominal surgery, β -blocker practolol intake, liver transplant, sarcoidosis, systemic lupus erythematosus (SLE), recurrent peritonitis, and ventriculoperitoneal and peritoneovenous shunts.

Yip and Lee¹⁹ listed 4 main clinical features that had identified cocoon preoperatively

- Occurrence in relatively young girls without obvious cause of intestinal obstruction
- History of similar episodes which resolved spontaneously
- A presentation with abdominal pain and vomiting but rarely the four cardinal symptoms of intestinal obstruction.
- A presentation of nontender soft mass on abdominal palpation.

All our five cases came with recurrent attacks of SBO. Preoperative diagnosis of SEP is very difficult mainly due to nonspecific clinical symptoms of SEP and due to its reduced awareness of condition. That is why majority of the abdominal cocoon cases are reported in past have been incidental findings during surgery.¹⁵

Radiological features are also non specific. CT is of more specific

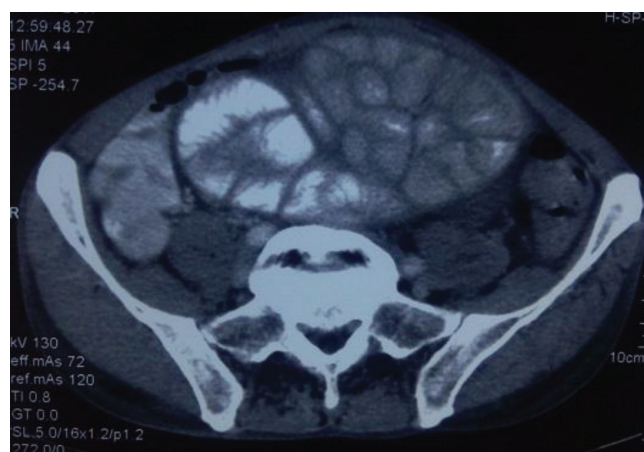

Figure-1: CT showing encapsulating fibrous membrane surrounding intestinal loops

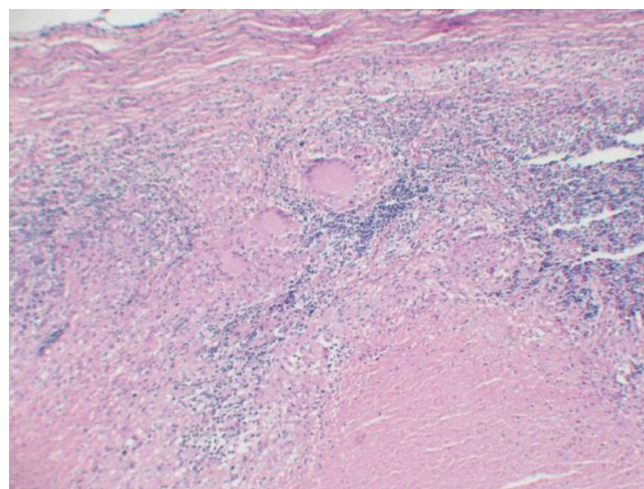


Figure-2: HPE of mesenteric lymphnode showing granuloma.

diagnostic value and has helped diagnosed the condition with considerable ease. Classic 'cauliflower appearance', concertina pattern on barium meal is seldom seen and may provide a clue towards diagnosis. But computed tomography and MR are reasonably good at diagnosing the entity by demonstrating encapsulating fibrous membrane as seen in our 4 cases. It has been reported that sensitivity of CT to depict the cause of SBO is 73 to 95%.²⁰ The treatment of cocoon is controversial. Medical management with corticosteroids and tamoxifen have shown sporadic favourable reasons, but best results are seen with surgery. Approach to surgery should be conservative. It consists of dividing the membrane and associated adhesions either by laparotomy or laparoscopically. There are more chances of iatrogenic complications while stripping of membrane from small bowel. Thus extensive surgery should be avoided. In our series, 3cases had tubercles on peritoneum and all four had enlarged mesenteric lymphnode. Diagnostic laparoscopy may be helpful in diagnosing this condition, we have not tried in our cases. In true cocoon, interloop adhesions are rarely seen as in our series. Postoperative period was uneventfull in all cases. Though postoperative complications have been reported such as enterocutaneous fistulae, anastomotic leak²¹, enterohepatic encephalopathy²², multiorgan failure after 7 months of surgery.¹⁷ All 5 cases were given antitubercular therapy for 6 months and responded well.

CONCLUSION

Abdominal cocoon is not an uncommon cause of surgical emergency in the region with high prevalence of TB and patient presented with vague, nonspecific, recurrent symptoms of SBO. Among all radiological investigation CT shows high sensitivity. Patient should be treated by surgery and if positive for AFB start ATT postoperatively. Poverty, illiteracy, non specific symptoms and poor understanding of disease are some reasons of delayed diagnosis and increased mortality due to abdominal TB.

REFERENCES

1. K P. Park's textbook of Preventive and social medicine 19th edition india: Banarsidas Bhanot; 2007.
2. Kapoor VK. Abdominal tuberculosis: the Indian contribution. Indian journal of Gastroenterology. 1998; 17:141-47.
3. Chang VH Lim KS. Gastrointestinal tuberculosis. Singapore Med J. 2009;50:638-645.
4. Dasgupta A, Singh N, Bhatia A. abdominal tuberculosis: ahistopathological study with special reference to intestinal perforation and mesenteric vasculopathy. indian J Pathology microbiol. 2010;53:418-423.
5. Debi V Ravishankar V, Prasad KK, Sinha SK, Sharma AK. abdominal tuberculosis of the gastrointestinal tract:revisted. world journal of gastroenterol. 2014;20:14832-14840.
6. Foo KT, Ng KC, Raulff A, Foong WC, Sinniah RC. unusual small intestinal obstruction in adolescent girls:the abdominal cocoon. Br J of Surgery. 1978;65:427-30.
7. Sahoo SP,Gangopadhyay AN, Gupta DK, Gopal SC, Sharma SP, Dash RN. abdominal cocoon in children: a report of four cases. J pedia surg. 1996;31:987-8.
8. Yoon YW, Chung JP, Park HJ, Cho HG, Choncy, Park IS, Kim KW, Lee HD. a case of abdominal cocoon. J korean med sci. 1995;10:220-5.
9. Wig JD, Goenka MK,Nagi B, Vaphai K. Abdominal cocoon in male: a rare cause of intestinal obstruction. Tropical gastroenterol. 1995;16:31-3.
10. Owtschinnikow PJ. Peritonitis chronica fibrosa encapsulata. Langenbecks Archiv fur Klinische Chirurgie vereinigt mit Deutsche Zeitschrift fur Chirurgie. 1907;83:623-634.
11. D, Jain B, Agrawal J, Gupta A, Agrawal V. Abdominal cocoon: clinical presentation, diagnosis and management. J Gastrointestinal surgery. 2009;13:1160-2.
12. Xu Ping, Chen L Hua, Li You-Ming. idiopathic sclerosing encapsulating peritonitis or abdominal cocoon:a report of 5 cases. world journal of emergency surg. 2006;p. 1:8.
13. Kaushik R, Punia RPS, Mohan H, AttriAK. tuberculous abdominal cocoon- areport of 6 cases and review of literature. W J Emerg Surg. 2006;1:18.
14. S. Laloo D Krishna, J Maharaj. Abdominal cocoon associated with tuberculous pelvic inflammatory disease. British Journal of Radiology. 2002;75:174-176.
15. A. Gadodia, R Sharma, N Jeyaseelan. Tuberculous abdominal cocoon. The American Journal of Tropical Medicine and Hygiene. 2011;84:1-2.
16. Rastogi R. Abdominal cocoon secondary to tuberculosis. Saudi Journal of Gastroenterology. 2008;14:139-141.
17. Ibrahim NA, Oludara MA. abdominal cocoon in adolescent male patient. tropical doctor. 2009;39:254-56.
18. Carbonel F, BarrieL, Beaugerie L etal. sclerosing peritonitis, a series of 10 cases and review of literature. gastroenterologie clinique et biologique. 1995;19:876-82.
19. Yip FWK, Lee SH. the abdominal cocoon. australian and

new zealand journal of surgery. 1992;62:638-42.

20. Burkill GJ, Bell JR, Healy JC. the utility of computed tomography in acute small bowel obstruction. clin radiol. 2001;56:350-9.
21. Tannoury JN, Abboud BN. idiopathic sclerosing peritonitis: abdominal cocoon. world J Gastroenterol. 2012;18:1999-2004.
22. Mohd Zain Sohail, Shumail Hasan, Benan Dala Ali, Shahanoor Ali Hashmi MA. multiple abdominal cocoon: an unusual presentation of intestinal obstruction and a diagnostic deliema. case reports in surgery. 2015;p. 282368.

Source of Support: Nil; **Conflict of Interest:** None

Submitted: 22-03-2017; **Accepted:** 20-04-2017; **Published:** 01-05-2017