

Clinical Profile of Patients with Brain Metastasis- A Single Institutional Retrospective Study

Manashi Ghosh¹, Kaustav Mandal², Vinita Trivedi¹, Richa Chauhan¹, Santosh Shubham², Muneer A.²

ABSTRACT

Introduction: Brain metastases are the commonest type of intracranial neoplasm, with an annual incidence of about 1, 70, 000 to 2, 00, 000 cases in United States. Metastatic brain tumors outnumber primary brain tumor by a ratio of 10:1, with an occurrence rate of about 25% in all cancer patients. Autopsy series demonstrating a 20% to 40% rate of brain metastases for all patients with a diagnosis of cancer. However, heterogeneous data exist regarding demographic and clinical profile of brain metastases. Aims: This study was conducted retrospectively with the aim to know the social, demographic and clinical profile of patients with brain metastases.

Material and Methods: A retrospective, single institutional study of 115 patients with brain metastases was carried out from January 2013 to January 2016. The data related to patients collected from review of hospital records and entered in a standardized case record form. Details regarding clinical history, primary diagnosis, histological diagnosis and imaging findings obtained.

Results: Majority of the cases were female in 6th decade of life. Breast cancer was the most common primary causing brain metastases followed by carcinoma lung. Adenocarcinoma was the commonest histology of the primary that lead to metastases. On imaging (CT or MRI) multiple metastases were more common than single metastases. Supratentorial lesions were more common compared to infratentorial lesions. Parietal lobe of brain was most commonly involved. Brain metastases were common in the patients with uncontrolled primary.

Conclusions: Present study concludes that brain metastases are more common in older patients. Common causes of metastatic brain disease are breast and lung cancer. Adenocarcinoma is the commonest histology of primary causing brain metastases and cerebral hemisphere are most commonly involved site.

Keywords: Brain Metastases, Primary Site of Disease, Multiple Metastases.

Supratentorial metastases (80%) are more common compared to infratentorial brain metastases.¹⁰

Presenting symptoms are various and any new neurologic symptom should be investigated in a patient with known cancer. Symptoms are due to increased intracranial pressure and focal neurological deficit- headache (70%), seizures (30%), cognitive impairment (30%), papilledema (8%) and various focal neurological deficits.^{12,13}

CT scan is the essential imaging modality for diagnosing brain metastases. Contrast enhanced tomography because of its easy accessibility and low cost is widely used. Contrast enhanced MRI of brain is the diagnostic modality of choice. MRI brain is more sensitive than contrast enhanced computed tomography in small lesions and metastases situated in the posterior fossa.^{21,22} MRI is recommended for patients with apparently single metastases on CT or for the patients with limited disease in whom the detection of asymptomatic brain metastases would change the management.¹⁴

Radiographically, metastases are ring enhancing lesions, often located at grey-white matter junction and surrounded by significant edema. Arterial hematogenous spread result in tumor emboli growth at the gray-white junction.²⁴ Metastatic lesions rarely involve the corpus callosum or cross midline. The radiological differential diagnoses are primary brain tumor, inflammatory lesion, abscess and brain hemorrhage or infarction.⁷

The treatment of brain metastases is multidisciplinary; the mainstay of treatment is radiotherapy that is whole brain radiotherapy.^{19,20} Other therapeutic modalities are surgery, stereotactic radiosurgery (SRS) and chemotherapy. The initial therapy should start early with corticosteroids, which effectively improve edema and neurological deficit.¹¹

The purpose of this study is to analyze retrospectively the social, demographic and clinical profile of patients with brain metastases.

MATERIAL AND METHODS

It is a single institutional retrospective study based on the observation of 115 patients with brain metastases from January 2013 to January 2016. Observations were based on thorough analysis of all patients and their records, data of these patients were entered in a standardized case record form. Detailed history

INTRODUCTION

Brain metastases are the commonest type of intracranial neoplasm, with an annual incidence of about 1, 70, 000 to 2, 00, 000 cases every year in united states.^{1,2} The ratio of metastatic brain tumors to primary neoplasm of brain is 10:1 and occur in about 25% of all patients with cancer. About 20% to 40% of all patients with metastatic cancer will have brain metastases at autopsy.^{3,4} Brain metastases are associated with significant morbidity and mortality and quality of life deteriorate as well.

The common primaries causing brain metastases are: lung cancer (40-50%), breast cancer (15-25%), melanoma (15-20%) and kidney (5-10%). In 5% to 10% of the patient's brain metastases were from unknown primary.⁷ Brain metastases from extracranial primaries are multiple in two-third to three-fourth of patients.^{21,23} Cerebral hemispheres are involved in about 80% of patients followed by cerebellum 15% and brainstem in 5%.⁷ Parietal and frontal lobes are most commonly involved.

¹RT, ²PG Resident, Mahavir Cancer Sansthan, Patna, Bihar, India

Corresponding author: Dr. Manashi Ghosh, MBBS, DNB (RT), Mahavir Cancer Sansthan, Patna, Bihar, India

How to cite this article: Manashi Ghosh, Kaustav Mandal, Vinita Trivedi, Richa Chauhan, Santosh Shubham, Muneer A. Clinical profile of patients with brain metastasis- a single institutional retrospective study. International Journal of Contemporary Medical Research 2017;4(2):372-376.

about demographic profile, area of brain involved, methods of diagnosis (CT Scan and MRI), number of metastatic lesion, site of primary tumor, whether primary controlled or not at the time of development of brain metastases and whether received whole brain RT were taken. Proper examination including neurological evaluation done. The investigations done were complete blood examination, liver function test, kidney function test and other imaging studies as chest X-ray postero-anterior view, ultrasonography whole abdomen, CECT chest or abdomen and pelvis or face and neck were done to detect primary disease.

RESULTS

Total 115 patients of brain metastases were there from January 2013 to January 2016. Majority of the patients were in 6th decade constituting 38.26% followed by 7th decade 21.73% [Fig 1]. In this study, female preponderance was seen constituting 68.69% whereas male constituted 31.31% [Fig 2]. Male to female ratio is 1:2. Breast cancer was the most common primary leading to brain metastases constituting 39.13% [Fig 3]. The histology of the breast cancer patients was infiltrating ductal carcinoma. Lung cancer was the second common primary causing brain metastases constituting 35.65%. Among the lung cancer patients non small cell histology constituted 33.04% and small cell histology constituted 2.6%. Other primaries causing brain metastases were gynecological malignancies 9.56% (carcinoma cervix-7, ovarian cancer-3, chorocarcinoma-1 patients), gastrointestinal system (GIT) malignancies 10.35% (gall bladder-3, esophagus-1, gastroesophageal junction-1, rectum -1, pancreas-1, hepatocellular carcinoma-1 patients), unknown primary 4.34% and others 4.6% (mediastinal tumor-1, renal cell cancer-1, malignant melanoma-1 patients). Time to development of brain metastases after completion of treatment of primary disease ranges from 0.56 to 29.6 months, with average interval of 10.04 months. Multiple brain metastases is seen in 55.65% patients whereas single brain metastases seen in 44.34% patients [Fig 4]. The distribution of single brain metastases as follows parietal 50.98%, frontal 25.49%, temporal 19.6%, occipital 17.64%, cerebellar 13.72% and others (supracellar, thalamus) 3.92% [Fig 5]. In patients with multiple metastases cerebral hemisphere involved in 54.68%, both cerebral hemisphere and cerebellum involved in 35.93% and cerebellum involved in 9.37% [Fig 6].

Supratentorial metastases seen in 69.56% of patients, 12.17% patients had infratentorial metastases and 18.26% patients had both supratentorial and infratentorial metastases [Fig 7].

The average interval for the development of brain metastases in patients with controlled primary disease is 10.37 months whereas in patients with uncontrolled primary the average interval is 8.7 months.

The frequency of single or multiple metastases for various primaries are shown in Table - 1. 60% of the patients with breast cancer as primary disease have multiple metastases followed by 56.09% in patients with lung cancer primary.

All the patients were treated with external beam radiotherapy to whole brain by CO-60 gamma rays to a total dose of 30Gy/10# or 20Gy/5#. Out of 115 patients 91 (79.13%) patients were treated with 30Gy /10# and 24 (20.86%) were treated with 20Gy/5# [Fig. 8].

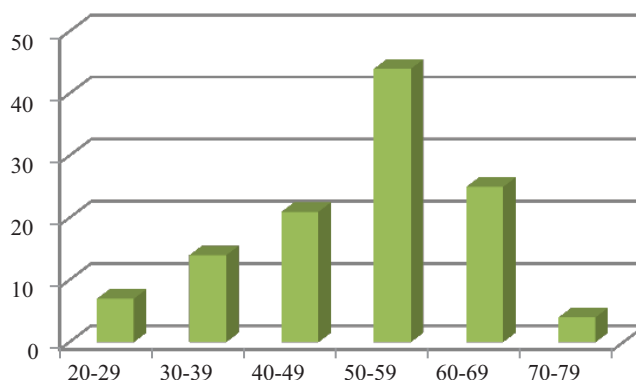


Figure-1: Bar diagram showing age distribution




Figure-2: Pie diagram showing sex distribution of patients.

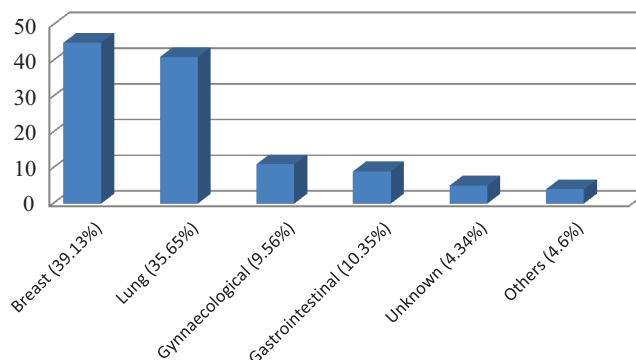


Figure-3: Showing distribution of primary disease.

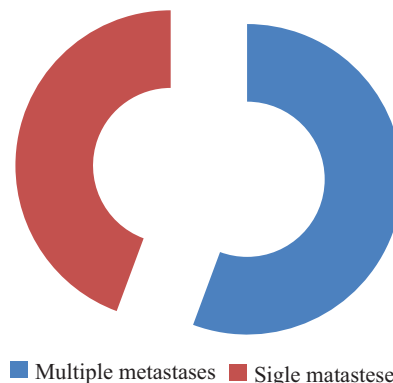


Figure-4: Pie diagram showing type of lesions

DISCUSSION

Brain metastases are the commonest type of intracranial neoplasm, with an annual incidence of about 1, 70, 000 to 2, 00, 000 cases in United States.^{1,2} The ratio of metastatic brain

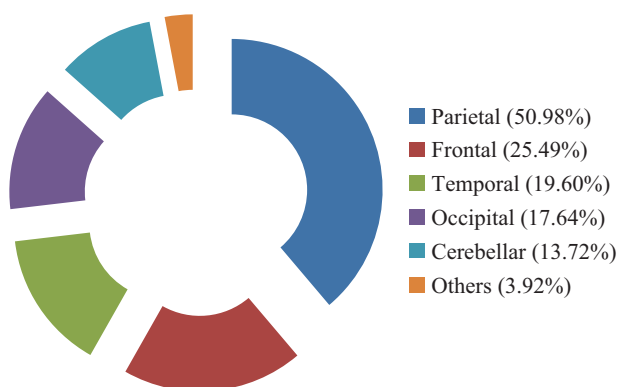


Figure-5: Showing distribution of single brain metastases.

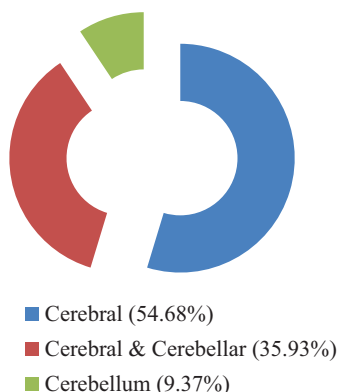


Figure-6: Showing distribution of multiple brain metastases.

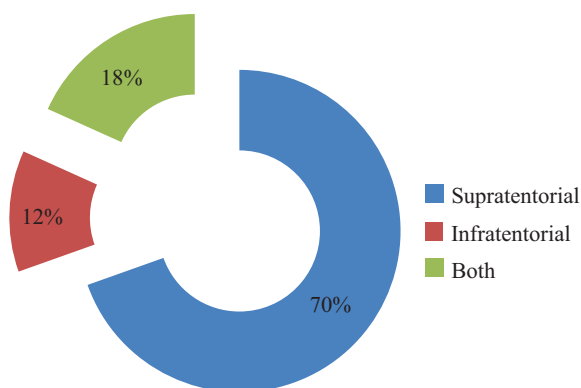


Figure-7: Pie diagram showing distribution according to location of tumor (supratentorial/infratentorial).

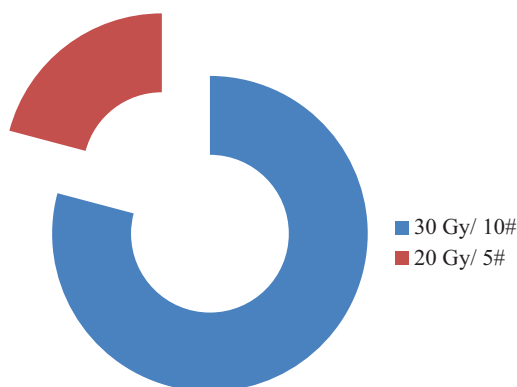


Figure-8: Showing distribution of patients treated by different radiotherapy fractionation

tumors to primary neoplasm of brain is 10:1 and occurs in about 25% of all patients with cancer. About 20% to 40% of all patients

Primary Type	Total	Single	Multiple
Breast	45	18 (40%)	27 (60%)
Lung	41	18 (43.90%)	23 (56.09%)
Cervix	7	5 (71.42%)	2 (28.57%)
Ovary	3	1 (33.33%)	2 (66.66%)
Gall bladder	3	1 (33.33%)	2 (66.66%)
Parotid	2	1 (50%)	1 (50%)
Rectum	1	1 (100%)	0
Mediastinum	1	1 (100%)	0
Renal	0	0	1 (100%)
Unknown	5	2 (40%)	3 (60%)

Table-1: Showing type of brain metastases according to primary site of disease.

with metastatic cancer will have brain metastases at autopsy.^{3,4} Brain metastases is associated with significant morbidity and mortality and quality of life deteriorate as well. Treatment of brain metastases is multidisciplinary with radiation being the main modality of treatment.^{5,6}

Saha et al from India in their study reported 44.44% patients in 50-60 years of age group, 22.22% of patients in 40-50 years age group and 16.66% patients in 30-40 years age group.⁷ Study by Akhavan showed peak incidence of brain metastases in between 5th and 7th decade of life with mean age of patients was 53.6 years.¹⁸ About 60% of patients are aged 50-70 years as stated by Victor et al.¹⁹ In present study majority of the patient's i.e 38.26% were in 6th decade, 21.73% patients were in 7th decade, 18.26% patients were in 5th decade of life which is consistent with above mentioned studies.

Study by Akhavan reported 57.8% patients were female and 42.2% were male. The primary sites of the tumor were breast i.e 32%, lung i.e 24.8%, lymphoma i.e 4.4%, sarcoma i.e 3.9%, melanoma i.e 2.9%, colorectal i.e 2.4% and renal cell carcinoma i.e 1.5%. In 16.5% of patients, brain metastases were the first presenting symptom and the primary site had not been found.¹⁸ As per Miabi et al the incidence of various primary tumors are as mentioned breast cancer in 42.6% cases, lung cancer in 40.3% cases, followed by renal cancer in 7.7% cases, colorectal cancer in 4.6% cases, lymphoma in 3.1% cases, and melanoma in 1.5% cases.²⁰ In present study 69% patients of brain metastases were female and 31% patients were male. The primary sites of tumor were breast i.e 39.13%, lung i.e 35.65%, gastrointestinal system i.e 10.35% and others 4.6%. In 4.34% patients brain metastases was from unknown primary. In two studies from India Ashifa et al and Saha et al had shown male preponderance though not statistically significant i.e 51.6% male and 48.4% females and 52.7% male and 47.22% female, respectively. The incidence of primary sites of the tumor are lung (51.57%), breast (15.7%), GIT (14.73%), malignant melanoma (5.3%), others (5.3%), unknown primary (7.3%) and lung (51.4%), breast (30.6%), unknown primary (4.2%) respectively.^{10,21}

Debnath et al and Saha et al reported that most common histology of the primary leading to brain metastases is adenocarcinoma (35-40%) and squamous cell carcinoma (20-30%).^{10,15} In present study the most common histology of the primary leading to brain metastases is Infiltrative ductal carcinoma from breast (39.13%) followed by non small cell carcinoma lung (33.04%) consistent with the above studies. Other histology are Squamous cell carcinoma (9.56%) followed by others (6.08%)

(adenosquamous, acinic cell, choriocarcinoma, lymphoma, melanoma).

In imaging study of Delattre et al single metastases seen in 49% of patients and 51% patients had multiple brain metastases ranging from one to five or more. Ashifa et al in their study reported single brain metastases was seen in 44.2% patients and multiple brain metastases was seen in 55.8% patients. In present study, the single metastases was seen in 44.34% patients and multiple metastases seen in 55.65% patients. The lobar distribution of the single metastases is as follows: parietal lobe (51.30%), frontal lobe (30.43%), occipital lobe (14.78%) and temporal lobe (13.91%). Multiple metastases were distributed in cerebrum (54.68%), cerebrum and cerebellum (35.93%), cerebellum (9.73%). Nussbaum et al reported 53% patients presented with single brain metastases located in the following areas: frontal lobe (36%), parietal lobe (24%), cerebellum (18%), occipital lobe (11%), temporal lobe (9%) and brainstem (2%). Multiple metastases were present in 47% patients, involving the cerebrum (70%), cerebrum and cerebellum (26%), cerebellum (3%) and brainstem (1%).

In the present study, cerebrum was involved in 83 patients (87.3%), cerebellum in 13 patients (11.3%), and 3 patients had brainstem involvement (3.1%). These observations correlate with the results of Patchell according to whom anterior circulation accounts for approximately 80% of parenchymal metastases compared to 20% for the lower flow posterior circulation (15% cerebellum, 5% brainstem).²⁴

The frequency of single or multiple brain metastases for each histological tumor type is shown in Table-1. Multiple metastases were observed most commonly with breast cancer patients (42.18%) followed by lung cancer patients (35.93%).

In present study 69.56% patients had supratentorial lesions, 12.17% had infratentorial lesions and 18.26% had both supra and infratentorial lesions correlate as Nussbaum et al has reported.²⁵

Out of 115 patients 49 patients had controlled primary disease and 66 patients had uncontrolled primary disease. In 36 patients with controlled primary the median time to develop brain metastases after completion of primary treatment is 7.8 months. The rest of the 13 patients developed brain metastases during primary treatment.

CONCLUSION

Our study concludes that brain metastases are commonly seen in our breast cancer and lung cancer patients. Most the patients had multiple brain metastases with uncontrolled primary and are commonly seen in elderly patients. The high incidence of brain metastases seen in our patients is suggestive of advanced stage at presentation and supports high clinical suspicion and early brain imaging in such patients.

REFERENCES

- Davey P. Brain metastases: treatment options to improve outcomes. *CNS Drugs*. 2002;16:325-38.
- Eichler AF, Loeffler JS. Multidisciplinary management of brain metastases. *Oncologist*. 2007;12:884-98.
- Li KC, Poon PY. Sensitivity and specificity of MRI in detecting malignant spinal cord compression and in distinguishing malignant from benign compression fractures of vertebrae. *Magn Reson Imaging*. 1988;6:547-556.
- Wen PY, McLaren Black P, Loeffler JS. Treatment of metastatic cancer. In: DeVita VT, Hellman S, Rosenberg SA, eds. *Cancer: principles and practice of oncology*. Philadelphia, PA: Lippincott Williams and Wilkins, 2001:2655-2670.
- Priestman TJ, Dunn J, Brada M, et al. Final results of the Royal College of Radiologists' trial comparing two different radiotherapy schedules in the treatment of cerebral metastases. *Clin Oncol (R Coll Radiol)*. 1996;8:308-315.
- Haie-Meder C, Pellae-Cosset B, Laplanche A, et al. Results of a randomized clinical trial comparing two radiation schedules in the palliative treatment of brain metastases. *Radiother Oncol*. 1993;26:111-116.
- Delattre JY, Krol G, Thaler HT, Posner JB. Distribution of brain metastases. *Arch Neurol*. 1988;45:741-4.
- Sze G, Milano E, Johnson C, Heier L. Detection of brain metastases: Comparison of contrast-enhanced MR with unenhanced MR and enhanced CT. *AJNR Am J Neuroradiol*. 1990;11:785-91.
- Wen PY, McLaren Black P, Loeffler JS. Treatment of metastatic cancer. In: DeVita VT, Hellman S, Rosenberg SA, eds. *Cancer: principles and practice of oncology*. Philadelphia, PA: Lippincott Williams and Wilkins, 2001:2655-2670.
- Saha A, Ghosh SK, Roy C, et al. Demographic and clinical profile of patients with brain metastases: A retrospective study. *Asian J Neurosurg*. 2013;8:157-61.
- Ruderman NB, Hall TC. Use of glucocorticoids in the palliative treatment of metastatic brain tumors. *Cancer*. 1965;18:298-306.
- Posner JB. Brain metastases: 1995. A brief review. *J Neurooncol*. 1996;27:287-93.
- Sawaya R, Bindal RK, Lang FF, Abi-Said D. 2nd ed. New York: Churchill Livingstone; 2001. *Metastatic brain tumors*.
- Davis PC, Hudgins PA, Peterman SB, Hoffman JC Jr. Diagnosis of cerebral metastases: Double-dose delayed CT vs contrast-enhanced MR imaging. *AJNR Am J Neuroradiol*. 1991;12:293-300.
- Schellinger PD, Meinck HM, Thron A. Diagnostic accuracy of MRI compared to CCT in patients with brain metastases. *J Neurooncol*. 1999;44:275-81.
- Suzuki K, Yamamoto M, Hasegawa Y, Ando M, Shima K, Sako C, et al. Magnetic resonance imaging and computed tomography in the diagnoses of brain metastases of lung cancer. *Lung Cancer*. 2004;46:357-60.
- Hwang TL, Close TP, Grego JM, et al: Predilection of brain metastasis in gray and white matter junction and vascular border zones. *Cancer*. 1996;77:1551-1555.
- Ali Akhavan, Fariba Binesh, Samaneh Heidari. Survival of Brain Metastatic Patients in Yazd, Iran *Asian Pacific Journal of Cancer Prevention*. 2014;15:3571-3574.
- Victor TS. Brain metastasis. Medscape reference. [Last updated on 2011 Oct 7]. Available from: <http://www.emedicine.medscape.com/article>.
- Miabi Z. Metastatic brain tumors: A retrospective review in East Azarbyjan (Tabriz). *Acta Med Iran*. 2011;49:115-7.
- Asifa Andleeb, Mohammad Ashraf Teli, Mohammad Maqbool Lone, Fir Afroz, Hakim Irfan Ahmad, Kaneez Fatima Brain metastases: A single institute experience. 2016;5:213-217.
- Debnath H, Barua KK, Hossain MA, Khair MA, Islam MA. Outcome and prognosis of metastatic brain tumour: A

- study of 35 cases. *Bangladesh J Neurosci.* 2008;24:17–23.
23. Abrams HL, Spiro R, Goldstein N. Metastases in carcinoma; analysis of 1000 autopsied cases. *Cancer.* 1950;3:74-85.
 24. Patchell RA. Brain metastases. *Neurol Clin.* 1991;9:817-24.
 25. Nussbaum ES, Djalilian HR, Cho KH, Hall WA. Brain metastases. Histology, multiplicity, surgery, and survival. *Cancer.* 1996;78:1781–8.

Source of Support: Nil; **Conflict of Interest:** None

Submitted: 19-01-2017; **Published online:** 26-02-2017