Clinicopathological Study of Infectious Graulomatous Dermatoses in a Peripheral Hospital of Mumbai

Yasmeen Khatib[1], Surekha Khaire[2], Meena Makhecha[3], Anuja Kamat[4], Ranjeet Rathod[5], Komal Kapoor[5]

ABSTRACT

Introduction: Infectious granulomatous dermatoses (IGDS) can occur due to various causes and have overlapping clinical and histological features. An identical histological pattern may be produced by several causes and conversely a single cause may produce several histopathological patterns. Moreover the causative agent cannot be demonstrated in majority of the cases. Hence they pose a diagnostic challenge to both dermatologists and pathologists. The aim of the present study was to classify IGDS based on their etiology using the histological features, to determine their relative frequency and to highlight the importance of clinical correlation in arriving at a correct diagnosis.

Material and Methods: A prospective study was done on 100 clinically diagnosed cases of IGDS over a period of 2 years. Clinical and histopathological data along with special stains was studied and concordance rate was calculated. Chi square test was used for comparison of proportion of different groups.

Results: Out of the total 700 skin biopsies received 100 (18%) were clinically diagnosed cases of IGDS. The age of the patients ranged from 2 years to 71 years with maximum number of cases in the 21years to 30 years age group. There were 69 females and 31 males included in this study. Majority of the cases were due to leprosy (54 cases) followed by tuberculosis,(27 cases) fungal infections(3cases) and one case each of cutaneous leishmaniasis and cat scratch disease.

Conclusion: Major cause of granulomatous dermatitis is infection with leprosy and tuberculosis being the common causes. Histopathology plays an important role in classification and diagnosis of IGDS. Clinicopathological correlation is required for correct diagnosis

Keywords: infectious granulomas, leprosy, tuberculosis fungal, leishmaniasis.

INTRODUCTION

Infective granulomatous lesions of the skin comprise a large group of dermatoses due to varied causes but showing the common feature of granuloma formation. The granulomatous reaction pattern is characterised by collection of epitheloid cells rimmed by lymphocytes giant cells with or without central necrosis.[1] IGDS poses a diagnostic challenge both to the clinicians and pathologists because an identical histological picture is produced by several causes and conversely a single etiology can produce different histological patterns.[2] Hence a clinio- pathological correlation is very important in these cases to arrive at a correct diagnosis for optimum treatment. This can be aided even further by adding some special stains like ZN stain Fite faraco stain and GMS stain for specific diagnosis.[2]

There is a high prevalence of IGDS in a developing country like India with leprosy and tuberculosis being the most common causes.[2] However the frequency of these infections across different regions is variable. There are only few studies of IGDS done in Mumbai describing their clinicopathological spectrum.[3] We conducted the present study with the aim of classifying IGDS based on its cause, to find the frequency of these lesions and to study their clinical and histopathological spectrum.

MATERIAL AND METHODS

A prospective observational study of 100 cases of clinically diagnosed IGDS was conducted in the department of pathology at DR R. N. Cooper Hospital for a period between January 2012 till December 2013.Permission of ethics committee was obtained. The clinical history, age, sex, duration of disease, location, type of lesion and clinical diagnosis was noted. Skin biopsies were fixed, processed and stained with hematoxylin and eosin stain, modified Fite Faraco stain, ZN stain, PAS stain and GMS stain. The sections were studied for the presence of epidermal changes, type and location of granulomas, predominant cell type, involvement of nerves and the presence of microorganisms if any was noted. A clinicopathological correlation was done and final diagnosis was given.

STATISTICAL ANALYSIS

Statistical Analysis was done using SPSS 15 software. Percentages were calculated for the various categories. Chi -square was used to compare the various groups and a *P-value* <0.05 was considered as significant.

RESULTS

Out of the total 700 skin biopsies received in our department 100 cases (18%) were clinically diagnosed as IGDS. Out of the 100 cases a definite diagnosis was given in 86 cases while 14 cases were reported as granulomatous inflammation and could not be furthur categorised. Majority of the cases were of leprosy 54 (62.7%) followed by TB 27 cases (31.3%) fungal infection 3 cases (3.4%) and 1 case each ofpost Kala azar dermal leishmaniasis and cat scratch disease. There were 69 males and 31 females with a male female ratio of 2.3:1. The age of the patients ranged from 2 years to 71 years. Table 1 shows the age and sex distribution of different IGDS. Maximum

[1]Associate Professor, Department of Pathology, [2]Registrar Department of Pathology, [3]Associate Professor, Department of Dermatology, [4]Senior Medical Officer, Department of Pathology, [5]Junior Resident, Department of Pathology, HBT Medical College, Dr. R.N. Cooper Hospital, Mumbai, India.

Corresponding author: Surekha Khaire, Registrar Department of Pathology, HBT Medical College, Dr. R.N. Cooper Hospital, Mumbai, India.

How to cite this article: Yasmeen Khatib, Surekha Khaire, Meena Makhecha, Anuja Kamat, Ranjeet Rathod, Komal Kapoor. Clinicopathological study of infectious graulomatous dermatoses in a peripheral hospital of Mumbai. International Journal of Contemporary Medical Research 2016;3(11):3311-3314.

Final HP Diagnosis	Sex		Age group (yrs)								Total
	M	F	0 to 10	11 to 20	21 to 30	31 to 40	41 to 50	51 to 60	61 to 70	71 to 80	
Leprosy	43	11	00	03	18	14	07	04	07	01	54
TB	13	14	08	09	04	05	00	01	00	00	27
Fungal infection	03	00	00	00	02	00	00	00	01	00	03
Cat scratch disease	01	00	00	01	00	00	00	00	00	00	01
Kala azar	01	00	00	01	00	00	00	00	00	00	01
Granulomatous inflammation	08	06	00	01	05	04	02	01	01	00	14
Total	69	31	08	15	29	23	09	06	09	01	100

Table-1: Association among study group between final histopathological (HP) Diagnosis and age groups (years)

Histological Diagnosis	No. of cases	Percentage
Tuberculoid Leprosy (TL)	9	16.67%
BorderlineTuberculoidLeprosy (BT)	17	31.48%
Borderline lepromatous (BL)	6	11.11%
lepromatous Leprosy (LL)	3	5.56%
Intermediate leprosy	7	12.96%
Histioid Leprosy	6	11.11%
Type 1 Lepra Reaction	2	3.70%
Type 2 Lepra Reaction (ENL)	4	7.41%
Total	54	100 %

Table-2: Distribution of various subtypes of Leprosy in present study based on histology

Final Diagnosis	No. of cases	Percentage
Lupus vulgaris	11	40.74%
TBVC	05	18.51%
Lichen scrofulosorum	05	18.51%
Scrofuloderma	04	14.81%
Papulonecrotic tuberculid	02	7.4%
Total	27	100%

Table-3: Incidence and Percentage of different types of Cutaneous Tuberculosis

patients were in the 21 to 30 years age group followed by 31 to 40 years age group. Out of the 54 cases of leprosy (Table-2) borderline tuberculoid leprosy (BT)(31.4%) constituted the most common diagnosis followed by tuberculoid leprosy, (TL) (16.67%) borderline lepromatous leprosy (BL) (11.11%) indeterminate leprosy (12.96%), histoid leprosy (11.11%) and lepromatous leprosy (5.56%). Reactions constituted 11% of the cases with 4 cases of erythema nodosum leprosum (ENL) and 2 cases of type 1 reaction. Leprosy was most common in 21 to 30 years age group followed by 31 to 40 years age group. The sex distribution pattern of leprosy showed a male preponderance of 43males (79.63 %) as compared to 11 (20.37%) females. Upper limb (18 cases) was the common site involved followed by trunk (14 cases) and face (6 cases).Multiple site of involvement (12 cases) was seen in lepromatous leprosy and histoid leprosy. Fite stain was positive in 18 out of 54 cases. The clinicopathological concordance of leprosy in our study was 51.8%. Table 3 shows percentage of different types of cutaneous tuberculosis. Out of the 27 cases of cutaneous tuberculosis, lupus vulgaris was the most common lesion (40.74%) followed by TBVC (18.51%),lichen scrofulosorum (18.51%) scrofuloderma (14.81%) and papulonecrotic tuberculid, (7.4%). The most common age group was 11 to 20 years followed by patients less than 10 years of age. There were 14 males and 13 females of TB included in the study. The most common site of involvement was lower limb (9 cases) followed by upper limb (8cases). 4 out of 21 cases showed AFB positivity.2 cases of lupus vulgaris and 1 case each of scrofuloderma and TBVC were AFB positive. In our study fungal granulomas were seen in 3cases (3.4%) out of which 2 cases were diagnosed as mycetoma and one case as chromoblastomycosis. PAS and GMS stains were done in these cases for confirmation of the diagnosis. One case of post Kala Azar leishmaniasis was confirmed by demonstration of LD bodies within the macrophages with the help of Giemsa stain. There was only one case of cat scratch disease in our study and its diagnosis was based on clinical picture and histological features.

Statistical analysis showed that leprosy was more common in patients more than 20years of age while TB was more common in patients less than 20years age and this difference was statistically significant, *P value* (<0.001). Leprosy was more common in male patients while TB was almost equally seen in both genders and this difference was also statistically significant *Pvalue* <0.001.

DISCUSSION

Cutaneous granulomas are usually classified as infectious or non-infectious depending on the presence or absence of pathogenic organism.[4] The incidence of IGDS in our study was 18% of all skin biopsies received. Grower et al from Mumbai, Qureshi et al from Pakistan and Gautam et al from Nepal have reported the frequency of IGDS to be 14.58%, 14.9% and 6.67%.[3,5,2] This shows a geographical variation in the incidence of IGDS in different regions. Table 4 shows distribution and comparison of cases of infectious granulomatous dermatoses in different studies. In our study, a higher incidence of IGD S is seen which shows that both leprosy and TB have a high prevalence in Mumbai. Leprosy(62.7%) was the commonest cause of IGDS in our study followed by tuberculosis(31.3%). In a similar study, Amarjit Bal et al reported 72.4% cases of leprosy followed by 23.1% cases of cutaneous tuberculosis.[6] Grover et al have also reported similar results with 77.28% leprosy and 22.72% cases of TB in their study.[3] Out of the 54 cases of leprosy borderline tuberculoid leprosy(BT) constituted the most common diagnosis followed by tuberculoid leprosy(TT). Thus we can conclude that leprosy subtypes BT and TT are more common in this population of Mumbai. Similar findings have been reported by Grover et al from Mumbai, Bal et al from Punjab[6] and Gautam et al from Nepal[2] while lepromatous leprosy (LL) has been found to be more common as reported by Jindal from Himachal Pradesh.[7] The sex distribution pattern of leprosy revealed a male preponderance of 43 males as compared to 11 females with a male female ratio of 3.9:1.Grover and Jayalaxmi have

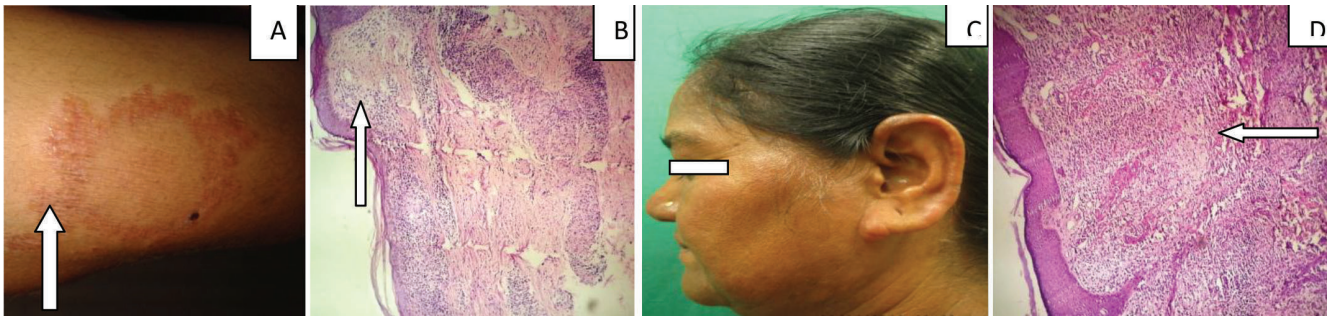

Figure-1: (A) shows a well defined plaque of Tuberculoid Leprosy having an erythematous infiltrated margin and atrophy at the center. (B) Histopathology of TL showing epithelioid granuloma encroaching the epidermis along with perineural involvement. (100X) (C) Lepromatous Leprosy shows infiltrations of pinna and cheek by LL lesions. (D) Histopathology of Lepromatous leprosy shows sheets of of foamy Lepra cells in the dermis. (100X)

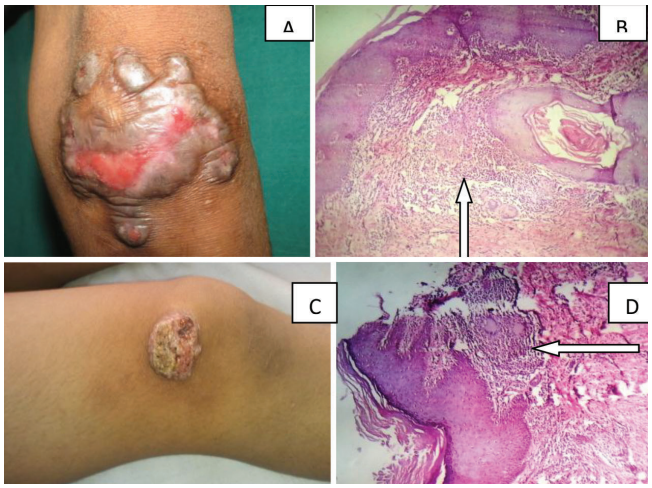

Figure-2: (A) Lupus vulgaris shows plaque with central ulceration. (B) Histopathology of Lupus Vulgaris showing epithelioid granuloma and dense lymphocytic infiltrate in upper dermis. (C) shows a single plaque of TBVC over knee with verrucous surface and ulceration at one place. (D) Histopathology of TBVC showing epithelioid granuloma in upper dermis with hyperkeratotic, hyperplastic epidermis. (100X)

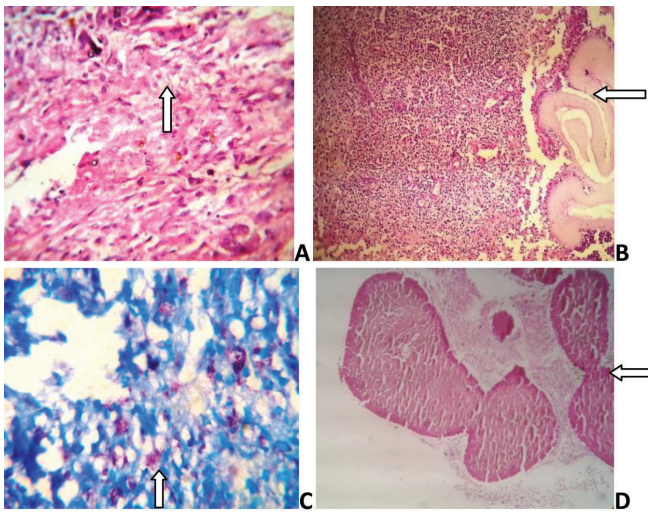

Figure-3: (A) shows chromoblastomycosis with brown sclerotic'Copper Penny bodies. (400X). (B) shows fungal colonies along with granulation tissue on H and E stained section (400X) in case of mycetoma. (C) LL showing numerous acid fast bacilli, some within lepra cells (1000X). (D) shows fungal colonies on PAS stained section(400x) in case of mycetoma.

also found a male preponderance with 79.42% and 65% male leprosy patients.[3,8] This may be due to more hospital access to males as compared to females due to socioeconomic factors. In our study upper limb (33.33%) was the most common site followed by trunk (22.22%) and face (11.11%).Multiple sites were more common in lepromatous and histoid leprosy. Similarly Grover et al has also reported upper limb to be the commonest site with 29% cases.[3] while Jha et al has found neck to be the common site.[9] Fite positivity in our cases was 33.33% which was similar to study of Bal et al[6] which show 36.4% fite positivity. The clinicopathological concordance was seen in 51.85% our of cases while Anuja et al has reported it to be 53.44%[10] and Giridhar et al as 60.23%.[11] Maximum discordance was seen in cases of indeterminate type where the histological features are non specific and in the tuberculoid pole where BT and TT can show overlapping features. The disparity between clinical and histological diagnosis also depends upon the lesion biopsied and the time of taking the biopsy. If the biopsy is taken at an early stage there is likely to be a clinic pathological discordance. Out of the 27 cases of cutaneous tuberculosis lupus vulgaris,(40.74%), TBVC (18.51%) and lichen scrofulosorum (18.51%) were the commonest types. Grover et al[3] and Bal et al[6] found lupus vulgaris to be the commonest type of cutaneous TB followed by scrofuloderma, while Khan et al[12] and Zafar et al[13] found TBVC to be second most common diagnosis after lupus vulgaris which is similar to our study.The presentation of cutaneous TB depends on the route of infecion (endogenous/ exogenous),immune status and previous sensitization with tuberculosis. Thus skin can react in different ways giving rise to such a varied spectrum.[6] The most common age group affected was 11 to 20 years (33.33%) followed by 0 to 10 years(29.6%), while other studies have reported the commonest age group to be 21 to 30 years. Females were more commonly affected than males.This is similar to studies by Zafar et al[13], while Sengupta[14] and Sehgal[15] have reported a male preponderance. Clinicopathological concordance for cutaneous TB in our study was 81.48% while Nitin et al reported it to be 89.13%.[16] TB is very common in our population in spite of active immunization programme through BCG vaccination. With the emergence of multi drug resistance TB and AIDS epidemic there has been a world wide rise in TB cases more so in the lower socio economic group with poverty, poor nutrition, overcrowding, poor hygienic conditions acting as the contributory factors.[13] Incidence of

cutaneous TB worldwide is 0.1 to 1% of all cutaneous disorders.[17] We found it to be 3.85%. This could be attributed to a high incidence of systemic TB in our area with many patients referred to our center with a specialised dermatology centre, biopsy facility and access to free treatment. TB has to be differentiated from other granulomatous dermatitis. Clinical correlation, X-ray chest, sputum examination with positive mantoux test helps in the diagnosis. AFB was positive in only 4 (14.8%) cases while Ranjan et al reported a positivity of 17.19%.[18] We found 3 (3.4%)cases of fungal infections in our study one of chromoblastomycosis and 2 of mycetoma while Mohammed et al has reported 5.6% cases of fungal dermatitis.[4] PAS and GMS stain are helpful in these cases.[19] Chromblastomycosis can be mistaken for TBVC clinically but the demonstration of brown coloured spores of fungus known as copper penny help in the diagnosis. Only one case of leishmaniasis was found in our study while Bal et al reported 1.65%, Zafar et al 7.3% and Gautam et al 3.7% cases of leishmaniasis in their studies of IGDS. There is a wide geographical variation in the incidence of this disease. LD bodies can be identified with Geimsa stain in 50% of the cases as reported by Bal et al.We had one case of catscratch disease with stellate necrosis and palisading granulomas.Margaleith has described the cutaneous manifestations of this disease.[20]

CONCLUSION

Infections are an important cause of cutaneous granulomatous dermatoses with leprosy and TB being the most common causes. The high incidence of these infections need to be addressed with a good heaith care control programme with better access to treatment. Communication between the clinician and pathologist is required to arrive at a correct diagnosis. Choosing a proper site of biopsy, its adequacy and other supportive tests can be helpful. IGDS have a varied spectrum both clinically and histologically. Special stains, culture studies and PCR may be needed in some cases with overlapping features.

REFERENCES

1. Weedon D. The granulomatous reaction pattern. In: Weedon D (ed). Skin Pathology, 2nd ed. Philadelphia: Churchill Livingstone, 2002:193-220.
2. Gautam K, Pai RR, Bhat S.Granulomatous lesions of the skin. Journal of Pathology of Nepal. 2011;1:81-86.
3. Grover S, Agale S, Decosta GF,Valand AG,Clinico-Histopathological Spectrum of Infectious Granulomatous Dermatoses in Western India- A Representative Study from Mumbai.Journal of Clinical and Diagnostic Research. 2016;10:10-14.
4. El-Khalawany M, Meraag I, Eassa B, El-Naby HH. Clinicopathological features and the practice of diagnosing infectious cutaneous granulomas in Egypt. Int J Infect Dis. 2011;15:620-6.
5. Qureshi R, SheikhAR and ul Haque A.Chronic Granulomatous Inflammatory Disorders of Skin at a Tertiary Care Hospital in Islamabad. International Journal of Pathology. 2004;2:31-34.
6. Bal A, Mohan H, Dhami G P. Infectious granulomatous dermatitis: A clinico pathological study. Indian J Dermatol. 2006;51:217-20.
7. Jindal N, Shankar V, Tegta GR, Gupta M, Verma GK. Clinicoepidemilogical trends [10] of leprosy in Himachal Pradesh: a five year study. Indian J Lepr. 2009;81:175-79.
8. Jayalakshmi. Histopathology of skin lesions in leprosy. Malaysian J Pathol. 1980;3:39-45.
9. Jha R, Karki S. Limitations of Clinico-histopathological Correlation of Skin [13] Biopsies in Leprosy. J Nepal Health Res Counc. 2010;8:40-43.
10. Sharma A, Sharma RK, Goswsami KC, Bardwaj S. Clinico-Histopathological Correlation in Leprosy.JK Science. 2008;10:120-23.
11. Giridhar M, Arora G, Lajpal K, Singh KC. Clinicohistopathological concordance in Leprosy - A Clinical, Histopathological and Bacteriological study of 100 cases. Indian J Lepr. 2012;84:217-25.
12. Khan Y, Anwar J, Iqbal P, Kumar A. Cutaneous tuberculosis: a study of ten cases. J Pak Assoc Dermatol. 2001;11:6-10.
13. Zafar MN, Sadiq,S, Memon.M.A. Morphological study of different granulomatous lesions of the skin. Journal of Pakistan Association of Dermatologists. 2008;18:21-28.
14. Sengupta LK, Talukder G, Sharma A. Cell-mediated immunity in cutaneous tuberculosis. Indian J Med Res. 1981;73:746-50.
15. Sehgal VN, Srivastava G, Khurana VK. An appraisal of epidemiologic, clinical, bacteriologic, histopathologic, and immunologic parameters in cutaneous tuberculosis. Int J Dermatol. 1987;26:521-6.
16. Chaudhari ND. Talaniker HV, Deshmukh P, Gupta S. A clinicopathological study of cutaneous tuberculosis. Int J Pharm Biomed Sci. 2012;3:181-183.
17. Yasaratne BMGD, Madegedara DM. Tuberculosis of the skin. Journal of the Ceylon College of Physicians. 2010; 41:83-88.
18. Agraval R, Kumar M, Kumar P. Cutaneous tuberculosis.A clinicopathological study. Indian journal of medical specialities. 2012;3:138.
19. Bansala C, Batrab M, Sharmac KL, Tulsyanb S, Srivastavaa AN. Facial granulomatous dermatoses: A clinico-pathological study Journal of the Saudi Society of Dermatology and Dermatologic Surgery. 2013;17:55–61.
20. Margileth AM. Dermatologic manifestations and update of cat scratch disease. Pediatr Dermatol. 1988;5:1.

Source of Support: Nil; **Conflict of Interest:** None

Submitted: 17-10-2016; **Published online**: 03-12-2016