

Lichtenstein v/s Preperitoneal Mesh Placement-in Cases of Inguinal Hernias

G S Randhawa¹, Navneet Kaur², Subhash Goyal³

ABSTRACT

Introduction: Repair of inguinal hernia remained an equivocal task; evident from the fact that many methods with different approaches and material tried since time immemorial. A definite or ideal solution for the problem is yet to be evolved despite a relentless effort over many years by best of the brains as researchers. One point is agreed universally is institution of non-tension repair. This is possible only by using synthetic mesh as 'patch' for the defect. Lichtenstein repair became the standard procedure out of several other methods and improved the results on all parameters vis a vis repairs causing tension over tissues with sutures. The most commonly performed procedure was Bassini's repair. Recently introduced repair as preperitoneal placement of mesh, gaining popularity especially after the introduction of laparoscopic surgery. Open preperitoneal repair becoming popular because of low cost and almost a daycare procedure under local anaesthesia.

Material and methods: A comparative study done over 100 cases; 50 in each group. 50 cases were subjected to preperitoneal open repair and another 50 were repaired with classical Lichtenstein method. All patients were males between ages of 20-60yrs. Patients with comorbidities affecting healing viz: diabetes, chronic renal failure, impaired liver function, anaemia etc. were not included in the study. Similarly, patients with recurrent problem, local distorted anatomy or infection excluded from the series. A follow-up of one year was done and the study period extended over six months i.e. patients came over a period of six months.

Results: the results were interpreted on following parameters- operation time, post operative pain, ambulation, chronic groin pain, recurrence and infection of mesh. Here the graph was tilting in favour of the preperitoneal method.

Conclusion: though Lichtenstein method has acquired the distinction of gold standard unequivocally and mastered by most of the surgeons; still there is a room for improvement on certain fronts like – post operative pain which is a constant feature with this method. Groin pain as chronic nagging pain also gets cured to great extent by new method. Though infection rate and recurrence showed no difference.

Keywords: hernia, synthetic mesh, post-op pain

INTRODUCTION

Inguinal hernia as a defect in the groin was known to prehistoric people.¹ Since the advent of its treatment as surgical remedy various methods to seal the defect and to prevent its recurrence are tried.^{2,3} Till recently despite best tailored repairs recurrence used to be fairly common. A tensionfree repair with synthetic mesh patch proved a near ideal repair and out of many such methods Lichtenstein^{5,9,10} repair became classic and gold standard. But the problem of groin pain remained same perhaps slightly upshooted which affected a patient's daily routine and profession especially those with heavy duties requiring lifting

weights, prolonged standing and strenuous work. Recently, especially after the introduction of laparoscopic surgery a method excluding opening of inguinal canal devised called preperitoneal repair; where a mesh is placed in preperitoneal space⁵ avoiding nerves in inguinal canal and moreover a proper repair of fascias can be effected in open repairs. As nerves, vessels and muscles in inguinal canal remain untouched patient remains painfree in immediate post-operative period and thereafter. Method can easily be mastered can be performed quickly even in local anaesthesia.

This study was aimed to evaluate the merits of new coming up method of inguinal hernia repair with lesser sequelae, especially chronic pain syndrome associated with classical Lichtenstein procedure at operation site, leading to decreased work efficiency of an individual.

MATERIAL AND METHODS

Study included two groups of patients 50 in each group requiring hernia surgery. Group A included those who were repaired with open preperitoneal method while group B included those who underwent standard Lichtenstein repair.

Procedure

Group A- an incision of about 5-7.5 cms long given in outer part of suprapubic fold. skin, subcutaneous tissue, scarpa's fascia and external oblique aponeurosis cut in the same line. Now internal oblique and transverses muscles splitted and preperitoneal space reached. A gentle blunt dissection used to create space. Hernia sac along with spermatic chord structures will be found entering inner ring.

A gentle and blunt dissection will easily separate the sac from rest of the structures in inguinal canal and scrotum. Cord separated. Herniotomy done and stump invaginated. A darn of fascia transversalis done. prolene mesh of appropriate size designed according to need and sutured to the peritoneum with 2/0 vicryl at four corners and one central stitch. The invaginated stump of hernia will be lying in the centre of the mesh. Proper haemostasis achieved and wound closed layer by layer without drain. A simple aseptic dressing applied.

In group B- inguinal canal opened. Sac dissected out from rest of the canal contents. Herniotomy done. A mesh of appropriate size sutured to posterior wall of canal encircling spermatic cord with classical five stitch anchoring. Wound closed in

¹Associate Professor, ²Assistant Professor, ³Professor, Punjab Institute of Medical Sciences (PIMS), Garha Road, Jalandhar, Punjab (India)

Corresponding author: Dr G S Randhawa, B1-1732, Randhawa Hospital, Maqsudan Chowk, Jalandhar, Punjab, India-144008.

How to cite this article: G S Randhawa, Navneet Kaur, Subhash Goyal. Lichtenstein v/s preperitoneal mesh placement-in cases of inguinal hernias. International Journal of Contemporary Medical Research 2016;3(11):3275-3277.

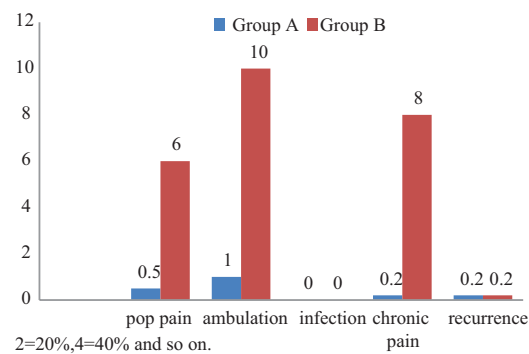
layers without drain. Aseptic dressing done. All patients were prescribed antibiotics and an initial dose of NSAID injection. Later analgesics given only if there was complaint of pain. Ambulation encouraged from next morning onward. Wound inspected for any sign of infection. All the patients discharged from hospital between 2-4 post operative day. Skin staples removed on 7 postoperative day. Later followed up at regular intervals till one year.

RESULTS

Post operative pain- only 05(10%) cases complained about pain at surgical site in group A, while 30(60%) asked for analgesics in group B. All the patients (100%) in group A were ambulatory on first postoperative day; even those who were complaining pain. It showed that intensity of pain was low in group A cases. A substantial number of patients in group B (n=30;60%) needed analgesic injections post-operatively at least for two days, thereafter they were switched over to oral analgesics. Only 5(10%) patients could walk on first postoperative day of group B. Group A patients were ambulatory in comfortable posture while those in group B walked with a limp. Group A subjects needed analgesics regularly till 2nd postoperative day while only 2 cases asked for an analgesic in group A. Only one patient in group A complained of nagging pain especially on strenuous activity while 40 (80%) patients came for followup with a complaint of nagging pain in groin after strenuous work, driving a vehicle or stretch exercises. Patients who came regularly for followup till six months of their postoperative period none developed mesh infection in both the groups. Two patients developed recurrence one in each group (02%) (Table-1,2). Thinking on cosmetic point of view, many with Lichtenstein repair complained about the ugliness of scar especially medial part extending into pubic hairline. None in group had such complaint as the incision spared pubic area.

DISCUSSION

Since the advent of alternate method of hernia repair^{5,6} through preperitoneal approach, lot of interest was shown by many researchers with different set of data.^{7,8} Results range from no difference to a vast difference especially on pain front. Work includes small serieses⁹ to meta-analysis^{10,11,13} of large volume data. Most of the authors have shown negligible difference on fronts like- mesh infection and recurrence.^{12,14} Major difference recorded in immediate post-operative and long term chronic



Graph-1: Graphic comparison of results of group A and group B

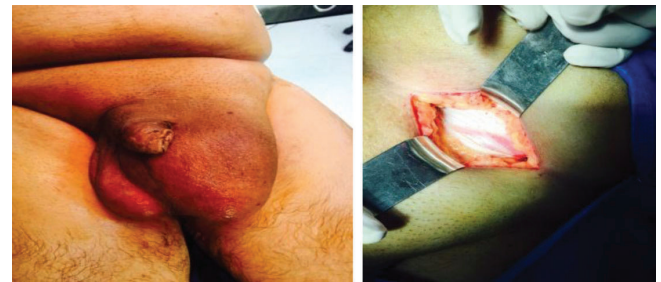

Figure-1: Pre-operative; **Figure-2:** Exposed external oblique

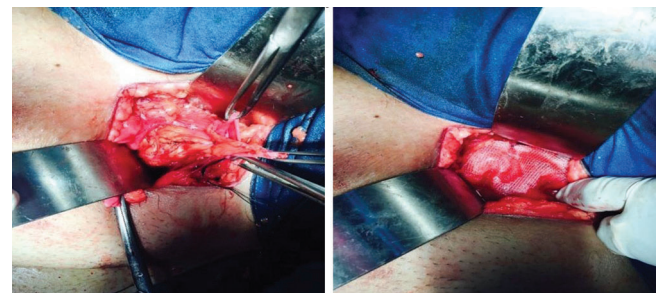


Figure-3: Hernia contents (omentum); **Figure-4:** External oblique restored

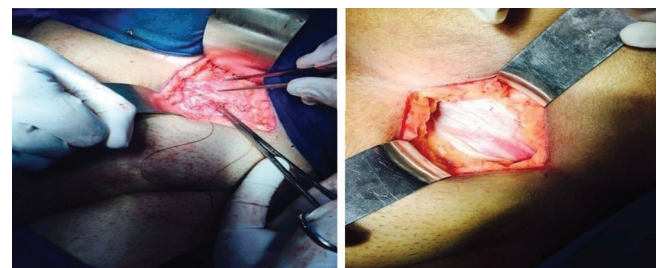


Figure-5: Muscles approximated; **Figure-6:** External oblique restored

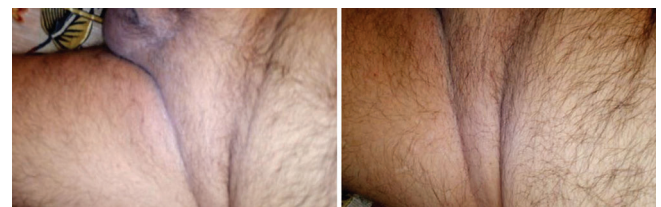

Figure-7: Final appearance-1 month; **Figure-8:** Final appearance-2mnths

Hernia type	Group A	Group B
Direct	20	22
Indirect	30	28
Bilateral	05	04
Both direct	02	02
Both indirect	03	02
Mixed	00	01

Table-1: Types of hernias in both groups

Repair type	Post-op pain	ambulation	infection	Chronic groin pain	Recurrence
Preperitoneal	05(10%)	All (100%)	nil	01(02%)	01(02%)
Lichtenstein	30(60%)	05(10%)	nil	40(80%)	01(02%)

Table-2: Comparison of data of both groups

nagging groin pain. Data range from 15-40% during earlier work to 20-70% in later series of Lichtenstein approach.¹⁵⁻¹⁷ In our work its 80%(n=40) with a range of severity – mild discomfort to severe disabling pain forcing the patient to discontinue work and rest. There was significant post-operative pain¹² (60%;n=30) despite initial dose of NSAID analgesic parenterally. Most series reported immediate post-operative pain less than 40%.^{19,21} This can be due to type of analgesic used immediate post-operatively. In many western countries narcotic analgesia is common practice to relieve post-operative pain; which is not in our circumstances. Ambulation is an important parameter for any postoperative case. Obviously pain determines degree of ambulation.²² Early ambulation prevents many complications inherent to anaesthesia and recumbancy like – chest congestion, deep vein thrombosis and bowel movements. We observed a 100%(n=50) off bed activity in group A cases while only 10%(n=05) could walk on first post-operative day.all the authers observed same results though with different data but definitely preperitoneal groups were leading with bigger margin statistically.^{23,24} Most authers have shown a recurrence rate either zero or around 0.1%.^{13,26} in our study one patient (n=50) in each group developed recurrence, showing an incidence of 2%; though 6 patients lost to follow-up before a total period of observation(6 months), and one patient died in a road traffic accident before completion of observation period.

CONCLUSION

Each of two i.e surgeon and patient wants an easy and hassalfree intraoperative and post-operative period. Pain is the major determinant to achieve this goal. As inguinal canal contains branches of sesory nerves supplying contents and surroundings of canal, a damage or entrapment of nerves leads to acute and chronic pains. Preperitoneal space is free of nerves cause no pain of high intensity. Preperitoneal mesh repair has an edge over the classical Lichtenstein in regard to early ambulation and early return to normal painfree activity in the present times of cut-throat competition and job insecurity. A boon for elderly as their dependency lessened and complications of recumbancy avoided which they are manifold prone to than younger lot.

REFERENCES

1. Read RC. Francis C Usher: the herniologist of the twentieth century. *Hernia*. 1999;3:57–61.
2. Read RC. The development of inguinal herniorrhaphy. *Surg Clin North Am*. 1984;64:185–196.
3. Kux M. Anatomy of the groin: a view from the surgeon. In: Fitzgibbons RJ, Greenberg AG (eds) *Nyhus and Condon's Hernia*, 5th edition. JB Lippincott, Philadelphia. 2002;45–53.
4. Read RC. Annandale's role in the development of preperitoneal groin herniorrhaphy. *Hernia*. 1997;1:111–115.
5. Lichtenstein IG, Shulman AG. Ambulatory (outpatient) hernia surgery including a new concept: introducing tension-free repair. *Int Surg*. 1986;71:1–4.
6. Usher FC, Ochsner J, Tuttle LL Jr. Use of Marlex mesh in the repair of incisional hernias. *Am Surg*. 1958;24:969–974.
7. The EU Hernia Trialists Collaboration. Mesh compared with non-mesh methods of open groin hernia repair: systematic review of randomized controlled trials. *Br J Surg*. 2000;87:854–859.
8. Stoppa RE. Errors, difficulties, and complications in hernia repairs using the GPRVS. *Probl Gen Surg*. 1995;12:139–148.
9. Amid PK, Shulman AG, Lichtenstein IL. A critical evaluation of the Lichtenstein tension-free hernioplasty. *Int Surg*. 1994;79:76–79.
10. Amid PK, Shulman AG, Lichtenstein, IL. Critical scrutiny of the open “tension-free” hernioplasty. *Am J Surg*. 1993; 165:369–371.
11. Friis E, Lindahl F. The tension-free hernioplasty in a randomized trial. *Am J Surg*. 1996;172:315–319.
12. Oghuzan karatepe et al; the comparison of preperitoneal and Lichtenstein repair for incarcerated groin hernias; A randomized controlled trial. *International jour. of surg*. 2008;6:189-192.
13. Nienhuijs,S. Staal, E.Keemers-Gels,M et al-pain after open preperitoneal repair v/s Listenstein repair:Results of a prospective randomized study.*World J Surg*. 2006;30:346-350.
14. McGillicuddy F. Prospective randomized comparison of the Shouldice and Lichtenstein hernia repair procedures. *Arch Surg*. 1998;133:974–978.
15. The EU Hernia Trialists Collaboration. Repair of groin hernia with synthetic mesh: meta-analysis of randomized controlled trials. *Ann Surg*. 2002;235:322–332.
16. Vrijland W, vanden Tol M, Luijendij RW, Hop WC, Busschbach JJ, deLange DC, van Geldere D, Rottier AB, Vegt PA, Ijzermans JN, Jeekel J. Randomized clinical trial of non-mesh versus mesh repair of primary inguinal hernia. *Br J Surg* 2002;89:293–297.
17. Shulman AG, Amid PK, Lichtenstein IL. Mesh between the oblique muscles is simple and effective in open hernioplasty. *Am Surg*. 1995;61:326–327.
18. Bringman S, Ramel S, Heikkinen TJ, Englund T, Westman B, Anderberg B. Tension-free inguinal hernia repair: TEP versus mesh-plug versus Lichtenstein: a prospective randomized controlled trial. *Ann Surg*. 2003;237:142–147.
19. MRC Laparoscopic Groin Hernia Trial Group. Laparoscopic versus open repair of groin hernia: a randomized comparison. *Lancet*. 1999;354:185–190.
20. Wright D, Paterson C, Scott N, Hair A, O'Dwyer P. Five-year follow-up of patients undergoing laparoscopic or open groin hernia repair: a randomized controlled trial. *Ann Surg*. 2002;235:333–337.
21. Lichtenstein IL, Shulman AG, Amid PK, Montllor MM. The tension free hernioplasty. *Am J Surg*. 1989;157:188–193.
22. Read RC, Barone GW, Hauer-Jensen M. Properitoneal prosthetic placement through the groin. *Surg Clin North Am*. 1993;73:545–555.
23. Crawford D, Phillips E. Laparoscopic totally extraperitoneal herniorrhaphy. In: Fitzgibbons RJ, Greenberg AG (eds) *Nyhus and Condon's Hernia*, 5th edition. JB Lippincott, Philadelphia, 2002; pp 2.
24. Amid PK. How to avoid recurrence in Lichtenstein tension-free hernioplasty. *Am J Surg*. 2002;184:259–260.
25. Amid PK, Lichtenstein IL. Long-term results and presentation of data on the Lichtenstein open tension-free hernioplasty. *Hernia*. 1998.
26. Lowham AS, Filipi CJ, Fitzgibbons RJ, Stoppa R, Wantz GE, Felix EL, Crafton WB. Mechanisms of hernia recurrence after preperitoneal mesh repair: traditional and laparoscopic *Ann Surg*. 1997;225:442–431.

Source of Support: Nil; **Conflict of Interest:** None

Submitted: 22-10-2016; **Published online:** 02-12-2016