

MR Spectroscopy in Space Occupying Lesions of the Brain: Does It Really Work?

Mehtab Ahmad¹, Mohd. Khalid², M.F. Huda³, S. Shamshad Ahmad⁴

ABSTRACT

Introduction: Magnetic resonance spectroscopy (MRS) is a rapidly developing field of neuroimaging that allows noninvasive in vivo analysis of metabolites. The present study was an attempt to characterise the lesions based on the biochemical information provided by MRS and assess its usefulness as a complimentary tool to Magnetic Resonance Imaging.

Material and Methods: This study comprised of cases with clinical diagnosis of intracranial space occupying lesion presenting with focal neurological symptoms such as epilepsy, paralysis, fever etc. in patients of any age or sex was included in the study group. Based on these criteria 60 patients with intracranial space occupying lesions detected on conventional MR Imaging were subjected to Magnetic Resonance Spectroscopy. The level of significance was determined using the Student 't' test. Probability value (P) <0.05 was regarded as significant.

Results: In the present study a significant difference was seen in the Cho/Cr and Cho/NAA ratios of low and high grades of gliomas (p < 0.05). Increasing Cho/Cr and Cho/NAA values were seen with increasing grade of malignancy. Diagnostic Accuracy of the MRI alone was found to be 78%. Diagnostic Accuracy of the MRI+MR Spectroscopy was found to be 84.6%.

Conclusion: The present study has shown that MRS can clearly distinguish the neoplastic intracranial lesions from the nonneoplastic lesions, as well as diagnose various lesions based on the metabolite spectrum and ratios. It has potential applications in grading of malignancies, in directing stereotactic biopsy and in follow up of postoperative patients.

Keywords: MR Spectroscopy, Space Occupying Lesions, Brain

INTRODUCTION

Magnetic resonance spectroscopy (MRS) is a rapidly developing field of neuroimaging that allows noninvasive in vivo analysis of metabolites. It selectively excites a small volume of tissue (voxel) using gradients, then records the free induction decay (FID) and produces a spectrum from the FID originating from that voxel.¹ The advantage of MRS has added to the diagnostic capabilities enabling tissue characterization based on their molecular composition. It provides information about cell proliferation, degradation, neuronal vitality and energy metabolism. Based on these characteristics, MRS attempts to differentiate between benign and malignant brain lesions. Currently there is widespread use of MRI to determine tumour extent for surgical and radiotherapy planning, as well as for post-therapy monitoring of tumour recurrence or progression to higher grade. MRI provides an initial diagnosis of an intracranial mass lesion with a success rate of 30–90% depending on tumour types 3 and 4.² The present study was an attempt to characterise the lesions based on the biochemical information provided by MRS and assess its usefulness as a complimentary tool to Magnetic Resonance Imaging.

MATERIAL AND METHODS

This study was performed in the Department of Radiodiagnosis, J.N. Medical College, AMU, Aligarh, which is one of the tertiary care hospitals in India. Cases with clinical diagnosis of intracranial space occupying lesion (ICSOL) and presenting with focal neurological symptoms such as epilepsy, paralysis, fever etc. in patients of any age or sex was included in the study group.

Magnetic resonance imaging was performed on a 1.5 Tesla whole body Superconducting System MAGNETOM Avanto 8-channel (Siemens, Erlangen, Germany) with spectroscopic capabilities using standard head coils (circularly polarized phased array head coil). After eliciting a detailed history and clinical general and neurological examination, magnetic resonance imaging was performed. Patients with diffuse disease the brain parenchyma, already been operated, requiring anaesthesia for the study, if an alternate diagnosis is made during the study or follow-up, all patients who had contraindications to undergo MRI and patients lost to follow up were excluded from the study. Due to the practical difficulties inherent to our set-up, children less than 3 years and those who needed sedation were also excluded from this study.

The examination was done after ruling out the presence of cardiac pacemakers, ear implants, metallic brain implants or any metallic bony prosthesis in these patients. All these patients were advised to clear the area of interest of removable metallic objects, if any, to avoid artifacts. Patient's comfort in the gantry was ensured before starting the sequences. Based on these criteria 60 patients with intracranial space occupying lesions detected on conventional MR Imaging were subjected to Magnetic Resonance Spectroscopy. As a control for the spectroscopic studies the normal spectrum obtained from the corresponding contra lateral or normal parts of the brain were taken.

The SVS spectra were used for metabolite ratio calculations. The area under the curve of a metabolite was considered as relative concentration (integral values) and was measured in terms of ratios. Measuring metabolite peak area ratios has the advantage of cancelling out the effects of general reduction in measured metabolite concentrations due to variations in cellular density. As reference standards, values of Cho/Cr > 1.5, NAA/

¹Assistant Professor, ²Professor, Department of Radiodiagnosis, ³Professor, Department of Surgery, ⁴Professor, Department of Pathology, JN Medical College, AMU, Aligarh, India

Corresponding author: Dr. Mehtab Ahmad, House No. 4/1309, New Sir Syed Nagar, Aligarh, (U.P.) India

How to cite this article: Mehtab Ahmad, Mohd. Khalid, M.F. Huda, S. Shamshad Ahmad. MR spectroscopy in space occupying lesions of the brain: does it really work?. International Journal of Contemporary Medical Research 2016;3(10):3099-3104.

Pattern	Granuloma	Abscess	Low Gr. Glioma	High Gr. Glioma and Metastasis	Meningioma	Schwannoma
Peripheral	10	3	2	21	0	0
Patchy	0	0	2	2	0	4
Central	0	0	1	1	1	0
Global	0	0	1	1	4	0

Table-1: Pattern of contrast enhancement

	Cho/Cr	Cho/NAA	NAA/Cr
Low grade Gliomas	1.53	1.76	1.32
High Grade Gliomas	6.27	5.81	1.57
Metastasis	3.46	5.14	1.22
Meningiomas	6.15	10.20	1.89
Infections	1.61	1.23	1.48
(Normal Values: Cho/Cr < 1.5; Cho/NAA < 0.8; NAA/Cr > 1.6)			

Table-2: Average Metabolite Ratios in the various lesions

Tumor	Total	Lactate	Lipids	Alanine
Low Grade Glioma	10	4	1	0
High Grade Glioma	14	11	8	0
Metastasis	10	6	7	0
Meningiomas	4	1	1	2

Table-3: Other Metabolites detected by Spectroscopy in tumors

Cr < 1.6 and Cho/NAA > 0.8 were taken as abnormal.

The metabolites and ratios assessed were:

- 1) NAA/Cr
- 2) Cho/Cr
- 3) Cho/NAA
- 4) Lactate and Lipids
- 5) Other prominent peaks in the spectrum.

Based on these ratios the lesions were characterised as:

1. Benign/malignant
2. Provisional diagnosis
3. Grade of malignancy (high and low)

All the patients were subsequently followed up for confirmation of diagnosis by biopsy or surgery. Patients with suspected infectious etiology were followed up by biopsy and imaging (response to treatment).

STATISTICAL ANALYSIS

The MR spectroscopic data in our study was assumed to follow normal distribution. The level of significance was determined using the Student 't' test. Probability value (P) <0.05 was regarded as significant.

RESULTS

Total of 73 patients were included in the study. On MR Spectroscopy, diagnostic spectrum was obtained in 69 patients (94%). In the remaining, spectrum obtained was of poor quality due to interference from hemorrhage within the lesion (in 1 case) or due to peripheral location close to bone (in 3 cases). 9 patients were lost to follow up without histopathological confirmation, so we included 60 patients in our observations and analysis. Majority of patients in the study belonged to the 30-45 year age group, constituting 28.33% of the cases. The minimum age was 4 years and the maximum was 75 years. The mean age of patients included in our study was 40.12 with a standard deviation of 19. The presentation of patients in the age group 0-15 years was more than shown, but due to technical

limitation of our set up, we were able to include a smaller number of patients. Majority of the patients in the study were males forming 58.3%. The most common presenting complaint was headache, seen in 71% of the patients, followed by seizures (46%). Symptoms of raised intracranial pressure and projectile vomiting, was seen in 30% of the patients. Weakness and hemiparesis was the major complaint in 18% of the patients. Fever in 8%, gait disturbances in 5%, personality changes in 2% and dementia was seen in 5% patients. The most common cause of intracranial space occupying lesions detected in the study was Gliomas, seen in 40 % of the cases. Next most common diagnosis was Metastasis, which was found in 17 % of the patients. Tumors constituted 77 % of the cases, forming the majority, while infections were found in 23% of the cases. Most common infective cause of intracranial space occupying lesions detected in the study was Tuberculoma, seen in 10 % of the cases, and comprised 44% of all infective causes.

Contrast enhancement

In patients of ICSOL, we performed contrast studies with gadolinium administration before Spectroscopy. The findings in the post contrast fat saturated T1 sequences were studied for intensity and pattern of contrast enhancement. Out of 60, 3 patients had no enhancement. 32 patients showed intense post contrast enhancement. 17 patients had moderate degree and 8 had mild degree of post contrast enhancement. This pattern is graphically represented in Graph 1.

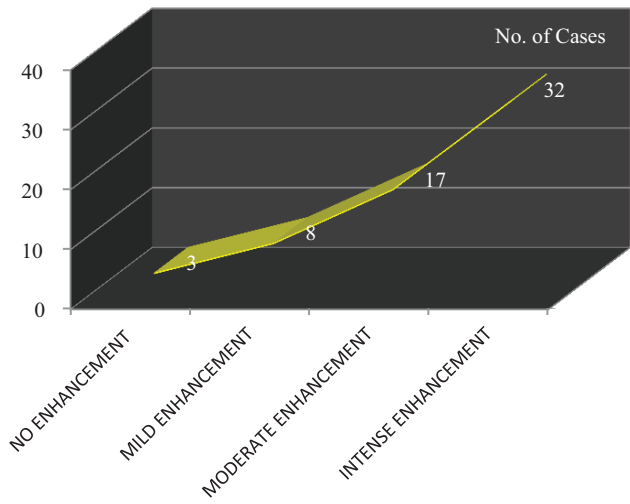
With regard to the pattern of enhancement, we observed patient who showed at least some enhancement and classified in one of the four basic patterns as shown in table 1.

On inverse analysis of Table 1, we observed that peripheral pattern was highly specific as well as sensitive for granulomatous lesions, brain abscesses and also for high grade malignant tumours, whereas global pattern of enhancement was highly specific for meningioma. Patchy and heterogenous enhancement pattern was rather non specific. This correlation is graphically depicted in Graph 2.

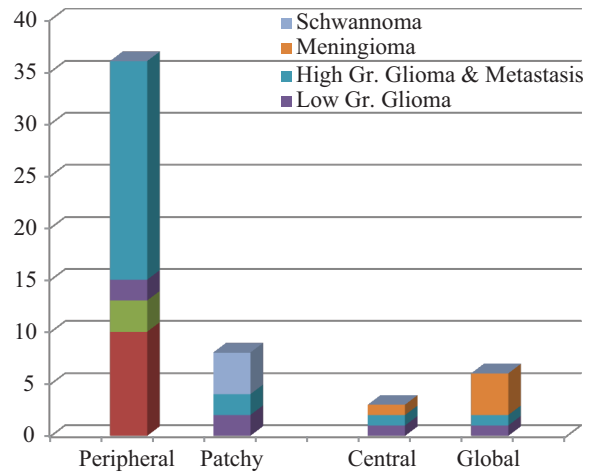
Metabolite ratios

Ratios of major metabolites were calculated after the analysis of spectra from the values relative to the integral. The Cho/Cr, Cho/NAA and NAA/Cr ratios are shown in table 2. Presence of other minor metabolites are shown in table 3. (Normal Values: Cho/Cr < 1.5; Cho/NAA < 0.8; NAA/Cr > 1.6) Mean Cho/ Cr ratio was high in high grade gliomas, metastasis and meningiomas, while it was normal in low grade gliomas and infections. Highest Mean Cho/Cr value was seen in high grade gliomas (6.27). Mean Cho/NAA ratio was high in all the lesions, with highest values seen in the meningiomas (10.20) and Gliomas (5.81). Mean NAA/Cr ratio was variable, and found to be inconclusive in most of the lesions, lowest values were seen in the metastasis (1.22) and meningioma (1.89).

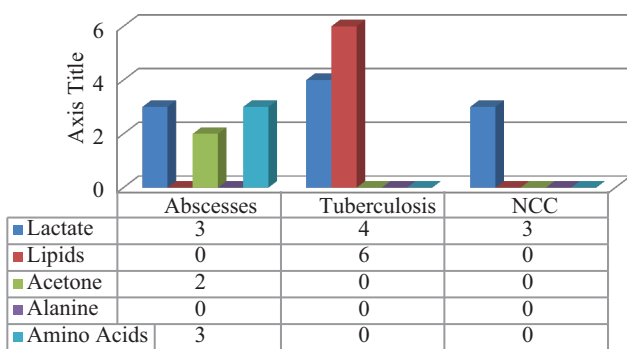
Lactate was elevated in more than 75% of all high grade



Graph-1: Intensity of contrast enhancement

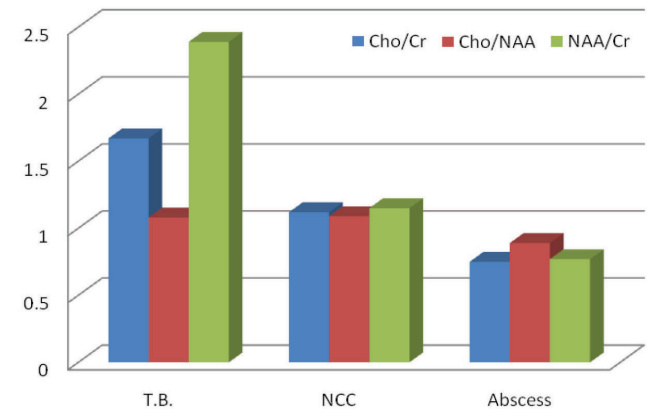


Graph-2: Pattern of contrast enhancement



Graph-3: Metabolites detected in infections

*Neurocysticercosis



Graph-4: Comparison of metabolite ratios in infections

Metabolite	Infections	S.E.M	Malignant	S.E.M.
Cho/Cr	1.6	±0.50	5.1	±1.9
P value < 0.05, significant				
Metabolite	Infections	S.E.M	Malignant	S.E.M.
Cho/NAA	1.2	±0.5	5.5	±2.9
P value < 0.05, significant				
Metabolite	Infections	S.E.M.	Malignant	S.E.M.
NAA/Cr	1.4	±0.4	1.4	±0.7
P value > 0.05, Not significant				
Metabolite	Low Grade	S.E.M.	High Grade	S.E.M.
Cho/Cr	1.5	±0.40	5.1	±1.9
P value < 0.001, significant				
Metabolite	Low Grade	S.E.M	High Grade	S.E.M
Cho/NAA	1.7	±1.2	5.5	±2.9
P value < 0.001, significant				
Metabolite	Low Grade	S.E.M.	High Grade	S.E.M.
NAA/Cr	1.3	±0.8	1.4	±0.7
P value > 0.05, Not significant				

Table-4: Comparison of metabolite Ratios in infections and malignant (Test of Significance: t test)

Gliomas and in 60% of Metastasis, while it was raised in only about 1/3rd of low grade gliomas and meningiomas. Lipid peak was found in the high grade Gliomas, particularly in grade IV gliomas (100%). Alanine was seen 50% of meningiomas, but not in any other malignancy (table 3). Figure 2 and figure 3 shows MRI, MRS and histopathological images of low and high grade gliomas.

Graph 3 shows Diagnostic spectrum obtained from 12

infections. Abscesses showed presence of lactate, acetone and aminoacid peaks, while acetone and aminoacids were not seen in Tuberculosis or NCC. Lipid peaks were seen in 100% of the cases of Tuberculosis, while being absent in neurocysticercosis. Mean choline, creatinine and NAA levels were found to be lower in the abscesses than in the other infectious lesions. The mean Cho/Cr and NAA/Cr ratios were higher in the tuberculous lesions than in NCC and Abscesses (Graph 4).

Brain Tumours	No of Patients diagnosed by MRI alone	No of Patients diagnosed by MR +MR spectroscopy	Final Histopathological Diagnosis	Accuracy	
				MRI	MRI + MRS
Low Grade Glioma	14	13	11	78.7	84.6
High Grade Glioma	10	11	14	71.4	78.8
Metastasis	12	12	10	83.3	83.3
Meningioma	3	4	4	75	100
Pituitary Macroadenoma	1	1	1	100	100
Schwannoma	4	4	4	100	100
Ependymoma	0	1	1	0	100
Central neurocytoma	0	0	1	0	0
Abscess	5	4	3	60	75
Tuberculoma	7	6	6	85	100
Neurocysticercosis	2	2	3	66.6	66.6
Hydatid Cyst	0	0	1	0	0
Toxoplasmosis	1	1	1	100	100

Table-5: Accuracy of MR Spectroscopy in diagnosis of brain tumours

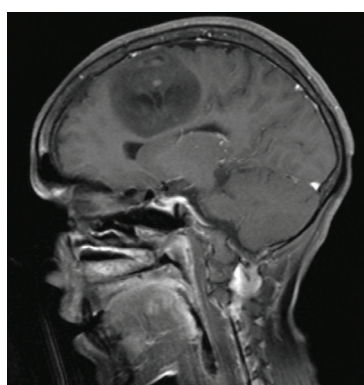


Figure-2a: Low Grade Glioma: altered signal intensity mass lesion with necrotic component in the medial part of right fronto-parietal region (para sagittal region) appearing isointense and the cystic component appearing hypointense on T1W with no significant perilesional edema.

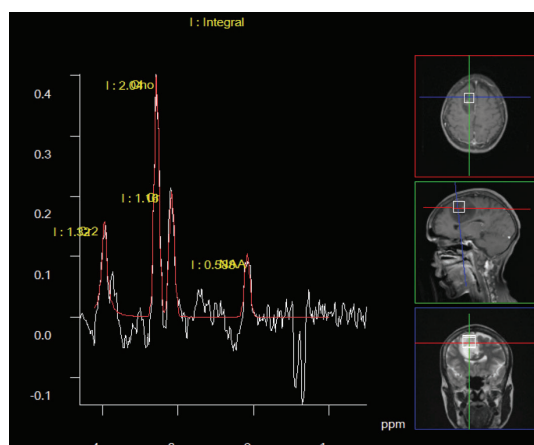


Figure-2b: Low Grade Glioma:MR spectroscopy shows elevated CHO peaks and raised CHO/NAA ratio.

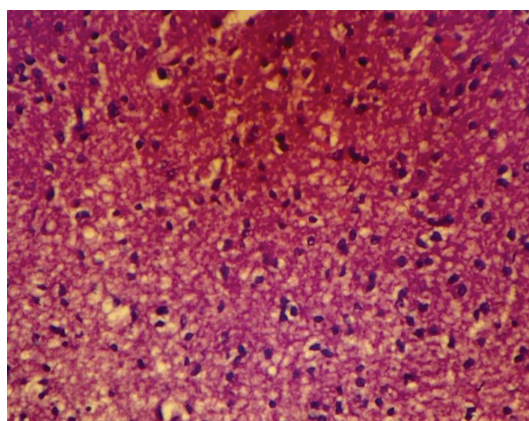


Figure-2c: Low Grade Glioma: Mild increase in glial cellularity, nuclear pleomorphism and network of fine astrocytic processes (X400, H and E).

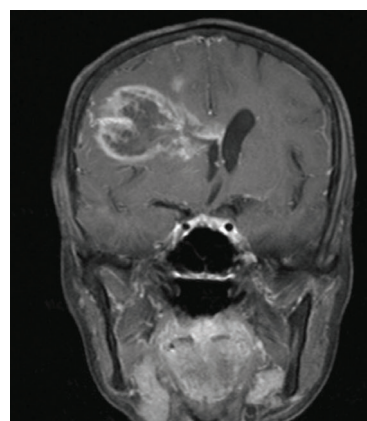

Figure-3a: High Grade glioma: A heterogeneous lesion with ill-defined margin involving RT fronto-parietal region lobe and extending into RT caudate with moderate amount of perilesional edema.

On Statistical analysis, table 4 shows level of significance and table 5 shows accuracy of MR Spectroscopy in diagnosis of brain tumours. Diagnostic Accuracy of the MRI alone was found to be 78%. Diagnostic Accuracy of the MRI+MR Spectroscopy was found to be 84.6%.

DISCUSSION

Magnetic Resonance Spectroscopy (MRS) is an analytical method used in chemistry that enables the identification

and quantification of metabolites in samples. It differs from conventional Magnetic Resonance Imaging (MRI) in that spectra provide physiological and chemical information instead of anatomy.³

In the present study, majority of the patients presenting with intracranial space occupying lesions were between 30 to 45 years of age group. The majority of patients were males, forming 58% of the study population. We found the predominant cause of intracranial space occupying lesions to be tumors,

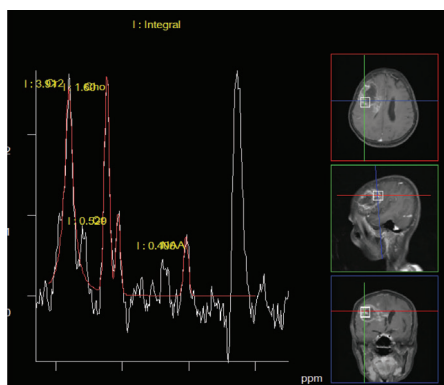


Figure-3b: High Grade glioma: On spectroscopy, the enhancing portion shows elevated choline and lactate peaks with decreased NAA levels. CHO/NAA ratio is grossly elevated suggestive of malignant lesion.

gliomas being the most prevalent (40%). Infections formed a relatively smaller group comprising 23%. Irrespective of cause, the predominant presenting symptom was headache, seen in about 70% of the patients, followed by seizures (33%). Even in infections, whether tuberculomas or abscesses, most of the patients presented with symptoms of raised intracranial tension or mass effect. Only few patients had fever as the presenting complaint. These observations were in concordance with the findings of Harada M et al⁴ and Klug N et al.⁵

The results of the present study reveal that the spectral pattern of tumors is markedly different from the normal brain and from other nonneoplastic lesions. We also concluded that histologically different lesions show different spectra, and that histologically similar lesions yield similar spectra with only minor differences. In general the results are consistent with the earlier studies on brain tumors.⁶⁻¹¹ Most of the tumors revealed an elevated Choline (Cho) peak along with a decrease in N-Acetyl Aspartate (NAA) resonance. However these resonances were normal or absent in the nonneoplastic lesions.

All malignant tumors, gliomas, metastasis and meningiomas, were characterized by increased Cho, decreased NAA and Creatinine (Cr) along with the presence of lactate (Lac), lactate and lipid (Lip), or lipid resonances in all the cases. Increased Cho has been observed in most brain tumors, attributed to the increased membrane turnover and cell proliferation.⁶ Presence of Cho was an essential feature of all gliomas, even when cystic; though the choline levels in cystic neoplasms were lower than in the solid lesions. The latter appears to be due to the degraded pool of Cho in the cystic fluid with no active membrane turnover. However though an elevated choline and hence, Cho/Cr, ratio was seen in the neoplasms, slightly high Choline level was also noted in few of the infectious lesions such as tuberculomas. In the in vivo proton MRS, the peak at 3.22 ppm is composed mainly of Cho, PC (phosphatidylcholine) and GPC (Glycerol-phosphatidylcholine). The choline pool is expected to increase in tumors because of an increased choline esterase activity which catalyses the first step of phospholipid biosynthesis. On the other hand increased PDEs (phosphodiesterases) containing GPC may be an indicator of the necrotic fraction in tumors as a consequence of phospholipid degradation.¹² Thus the increased Cho may either indicate increased cell proliferation (increased PC) or necrotic process (increased GPC). It is probable that the concentration of free Cho does not change in tumors as reported by Usenius JP et al.¹³ This may also explain the presence of

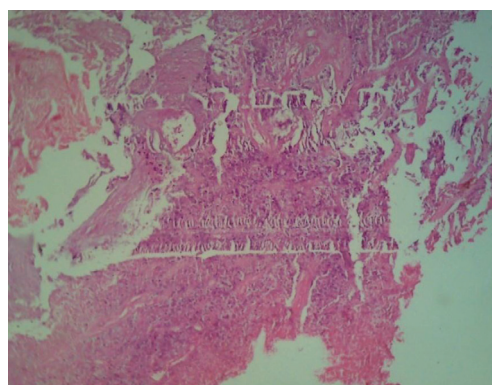


Figure-3c: High Grade glioma: Showing foci of necrosis (in right lower field) and clusters of malignant nuclei with endothelial cell proliferation seen in other areas. (X400, H and E).

increased choline in some infectious lesions in our study group. Presence of NAA as seen in most of the tumors has been attributed to the difference in the cellular composition and nature of the tumor.⁹ Higher grade tumors, especially with tissue necrosis, naturally have lower NAA levels due to neuronal loss or replacement.

Grading of gliomas has been done on the basis of NAA/Cho;^{9,10} Cho/Cr and NAA/Cr ratios.¹⁴ NAA/Cr and Cho/ Cr ratios have shown a consistency in predicting tumor grade,^{10,11} although Kugel H et al,⁹ have not found any significant difference in the metabolite ratios between various grades of tumors.

In the present study a significant difference was seen in the Cho/Cr and Cho/NAA ratios of low and high grades of gliomas ($p < 0.05$). Increasing Cho/Cr and Cho/NAA values were seen with increasing grade of malignancy. However, we did not find any significant difference in the NAA/Cr levels between high and low grades of gliomas. NAA/Cr ratios in various grades gliomas, metastasis and infections showed overlapping values. From the present study it can be concluded that Cho/Cr and Cho/NAA ratios can be used in the grading of malignancies as suggested by Kostas N et al,¹⁵ Sutton et al¹⁰ Ott et al.¹¹ Of these ratios, Cho/NAA appears to be the more significant in determining tumor grade. However, we did not find NAA/Cr to be significant. Lactate may be formed by anaerobic glycolysis in tumors with hypoxia.⁸ Malignant tumors were found to have a higher Lac/Cr ratio than benign tumors. High grade tumours showed the presence of lactate as compared to low grade tumours which did not show its presence. Hence the presence of lactate appears to correlate significantly with grade of malignancy i.e. higher levels of lactate correlated with higher grade tumours. Similar results were obtained by Fulham MJ et al⁸ in their study of brain tumours.

Lipid resonances have been observed in high grade gliomas in in-vivo studies using different echo times.¹⁵ Poptani H et al¹⁶ concluded that the presence of lipid signals may be useful in the discrimination of low and high grade tumors. In the present study, lipid signals were seen in tumors with and without visible necrosis. Only one of the low grade gliomas showed presence of lipids, while it was present in 60% cases of high grade gliomas, and 100% cases of GBM, all of which showed varying levels of necrosis on histological examination. Hence it can be concluded that lipid resonances indicate necrosis, and presence of lipid correlates with higher degrees of malignancy.

From the present study it is evident that Cho/NAA and Cho/

Cr ratios can be used to determine the histological grade of malignancy. But when used alone, they may prove inconclusive, especially in case of cystic or necrotic gliomas. However when combined with the presence or absence of lactate and lipid signals, the grade of malignancy can be predicted with greater accuracy.¹⁷

Reduced or absent NAA peak along with variable signal intensities from Cho, Cr, Lac and Lip have been observed in metastasis.^{8,9} As metastasis often contain non neuronal tissue, a low or absent NAA peak is expected. However in most cases a NAA peak is obtained. This may be explained by nature of the tumor, that is, NAA may be seen if the tumor grows invasively or is unable to displace all the neurons or due to partial volume from adjoining brain tissue. Kugel H et al⁹ have observed increased lipid signals in metastasis. Most studies have failed to demonstrate any spectral variations in the different histological types of metastasis, and have not found any difference in metastasis versus glioblastomas or abscesses based on MR Spectroscopy. In concordance with these observations, the present study also revealed spectral patterns in metastasis similar to and hence not differentiable from high grade gliomas. The presence of alanine (Ala) is specific for meningiomas.^{6,17} Kugel H et al⁹ however found Ala in only 62.5% of the meningiomas examined. In the present study, a prominent Ala peak was seen in two of the four cases of meningiomas (50%), along with strong resonance of Cho. The NAA and Cr levels were low, giving a high Cho/NAA and increased Cho/Cr ratios. Alanine peak was not observed in any other space occupying lesion, so specificity of Alanine for meningiomas was confirmed.

Proton MRS has been used to predict the presence of histopathological features important for brain tumor diagnosis that can be used to plan stereotaxic biopsies and selective tumor resections. Dowling C et al¹⁸ found that areas of abnormal spectrum indicating higher degree of malignancy within a lesion correlated with regions of viable cancer. This may be valuable for guiding surgical biopsies and focal therapy.

CONCLUSION

The present study has shown that MRS can clearly distinguish the neoplastic intracranial lesions from the nonneoplastic lesions, as well as diagnose various lesions based on the metabolite spectrum and ratios. It has potential applications in grading of malignancies, in directing stereotactic biopsy and in follow up of postoperative patients. It complements the information obtained from conventional MR imaging and contrast studies, proving particularly useful when these studies are inconclusive.

REFERENCES

1. Mandal PK. Magnetic Resonance Spectroscopy (MRS) and its application in Alzheimer's disease. *Concepts Magn Reson Part A*. 2007;30A:40–64.
2. Abdel-Monem ND, Manal EB, Manal H, Noha S. Magnetic resonance spectroscopy and diffusion imaging in the evaluation of neoplastic brain lesions. *The Egyptian Journal of Radiology and Nuclear Medicine*. 2014;45:485-93.
3. Bertholdo D, Watcharakorn A, Castillo M. Brain proton magnetic resonance spectroscopy: introduction and overview. *Neuroimaging Clin N Am*. 2013;23:359-80.

4. Harada M, Tanouchi M, Miyoshi H, Nishitani H, Kannuki S: Brain abscess observed by localized proton magnetic resonance spectroscopy. *Magn Reson Imaging*. 1994;12:1269–1274.
5. Klug N, Ellams ID: Difficulties in the differential diagnosis of brain abscesses. *Adv Neurosurg*. 1981;9:61–67.
6. Bruhn H, Frahm J, Gyngell ML, et al. Noninvasive differentiation of tumors with use of localized H-1 MR spectroscopy in vivo: initial experience in patients with cerebral tumors. *Radiology*. 1989;172:541–548.
7. Arnold DL, Emrich JF, Shoubridge EA, Villemure JG, Feindel W. Characterization of astrocytomas, meningiomas, and pituitary adenomas by phosphorus magnetic resonance spectroscopy. *J Neurosurg*. 1991;74:447-53.
8. Fulhan MJ, Bizzi A, Dietz MJ. Mapping of brain tumour metabolites with proton spectroscopic imaging: clinical relevance. *Radiology*. 1996;185:685-686.
9. Kugel H, Heindel W, Ernestus RI, Bunke J, du Mesnil R, Friedmann G. Human brain tumours: spectral patterns detected with localized H-1 MR spectroscopy. *Radiology*. 2008;183:701-9.
10. Sutton LN, Wang ZJ, Wehrli SL, Marwaha S, Molloy P, Phillips PC, Zimmerman RA. Proton Spectroscopy of Suprasellar Tumours in Pediatric Patients; *Neurosurgery*. 2007;41:388-395.
11. Ott D, Henning J, Ernst T. Human brain tumours: assessment with in vivo proton MR spectroscopy. *Radiology*. 2007; 186:745-752.
12. Cabello JR, Cohen JS. Phospholipid metabolites as indicators of cancer cell function. *NMR Biomed* 1992;5:226–233.
13. Usenius JP, Vainio P, Hernesniemi J, Kauppinen RA. Choline-containing compounds in human astrocytomas studied by H-1 NMR spectroscopy in vivo and in vitro. *J Neurochem*. 1994;63:1538-43.
14. Howe FA, Barton SJ, Cudlip SA, et al. Metabolic profiles of human brain tumors using quantitative in vivo 1H Magnetic resonance spectroscopy. *Magn Reson Med*. 2003;49:223–232.
15. Kostas N., Fountas; Proton Magnetic Resonance Spectroscopic Imaging Can Predict Length of Survival in Patients with Supratentorial Gliomas. *Neurosurgery*. 2004;55:257-258.
16. Poptani H, Gupta RK, Roy R, Samuel S, Angelliko G, Casillas G. Characterization of intracranial mass lesions with in vivo proton MR spectroscopy. *AJNR*. 1995;16:1593-603.
17. Poptani H, Gupta RK, Jain VK, Roy R, Pandey R. Cystic intracranial mass lesions: possible role of in vivo MR spectroscopy in its differential diagnosis. *Magn Reson Imaging*. 1995;13:1019-29.
18. Dowling C, Bollen AW, Stanley L, Hawk U. Preoperative proton MR spectroscopic imaging of brain tumours: Correlation with histopathologic analysis of resection specimens. *AJNR*. 2001;22:604-612.

Source of Support: Nil; **Conflict of Interest:** None

Submitted: 16-08-2016; **Published online:** 15-10-2016