

Is Histopathologic Evaluation of the Dental Follicle a Need of Time???

Rozina Vishnani¹, Pankaj B. Patil², Nupura Vibhute³, Nilesh Patil⁴, Mouneshkumar C.D⁴, Abhijit Sande⁵

ABSTRACT

Introduction: Previous studies have reported that dental follicle associated with third molar may undergo cystic degeneration or neoplastic transformation leading to formation of odontogenic cysts and tumors. The presence of pericoronal pathosis is generally accepted reason for their extraction. "Radiographic pathology" is define as a Pericoronal radiolucency measuring about 2.5 mm or larger in any dimension. The aim of the study was to evaluate Histopathological changes in Dental Follicle associated with Impacted Mandibular Third Molar.

Material and Methods: This study was conducted in Department of Oral and Maxillofacial Surgery between February 2014 and May 2014, total 50 patients were included in this study aged between 17 to 50 yrs age, out of which 29 males and 21 females who were undergone surgical removal of impacted mandibular third molar showing pericoronal radiolucency less than 2.4 mm. The dental follicle were detached from teeth carefully and sent for histopathological evaluation to the Department of Oral Pathology. The types of pathological changes were recorded based on histopathological report.

Results: Out of 50 patients studied, the results obtained from histopathological reports showed that incidence of chronic nonspecific inflammation (58%), incidence of normal dental follicle (28%) while incidence of cystic changes showed (14%)

Conclusion: Considering the significant incidence of pathological changes in dental follicular tissue, histopathological evaluation of dental follicle is routinely required to prevent any pathological changes in future.

Keyword: Tooth Germ; Dental Follicle; Follicular space; Tooth Extraction; Oral Surgical Procedures; Third molar.

in oral cavity. Removal of impacted mandibular third molar is common procedure performed in oral surgery. Indications for removal of third molar have generated much discussion in dentistry. Some clinicians advocate prophylactic removal before pathologic changes develop while others propose observation and periodic monitoring.

Third molar impaction is a major problem in dentistry. Figures ranging from 9.5% to 39% have been quoted in different populations worldwide. In the Asian Indian population the most common position of impacted third molar is vertical (42%) followed by mesioangular (31%), distoangular (27%) and rarely horizontal.¹³ The development of impacted third molars normally spans several years and, problems often develop gradually. Nevertheless, these gradual changes can cause sudden and severe pain, discomfort, pericoronitis, headache and swelling. Some type of pathologic changes like dentigerous cyst, internal resorption, caries, periodontal ligament damage, bone loss distal to second molar and pressure resorption of second molar can be expected eventually in approximately 12% of impacted third molar population and 1.82% of the general population over sustained period of time.¹⁴ The pathologic changes are common in mandibular third molar (8%) compared to maxillary third molars (5.2%). While not every impacted third molar actually causes clinically significant problem, each has a potential.¹⁵

This research includes histopathological evaluation of the dental follicle after mandibular third molar surgery; we have included 50 patients with unilateral impacted or partially erupted mandibular third molar in age group 17 to 50 years showing pericoronal radiolucency less than 2.4mm. After surgical removal of mandibular third molar, dental follicle was carefully detached from teeth and kept in 10% formalin solution and sent to Department of Oral pathology and microbiology for histopathological evaluation.

Numerous justification for and against prophylactic extraction of asymptomatic impacted third molar had been offered in the past leading to confusion in the mind of practitioners. Numerous studies with conflicting results were conducted on potential of follicular tissues to undergo

INTRODUCTION

Dental follicle originates from odontogenic ectomesenchyme, is part of the tooth germ and is physiologically involved in the formation of cementum, the periodontal ligament, and alveolar bone. Once the tooth has fully developed inside the jaw, the coronal part of the follicle is termed dental/pericoronal sac or follicle and occasionally persists adjacent to the crown of unerupted or impacted teeth.¹ It is composed of fibrous connective tissue and frequently contains epithelial residues of odontogenesis, which could be the starting point of pathology.²⁻⁴ Radiographically, it appears as a thin pericoronal radiolucency considered normal by some authors when it is less than 3mm thick^{5,6} and by others when it is no thicker than 2.5mm.⁷ Apart from its important role in eruption physiology, previous studies have reported that the dental follicle may undergo cystic degeneration and/or neoplastic transformation.² Recent studies have reported pathological changes in dental follicle of up to 2.5mm.^{2,8-12} Mandibular third molar are most commonly impacted teeth

¹Intern, ²Assistant Professor, ⁴Reader, Department of Oral and Maxillofacial Surgery, ⁵Assistant Professor, Department of Oral Medicine and Radiology, ³Reader, Department of Oral Pathology and Microbiology, School of Dental Sciences, Krishna Institute of Medical Sciences Deemed University, Karad, Maharashtra, India

Corresponding author: Ms. Rozina Vishnani, B – 41 Shaheed Society State Bank Road, Yavatmal 445001, Maharashtra, India

How to cite this article: Rozina Vishnani, Pankaj B. Patil, Nupura Vibhute, Nilesh Patil, Mouneshkumar C.D, Abhijit Sande. Is histopathologic evaluation of the dental follicle a need of time???. International Journal of Contemporary Medical Research 2016;3(5):1434-1436.

pathological alteration.¹⁶ Hence, this study aimed to evaluate the histopathologic changes in dental follicle associated with impacted mandibular third molars.

MATERIAL AND METHODS

50 patients who met the inclusion and exclusion criteria were randomly selected from the OPD in Department of Oral and Maxillofacial Surgery between February 2014 and May 2014. The Ethical clearance was obtained from ethical committee in January 2015. Out of the total 50 patients included (based on inclusion and exclusion criteria), 29 were males and 21 were females who underwent surgical removal of impacted mandibular. A written informed consent was taken from the patient before performing Surgical procedure.

Inclusion criteria

Healthy patient in age group 17 to 50 years.
Pericoronal radiolucency should be less than 2.4 mm.

Exclusion criteria

Medically compromised patient.
Pericoronal radiolucency > 2.4 mm.
The dental follicles were detached from teeth carefully and were kept in 10% formalin solution and sent for histopathological evaluation to the Department of Oral Pathology. The types of pathological changes were recorded based on histopathological report.

RESULT

A total of 50 dental follicles were histopathologically evaluated. The age of these patients ranged from 17 to 50 years, 29 of them being male patients and 21 female. The results obtained from histopathological reports showed that incidence of chronic nonspecific inflammation (58%), incidence of normal dental follicle (28%) while incidence of cystic changes showed (14%).

On comparison of age group affected by impacted teeth between male and female $t = 4.771$ and $p < 0.0001$ (extremely significant). Thus female with younger age have greater incidence of impacted mandibular third molar (Table-1).

Out of 50 cases 32 cases were of impacted 38 out of which 16 were male and 16 were female and 18 cases of impacted 48 out of which 13 were male and 5 were female patients. $p = 0.2188$ (not significant) chi square value = 1.512 Thus both sides are equally affected.

To determine the mean follicular size ranging from 1 to 2.4 mm following test were done to find any significant radiographic follicular size. For 38 male to female comparison $t = 0.5842$, $p = 0.5634$ (not significant). For 48 male to female comparison $t = 0.5842$, $p = 0.0932$ (not significant) Male comparison $t = 0.6496$, $p = 0.5215$ (not significant). Female comparison $t = 2.029$ $p = 0.0568$ (not significant). For all male to female comparison $t = 1.06$ $p = 0.2942$ (not significant). Overall comparison between 38 and 48 $t = 1.410$ $p = 0.1650$ (not significant). Thus there was no significantly comparable radiographic follicular size (Table-2).

$p = 0.4137$ (not significant) chi square = 1.765
The results obtained from histo-pathological reports showed that incidence of chronic nonspecific inflammation in 29 cases (58%), incidence of normal dental follicle in 14 cases (28%) while incidence of cystic changes in 7 cases (14%). p

= 0.4137 (not significant) chi square = 1.765. thus there was no significant cystic changes (Table-3) (Figure-1)

DISCUSSION

The presence of pericoronal pathosis is generally the common reason for the removal of third molars. Pericoronal space surrounding the impacted third molar may represent either a normal or an enlarged dental follicle but alternatively may represent a pathologic entity most commonly a dentigerous cyst.¹⁷

Several studies have suggested that the follicular tissue associated with these teeth may have the potential for transforming into cystic and/or neoplastic lesions. Various pathological changes like odontogenic keratocyst, dentigerous cyst, calcifying epithelial odontogenic cyst, odontogenic myxoma etc have been reported.¹⁶ However many of these changes are not detectable during clinical or

Age	Male	Female
Minimum	24	19
Maximum	49	47
Mean	35.79	28.09
Standard Deviation	73.50	7.236
$t = 4.771$ $p < 0.0001$ (extremely significant)		

Table-1: comparison of age between male and female

Impacted Tooth No.	Mean±Standard Deviation of Radiographic Follicular Size		Total
	Male	Female	
38	1.268+0.020	1.231+0.518	1.25+0.1796
48	1.223+0.169	1.08+0.083	1.177+0.162
All	1.274+0.188	1.195+0.516	1.224+0.1756

Table-2: Mean radiographic follicular size ranging between 1mm to 2.4mm

Histopathological Diagnosis	Impacted Tooth No.		Total
	38	48	
Chronic nonspecific inflammation	18	11	29
Normal Dental follicle	8	6	14
Cyst	6	1	7

Table-3: Histopathological diagnosis

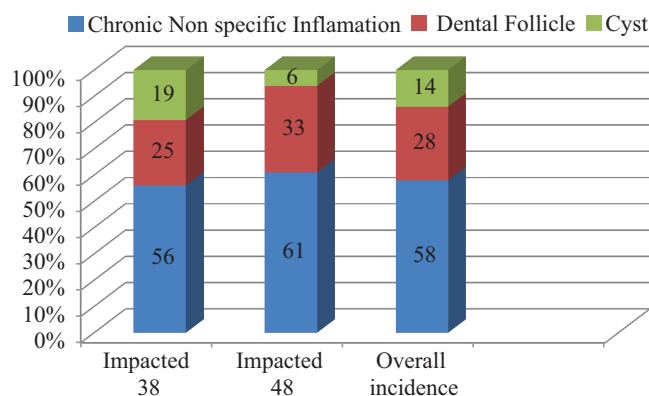


Figure-1: Incidence of chronic nonspecific inflammation, dental follicle and cyst associated with impacted 38, impacted 48 and overall incidence

radiographic examination while they may be found through microscopic analysis. Hence, histopathological evaluation of dental follicle is mostly recommended to evaluate the various cystic changes associated with impacted third molars.

In this study histopathological evaluation was carried out of 50 dental follicles from impacted mandibular third molar, which were having radiographic radiolucency less than 2.4mm.

In the present study we analyzed the pathologic changes in both asymptomatic as well as symptomatic cases (showing pericoronitis/chronic irritation).

21 follicles showed odontogenic tissue out of which 14 follicles showed presence of reduced enamel epithelium and underlying connective tissue displayed Odontogenic islands and few areas of ossification, without evidence of cystic lining. These follicles were histopathologically diagnosed as normal dental follicle. While 4 follicles showed presence of 2-3 cell layers of flattened cells, with connective tissue showing odontogenic islands in fibro cellular stroma, diagnosed as dentigerous cyst. The remaining 3 specimens showed presence of epithelial lining of stratified squamous type arranged in arcading pattern, underlying connective tissue showed presence of chronic inflammatory cell infiltration in fibro cellular stroma, diagnosed as radicular cyst.

In this study we found 7 cases of cystic changes out of which 4 cases were reported as dentigerous cyst while 3 cases seen as radicular cyst. Out of 50 cases studied, 29 cases showed chronic nonspecific inflammation suggestive of presence of inflammation in pericoronal region. 14 cases were showing normal routine dental follicle.

Previous similar studies conducted showed variable values ranging from the high rate of cystic changes in Rakprasitkul et al (2001)⁸ (58.65% (dentigerous cyst, 50.96%; chronic nonspecific inflammatory tissue, 4.81 %; odontogenic keratocyst, 1.92%; ameloblastoma, 0.96%).) to low as in Monica Yadav et al¹⁶ (2001) study (4.44%).

Comparing the present study with past studies conducted we have intermediate results (14%).

After extraction of impacted tooth, the follicles are normally discarded and not sent for histopathological examination. In view of results in our study we recommend all tissue extracted with impacted teeth should be sent for its histopathological evaluation.

CONCLUSION

Considering the significant incidence of pathological changes in dental follicular tissue, histopathological evaluation of dental follicle is routinely required to prevent any pathological changes in future. We propose more such studies with greater sample size and coupled with immunohistochemical investigations of the same are the need of the hour.

REFERENCE

1. Nanci, Ten Cate's Oral Histology. Development, Structure and Function, Mosby Elsevier, St Louis, Mo, USA, 7th edition, 2008.
2. J. W. Glosser and J. H. Campbell. Pathologic change in soft tissues associated with radiographically "normal" third molar impactions. British Journal of Oral and Maxillofacial

Surgery. 1999;37:259-260.

3. A. E. Curran, D. D. Damm, and J. F. Drummond. Pathologically significant pericoronal lesions in adults: histopathologic evaluation. Journal of Oral and Maxillofacial Surgery. 2002;60:613-617.
4. C. da Silva Baumgart, I. da Silva Lauxen, M. S. Filho, and O.F. de Quadros. Epidermal growth factor receptor distribution in pericoronal follicles: relationship with the origin of odontogenic cysts and tumors. Oral Surgery, Oral Medicine, Oral Pathology, Oral Radiology and Endodontology. 2007;103:240-245.
5. J. Kim, G. L. Ellis, and E. Eisenberg. Dental follicular tissue: misinterpretation as odontogenic tumors. Journal of Oral and Maxillofacial Surgery. 1993;51:762-767.
6. M. Edamatsu, H. Kumamoto, K. Ooya, and S. Echigo. Apoptosis-related factors in the epithelial components of dental follicles and dentigerous cysts associated with impacted third molars of the mandible. Oral Surgery, Oral Medicine, Oral Pathology, Oral Radiology, and Endodontics. 2005;99:17-23.
7. S. Eliasson and A. Heimdahl. Pathological changes related to long-term impaction of third molars. A radiographic study. International Journal of Oral and Maxillofacial Surgery. 1989;18:210-212.
8. S. Rakprasitkul. Pathologic changes in the pericoronal tissues of unerupted third molars. Quintessence International. 2001;32:633-638.
9. T. Baykul, A. A. Saglam, U. Aydin, and K. Bas, ak. Incidence of cystic changes in radiographically normal impacted lower third molar follicles. Oral Surgery, Oral Medicine, Oral Pathology, Oral Radiology and Endodontology. 2005;99:542-545.
10. G. Yildirim, H. Ataoğlu, A. Mihmanli, D. Kiziloğlu, and M. C. Avunduk. Pathologic changes in soft tissues associated with asymptomatic impacted third molars. Oral Surgery, Oral Medicine, Oral Pathology, Oral Radiology and Endodontology. 2008;106:838-842.
11. G. H. L. Saravana and K. Subhashraj. Cystic changes in dental follicle associated with radiographically normal impacted mandibular third molar. British Journal of Oral and Maxillofacial Surgery. 2008;46:552-553.
12. V. S. Kotrashetti, A. D. Kale, S. S. Bhalaerao, and S. R. Hallikeremath. Histopathologic changes in soft tissue associated with radiographically normal impacted third molars. Indian Journal of Dental Research. 2010;21:385-390.
13. Sandhu S, Kaur T "Radiographic evaluation of the status of third molars in the Asian Indian students", J of Oral Maxillofac Surg. 2005;63:640-345.
14. Stanley HR, Alattar M, Collett WK, Stringfellow HR Jr, Spiegel EH. Pathologic sequelae of 'neglected' impacted third molars. J Oral Pathol. 1988;17:113-17.
15. Eliasson S, Hemdahl A, Nordenran A. Pathologic changes related to long term impaction of third molars. A radiographic study. Int J Oral Maxillofac Surg. 1989;18:210-12.
16. Monica Yadav, Meghna S.M, Atul Desmukh, Pournima Godge. The wisdom behind third molar extraction: A clinicopathologic study. Int.J. Oral and Maxillofacial Pathology. 2011;2:7-12.
17. Tom D Daley, George P. Wysocki. The small Dentigerous cyst-A diagnostic dilemma. Oral Surg Oral Med Oral Pathol. 1995;79:77-81.

Source of Support: Nil; **Conflict of Interest:** None

Submitted: 22-03-2016; **Published online:** 22-04-2016