

CBCT Guided Flapless Implant Rehabilitation of A Missing Mandibular Second Molar-Case Report and Review of Literature

Sneha Mary Mathew¹, Sanjay Vasudevan², Ajay Reddy P³, Rajani Kumar G³, Mayuri Ganesh¹

ABSTRACT

Introduction: It is critical for clinicians to minimize trauma to the patient and produce acceptable aesthetic outcomes while understanding patients hard and soft tissue conditions. Minimally invasive surgeries have now become the norm eliminating the need for a second surgery, highlighting patient comfort in treatment planning when rehabilitating with implants.

Case report: A 51 year old male patient who reported with a missing second mandibular molar in the fourth quadrant was evaluated using cone beam computed tomography (CBCT) and successfully treated with a flapless implant procedure followed by prosthetic crown placement.

Conclusion: In the past decade due to technological advancements and introduction of the CBCT and dental implant planning software, the flapless implant surgeries have gained popularity. This procedure causes minimal trauma to the supporting structures and provides long term stability.

Keywords: flapless implant, CBCT, minimally invasive, DMLS.

INTRODUCTION

Every patient is unique and it is of paramount importance to make surgeries as comfortable and as minimally invasive as possible. Last few years have seen many modifications to the classical crestal incision technique advocated by Dr. Per Ingvar Branemark. An innovative technique of implant placement without elevating a mucoperiosteal flap, described as flapless implant surgery, has been introduced recently. It has the distinct advantage of minimal bone loss and increased patient comfort.

When dental implants are placed after reflecting soft tissue flaps, there is some bone resorption during the initial phase of healing in the crestal area of the alveolar bone.¹ Flapless surgery involves accessing the bone by either (a) punching out a small amount of soft tissue, just the amount required for osteotomy preparation and implant placement^{2,3} or (b) preparing the osteotomy site by drilling directly through the soft tissue.^{4,5}

In the punch technique, the gingiva at the centre of the implant site is removed using a surgical template and tissue punch. The incised gingival tissue is removed with a curette or mosquito haemostat.

In the second technique, the area of placement of implant is marked on the soft tissue using a surgical template and then the osteotomy site preparation is done with conventional drills, drilling directly through the soft tissue in the marked area.

Keratinized, attached, and non mobile tissue of at least 5 mm must be present, because the flapless procedure requires the actual removal of some of the tissue. This is essential to pro-

vide the epithelial and connective tissue elements needed for development of circumferential biological width to preserve soft tissue integration, without sacrificing the underlying peri-implant supporting bone.

Bone width of at least 4.5 mm must be available without undercuts of more than 15°. Since visibility is limited when using the flapless technique, it is difficult to ensure that the implant is positioned in the centre of the crestal bone. Greater ridge width offers the practitioner an extra margin of safety. Mild swelling and discomfort is seen in every surgical procedure. Using the flapless approach, we minimize the surgical trauma.

CASE REPORT

The patient, who was a 51 year old male, visited the Periodontics department, Army college of dental sciences, India with the chief complaint of desiring fixed replacement of missing right lower second molar. The tooth was lost due to decay 2 years ago. Overall examination was done and it was non contributory. Patient was explained about all the options and he opted to go for the implant. He was in good health and had adequate mesio distal and bucco lingual width with adequate attached gingiva. The periodontium of the patient was healthy. A CBCT and complete blood picture was advised, IOPA was also taken. Impressions were made to fabricate the stent for accurate implant site determination. Based on the CBCT analysis (Figure 1) of quantity, quality and morphology of bone a 4.2 × 11.5 mm (Adin Dental Implant System Ltd, Afula, Israel) root form implant was selected to be placed with the flapless technique.

Extra and intra oral antiseptics were done. Local anesthetic (xylocaine 2% with epinephrine 1:80,000, Indoco) was administered. The stent was placed at the site and marking on the soft tissue done using a round bur. A tissue punch (Figure 2) was used to perforate the tissue and sequential drilling was done to prepare osteotomy site. The implant was wrenched into place with a final torque of 45 N/cm² with good primary stability. Healing abutment was placed on the implant.

Patient was prescribed analgesics and antibiotics and in-

¹Post Graduate Student, ²Professor and Head of Department, ³Reader, Department of Pedodontics, Army College of Dental Sciences, Secunderabad, India

Corresponding author: Dr. Sneha Mary Mathew, Post Graduate Student, Department of Periodontics, Army College of Dental Sciences, Jai Jawahar Nagar, Chennaiapur – CRPF Road, Secunderabad- 500087, Telangana, India.

How to cite this article: Sneha Mary Mathew, Sanjay Vasudevan, Ajay Reddy P, Rajani Kumar G, Mayuri Ganesh. CBCT guided flapless implant rehabilitation of a missing mandibular second molar-case report and review of literature. International Journal of Contemporary Medical Research 2016;3(5):1314-1316.

structed to use 0.2% chlorhexidine rinse twice daily for 1 week. He was instructed to apply ice packs for the first 12 hours, soft diet for 3 days.

Patient was recalled after 1 week. He reported no discomfort and healing was uneventful with a smooth healthy gingival cuff formed around the healing abutment. Patient was motivated about oral hygiene instructions and recalled every month for review.

We waited for 4 months for complete osseointegration to occur and impressions were made using polyvinyl siloxane impression material (Aquasil putty and light body, Dentsply, Mannheim, Germany). Jig trial was done before final cementation of the prosthesis. Crown was fabricated by using the direct metal laser sintering (DMLS) process (Dentcare labs, Muvattupuzha, India). Final cementation was done with the prosthesis (Figures 3) providing good function. Patient was recalled every 3 months for implant and soft and hard tissue assessment. Patient was satisfied and implant was in good health with no sign of infection at the end of 1 year (Figure 4).

DISCUSSION

The final result of this case proves that flapless implant placement is an excellent treatment option in providing patient comfort, eliminating second surgery, preservation of blood circulation and maintaining of bone and surrounding soft tissues integrity. Although all cases cannot be treated with this protocol; certain prerequisites need to be met for a functional

and aesthetic result to be achieved.

Since flapless implant placement is mostly a “blind” surgical technique, placement of implants must be done with caution. Angulation is critical to prevent perforation of both lingual and buccal cortical plates, especially on the mandibular lingual molar area and the anterior maxilla. Proper patient selection with adequate width of bone available for implant placement will limit any complications.

Periosteum is the vital reactive layer of connective tissue covering the cortical bone. Minimal stripping of periosteum, consistent with sound surgical principles of access and soft tissue management, is an important consideration in implantology.

Hahn⁶ stated that avoiding the reflection of a flap results in less postoperative swelling and patient discomfort. Leaving the periosteum intact on the buccal and lingual aspects of the ridge assures a good blood supply to the site, reducing the likelihood of bone resorption.

Jeong et al.⁷ conducted an experimental study to examine the effect of flapless implant surgery on crestal bone loss and osseointegration in a canine mandible model and concluded that flapless surgery yielded superior results. Fortin et al.⁸ compared the amount of pain experienced with the two techniques using a Visual Analogue Scale and also by assessing the number of analgesics taken postoperatively from the day of surgery to six days after surgery. The results showed that pain decreased faster and also that the number of patients who felt no pain was higher with the flapless procedure. Campelo

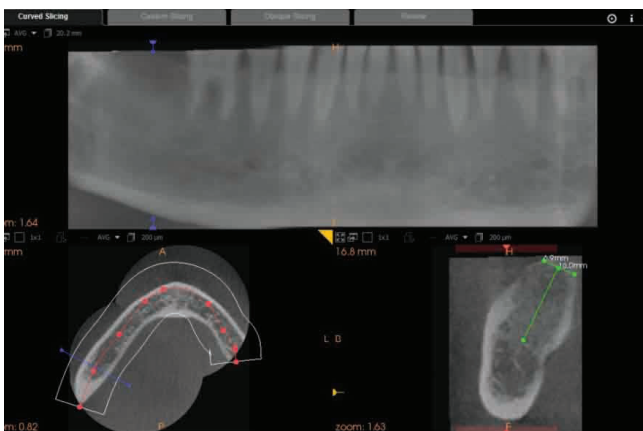


Figure-1: CBCT analysis to assess available alveolar ridge dimensions

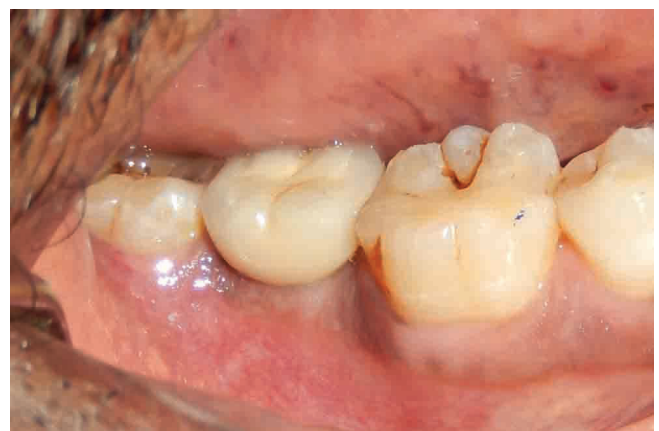

Figure-3: Final prosthesis in place over the implant - buccal view

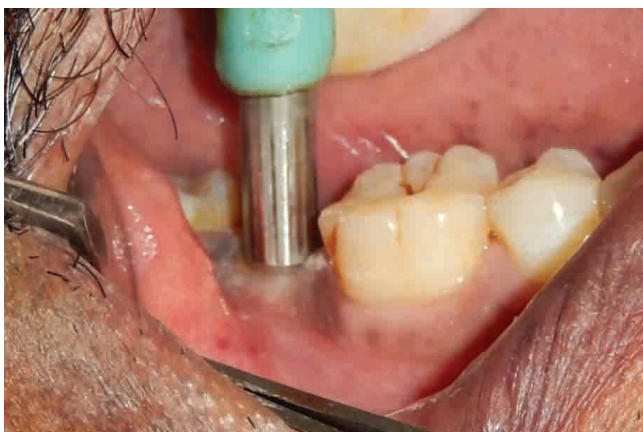

Figure-2: Tissue punch to guide implant osteotomy

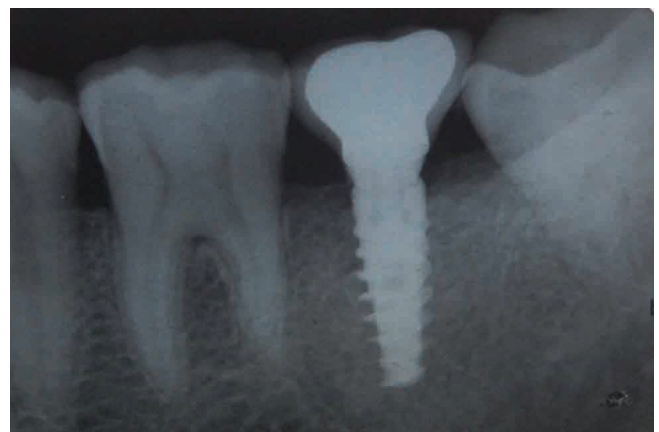

Figure-4: Follow-up IOPA of the implant with prosthesis

and Camara⁹ carried out a retrospective clinical analysis of 770 implants in 359 patients placed with a flapless approach in which the success rate post 10 years varied from 74.1% in the first year to 100% in the last year, concluding that flapless implant surgery is a predictable procedure if patient selection and surgical technique are appropriate.

The patient was provided with the DMLS prosthesis. Laser sintering process was first introduced by Deckard and Beaman¹⁰ also known as “3D printing” as it prepares the framework in a series of thin layers. It is the latest technology in metal manufacturing. Without using any machining DMLS produces complex 3D components directly from 3D CAD data for superior fit and function.

CONCLUSION

Flapless procedures cause less discomfort due to minimal tissue manipulation leading to better healing. It also eliminates the need for a second stage surgery. Proper case selection is important to avoid any complications. It is a predictable procedure that must be incorporated in our routine dental practise.

REFERENCES

1. Ramfjord SP, Costich ER. Healing after exposure of periosteum on the alveolar process. *J Periodontol.* 1968;38:199–207.
2. Casap N, Tarazi E, Wexler A, Sonnenfeld U, Lustmann J. Intraoperative computerized navigation for flapless implant surgery and immediate loading in the edentulous mandible. *Int J Oral Maxillofac Implants.* 2005;20:92-98.
3. Fortin T, Bosson JL, Isidori M, Blanchet E. Effect of flapless surgery on pain experienced in implant placement using an image-guided system. *Int J Oral Maxillofac Implants.* 2006;21:298-304.
4. Al-Ansari BH, Morris RR. Placement of dental implants without flap surgery: A clinical report. *Int J Oral Maxillofac Implants.* 1998;13:861-865.
5. Becker W, Wikesjo UM, Sennerby L, Qahash M, Hujuel P, Goldstein M, et al. Histologic evaluation of implants following flapless and flapped surgery: A study in canines. *J Periodontol.* 2006;77:1717-22.
6. Hahn J. Single-stage, immediate loading, and flapless surgery. *J Oral Implantol.* 2000;26:193-198.
7. Jeong S, Choi BH, Li J, Kim HS, Ko CY, Jung JH, et al. Flapless implant surgery: An experimental study. *Oral Surg Oral Med Oral Pathol Oral Radiol Endod.* 2007;104:24-28.
8. Fortin T, Bosson JL, Isidori M, Blanchet E. Effect of flapless surgery on pain experienced in implant placement using an image-guided system. *Int J Oral Maxillofac Implants.* 2006;21:298-304.
9. Campelo LD, Cámara JR. Flapless implant surgery: a 10-year clinical retrospective analysis. *Int J Oral Maxillofac Implants.* 2002;7:271-276.
10. Deckard C, Beaman J. Process and control issues in selective laser sintering. *ASME Prod Eng Div (Publication) PED.* 1988;33:191–197.

Source of Support: Nil; **Conflict of Interest:** None

Submitted: 19-03-2016; **Published online:** 16-04-2016