

# Role of Computed Tomography and Magnetic Resonance Imaging in Orbital Tumors with Histopathological Correlation

P.Sree Hari<sup>1</sup>, Praveen Kumar Alle<sup>2</sup>

## ABSTRACT

**Introduction:** CT and MRI when performed separately or in combination, will complement each other and provide exact diagnosis. Aim of the study was to evaluate efficacy of CT in orbital tumors and role of MRI to assess the nature, anatomical extent, morphology and aid in decision making for choice of treatment, and to correlate with histopathological diagnosis.

**Materials and methods:** It is a prospective study of CT and MRI evaluation of Orbital tumors with histopathological correlation was conducted on 35 patients with a suspicion of having orbital lesion.

**Results:** 17 were male and 18 were female patients. Mild female preponderance is seen with Maximum number of the patients was under 9 years. Proptosis is the most common clinical presentation noted in 26 cases (74.3%). The most common tumor in the adult age group was Optic nerve meningioma and in the pediatric group was retinoblastoma, MRI can better differentiate the pseudotumor from lymphoma, by showing the involvement of tendinous part of extraocular muscles, orbital fat stranding and reactive inflammation of sclera. In all the tumors, involving the optic nerve, MRI clearly showed the extent of the lesion and morphology. Except in one case, diagnosis in all the other cases was correlating with histopathological diagnosis.

**Conclusion:** CT and MRI when performed in combination will complement each other and provide correct diagnosis. MRI was superior to access nature, anatomical extent and morphology. Diffusion weighted image and apparent diffusion coefficient offer a useful additional parameter that can differentiate malignant tumours from benign lesions with high sensitivity and specificity.

**Key words:** Diffusion-weighted imaging, Apparent diffusion coefficient, Orbital tumors

lesion and intracranial extension.<sup>1</sup> Extra orbital diseases involving the orbit are also well delineated.

CT provides quicker scans, is able to image bone directly, and shows the presence of calcification better. Multidetector CT is now able to provide isotropic multiplanar imaging which has increased its ability to localize the site of orbital lesions.

MRI has advantages over CT in its superior soft tissue contrast, its ability to image the orbit and intracranial structures free of beam hardening artefacts from the skull base, dental fillings, and its lack of ionizing radiation. Selection of appropriate MRI imaging protocols and use of the correct surface coils is important depending on clinical question.<sup>2</sup> Use of gadolinium contrast enhancement and fat suppression aids in disease detection and characterization.

Hence this study is done to evaluate efficacy of CT in orbital tumors and role of MRI to assess the nature, anatomical extent, morphology and aid in decision making for choice of treatment, and to correlate with histopathological diagnosis

## MATERIALS AND METHODS

This prospective study of CT and MRI evaluation of Orbital tumors with histopathological correlation was conducted on 35 patients at Osmania General Hospital/Osmania Medical College, Hyderabad and also patients referred from Sarojini Devi Eye Hospital, which is attached to our hospital, with a suspicion of having orbital lesion.

### Inclusion Criteria

Patients who presented with proptosis, white reflex or mass around the orbits or clinically, fundoscopically suspected to have intraocular or retrobulbar lesion were selected and studied.

The patients included in the study had complaints of pain in

<sup>1</sup>Associate Professor, <sup>2</sup>Post Graduate, Department of Radiology, Osmania General Hospital and Osmania Medical College, Hyderabad, Telangana.

**Corresponding author:** Dr. P.Sree Hari, H.no 9-14, Ravindra nagar colony, Habsiguda, Hyderabad, India

**How to cite this article:** P.Sree Hari, Praveen Kumar Alle. Role of computed tomography and magnetic resonance imaging in orbital tumors with histopathological correlation. International Journal of Contemporary Medical Research 2016;3(1):182-186.

## INTRODUCTION

Diagnosis of orbital lesions is often not clear even after thorough clinical examination. In earlier era this dilemma would necessitate an exploratory orbitotomy in order to determine the diagnosis. With advent of CT and MRI, these have become the procedures of choice in arriving at a diagnosis. The clarity of presentation of orbital structures by CT and MRI have prompted investigations into detailed multiplanar anatomy of orbit. Tumor margins and inflammatory processes are so clearly needed that one can place the lesion in specific compartments and accurately determine the extent of the

the eye, redness of eye, proptosis, white reex and restriction of ocular movements.

**Exclusion Criteria**

Patients with recent history of trauma, patients with presence of foreign body, patients with claustrophobia and patients having metal implants are excluded from the study. A detailed history was taken from each patient followed by clinical examination and findings were tabulated. Basic investigations like blood and urine analysis were done in all patients.

**Patient Preparation**

All patients were advised at least three hours of fasting prior to the examination, Children who were not cooperative were sedated by giving oral Phenergan or IV diazepam. A thorough clinical examination was done with particular attention to the lesion in orbit. Contrast studies performed by injecting 60% or 76% Urograffin calculated at a dose of 300mg/kg body weight as a single bolus injection.

**Imaging**

Computed Tomography imaging was performed and following were used. Kilovoltage 120kv, Tube current 150Ma axial and coronal thin sections of 3mm slice thickness with no interslice gap were taken, FOV 25cm, matrix 512 \_ 512. Omnipaque contrast media was for contrast enhanced scans. MRI was performed on a 1.5 Tesla electromagnet (GE Company). The primary pulse sequences included T1 and T2WI using spin echo and gradient echo techniques. T1 weighted images were obtained with a TR of 600 msec. and TE of 30msec. T2W1 were obtained with a TR of 2740msec. and TE of 85msec. Images were obtained with a multislice technique using a slice thickness of 5mm, interslice gap of 6mm, FOV of 220 240mm and a matrix size of 512 \_ 512.

**MRI Orbit Protocol**

- Coronal STIR Orbits
- Coronal T2/T1 Fat Saturated Orbits
- Axial T2 Fat Saturated Orbits
- Axial T1 Orbits
- Sagittal T2 Fat Sat orbits (Parallel to optic nerve)

**POST CONTRAST \MRI Orbit Protocol"**

- POST axial T1 Brain
- POST coronal T1 Fat Sat
- POST axial T1 Orbits

Majority of these patients underwent surgery and their histopathology report was taken. The imaging morphology was correlated with histopathological features.

**Image Analysis**

On the basis of involvement of globe, intraconal or extra-

conal or arising from muscle/ from orbital wall, expansion of bony orbit, destruction of bone, calcification, attenuation, extension of the lesion and enhancement, the tumors are characterized.

**RESULTS**

The study Role of Computed Tomography and Magnetic Resonance Imaging in the evaluation of Orbital tumors with histopathological correlation was conducted on 35 patients. of 35 patients, 17 were male and 18 were female. Slight female preponderance is seen in my study. Age of patients range from 2 years to 70 years. More number of patients lie in 0-9 year group than in any other age group. Out of 35 cases, most common tumor in the adult age group was Optic nerve Meningioma (6 cases), followed by Pseudotumor (4 cases), cavernous hemangioma (2 cases), lymphoma (2 cases), Vascular malformations (2 cases), frontal mucocele (1 case, which is mimicking like a primary orbital

Age	Males	Females
0-9	3	6
10-19	3	4
20-29	0	0
30-39	1	5
40-49	2	2
50-59	5	1
60-69	2	0
70-79	1	0

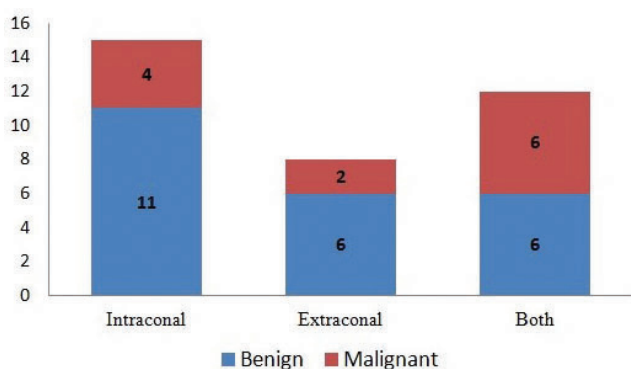
**Table-1:** Demographic distribution

Diagnosis	Number of Cases
Cavernous Hemangioma	2
Retinoblastoma	4
Capillary Hemangioma	3
Pseudotumor	4
Lymphoma	2
Epidermoid	1
Optic Nerve Meningioma	6
Optic Nerve Glioma	3
Schwannoma	1
Rhabdomyosarcoma	3
Venolymphatic Malformation	2
Metastasis	1
Mucocele	1
Melanoma of Choroid	1
Lacrimal gland tumor	1
Clinical Picture	
Proptosis	26
Defective Vision	20
Diplopia	4
Motility Disturbance	5
Pain	11
Signs of Inflammation	9
White Reflex	4

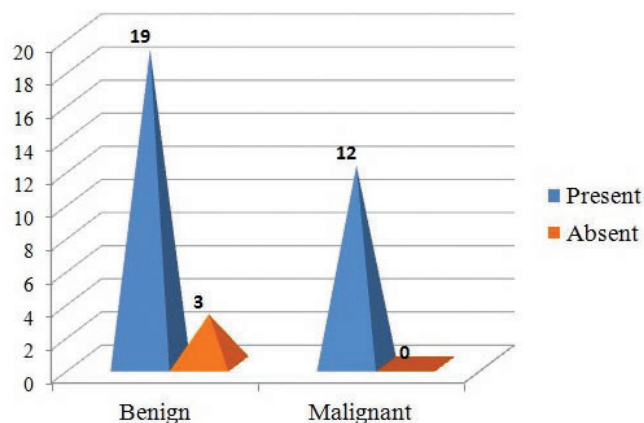
**Table-2:** CT and MRI Diagnosis

	Benign	Malignant
<b>Extraocular Musclce Involvement</b>		
Present	7	6
Absent	16	6
<b>Optic Nerve Involvement</b>		
Present	9	7
Absent	14	5
<b>Bone Changes</b>		
Present	2	5
Absent	21	7
<b>Calcification</b>		
Present	2	4
Absent	21	8

**Table-3:** Involvement of other sites



**Figure-1:** Location of tumor



**Figure-2:** Contrast Enhancement

tumor, resulting in severe proptosis), malignant melanoma of choroid(1 case), lacrimal gland mixedtumor(1 case) and 1 case of schwannoma. In the paediatric age group, cases with Retinoblastoma (4 cases) were maximum in number followed by capillaryhemangioma (3 cases), optic nerve gliomas(3 cases), Rhabdomyosarcomas (3 cases), 1 case of epidemoid and 1 case of orbital metastasis fromEwing’s sarcoma of left tibia. Majority of the patients (26 patients) presented with proptosis

Out of 35 cases, 23 cases were of benign tumors and 12 cases were of malignant tumors. In benign cases, 6 cases were extraconal, 11 cases were intraconal and 6 cases were both

intraconal and extraconal in location. In malignant cases, 2 cases wereextraconal, 4 cases were intraconal and 6 cases were both intraconal andextraconal in location.

9 cases with benign lesions, 7 cases with malignant lesions are showing optic nerve involvement. Bone changes are observed in 2 cases with benign tumors and in 5 cases with malignanttumors.

7 cases with benign lesions, 6 cases with malignant lesions are showing extraocular muscle involvement. Calci\_ cation is observed in 4 cases with malignant lesions, 2 cases withbenign lesions. All cases with malignant tumors, 20 cases with benign tumors show Contrast enhancement.

**DISCUSSION**

Wide varieties of tumors are known to occur in the orbit. Vascular, lymphoid, nervous, and mesenchymal structures are all normally found within the orbit and may give rise to primary orbital tumors. Primary lacrimal gland tumors of lymphoid and epithelial cell origin also cause orbital masslesions. Orbital tumors are comparatively rare, constituting only about one percent of the cases among the patients admitted to the eye departments.

The study was done on 35 patients of whom contrast was given in 34. Orbital tumors were analyzed based on clinical, ophthalmologic and Computed tomography, Magnetic resonance imaging. Patients presented with proptosis, suspected to have orbital mass were included in the study. Surgery was done in required patients and correlated with histopathological diagnosis.

In our study, the age group of patients ranges from 2 to 70 years. 17 were male and 18 were female patients. Mild female preponderance is seen in my study. More number of patients lie in 0-9 year group than in any other age group. Proptosis is the most common clinical presentation observed in 26 cases. This is comparable to the study of Simona Dunarintu et al<sup>3</sup> in which exophthalmia was the most important clinical symptom found in 95 cases (62.91%) also correlates with previous studies.<sup>4</sup>

The most common tumor in the adult age group in our study was Optic nerve meningioma (6 cases), with a female to male ratio 3:2. The age range is 30-40 years. All of the patients underwent surgery. One case showed peripheral calcification. This is comparable to the study of Wilson and Grossniklaus<sup>5</sup>, reviewed around 4,563 cases of orbital lesions and the most common tumor in their study was meningioma followed by cavernous hemangioma, lymphoma. Simona Dunarintu et al<sup>3</sup> studied 151 patients with age between 1-82 years. They classified of the orbital tumors into primitive orbital tumors 114 (75.49%), propagated secondary orbital tumors 33(21.95%) and secondary metastatic orbital tumors 4 (2.64%). The most frequent histopathological type of primitive orbital tumors in their study was meningiomas (14.56%).

We have encountered 4 cases of Pseudotumor, patients of the age above 50 years with female to male ratio 1:3. One case

had history of trauma and three cases are of idiopathic etiology. All the four cases showed involvement of extraocular muscles with its tendinous part and orbital fat stranding. This is supported by Guy J. Ben Simon et al.<sup>6</sup> study that orbital fat involvement and fat stranding was noticed only in inflammatory lesions. Diffusion weighted imaging has an important role in differentiating between inflammatory and malignant lesions. Diffusion restriction is usually seen in malignant lesions but not seen in inflammatory lesions. One case of Pseudotumor is showing restriction on diffusion weighted imaging. This is correlated with the study done by Roshdy N et al.<sup>7</sup> For one case, we performed ultrasound guided FNAC which is in favor of pseudotumor. All patients responded good with steroids and were in continuous follow up.

Cavernous hemangioma was diagnosed in two male patients with age between 45 to 50 years. The study by Alfred and Char et al<sup>8</sup> found that 70% of their patients with cavernous hemangiomas were women with a mean age of 41 years at the time of diagnosis. Our cases showed no restriction on diffusion weighted imaging in both the cases. This is in contradiction to the study done by Roshdy N et al<sup>7</sup> (2010) in which they noticed diffusion restriction in one case.

One case of lymphoma was diagnosed in male patient of age 50 years. The patient underwent surgery and was advised chemotherapy. Imaging showed round lobulated mass, molding to adjacent structures, and a wedge shaped enlargement of the lacrimal gland. Both of them were isointense on T2 WI. This is supported by the study done by Polito et al.<sup>9</sup> One case of Lymphoma misdiagnosed as Pseudotumor on imaging which was showing restriction on diffusion weighted imaging.

One case of schwannoma was diagnosed in a 17 year female patient, and showed bone remodeling which is better depicted on CT. MRI clearly delineated superior rectus muscle separate from the lesion. Two cases of venolymphatic malformations were diagnosed in 30- 35 year females which is uncommon in this age group. One patient had both superficial and deep components. She had recurrence because of presence of both the components. This is supported by the study done by Root man et al.<sup>10</sup>

One case of frontal mucocele was diagnosed in a 70 year male with proptosis mimicking orbital tumor. Sinus expansion was noted and signal is hyperintense on T1, isointense on T2 WI due to mucinous content. This is the only case of para orbital mass extending into orbit which we have come across. One case of malignant melanoma of choroid was diagnosed in 48 year female which is hyperintense on T1, hypointense on T2WI. One case of lacrimal mass diagnosed as mucoepidermoid carcinoma based on calcifications and bony changes later proven to be mixed malignant tumor on histopathology.

Among pediatric tumors, most common tumor was retinoblastoma. 4 cases were seen in patients with age less than 5 years. This finding is identical to the study done by SushmaVashisht et al.<sup>11</sup> One case showed bilateral involvement,

one case showed infiltration of optic nerve and extension up to suprasellar region, two cases are unilateral in presentation. All of these showed calcification, a unique feature of retinoblastoma, and are depicted well on CT. The extent of Optic Nerve Involvement is better demonstrated on MRI.

Three cases of capillary hemangioma were diagnosed in female children of age below 10 years. After a period of observation, two of them showed gradual regression of the tumor. One case lost follow up. Three cases of rhabdomyosarcoma were diagnosed in patients of age between 4 and 12 years with female to male ratio 2:1. Bone involvement was noticed in all cases.

Optic nerve gliomas diagnosed in 3 male children of age below 10 years. Histopathology revealed grade 1 stage in two cases and grade 2 stage in one case. One case of epidermoid cyst of lateral orbital wall detected in a 11 year old boy. It is showing restricted diffusion on DWI. One case of metastasis from Ewing's sarcoma of tibia detected in 11 year old female. Bone destruction with intracranial extension is observed with large soft tissue component.

Out of 35, 23 cases were benign, in which 19 cases did not show restriction on DWI. 12 cases were malignant and all of them showed restriction. This is identical to the study done by Roshdy N et al<sup>7</sup>, who studied twenty patients with orbital soft tissue masses. Histopathologically, 14 cases had benign lesions whereas the remaining six had malignant lesions. On DWIs, 57% of benign lesions appeared hypointense indicating free diffusion. All (100%) malignant tumors appeared hyperintense indicating restricted diffusion and showed low ADC values.

## CONCLUSION

In our study the age group includes from 2 to 70 years. 17 were male and 18 were female patients. Mild female preponderance is seen in my study. Maximum number of the patients was under 9 years. Proptosis is the most common clinical presentation noted in 26 cases (74.3%). The most common tumor in the adult age group was Optic nerve meningioma and in the pediatric group was retinoblastoma, MRI can better differentiate the pseudotumor from lymphoma, by showing the involvement of tendinous part of extraocular muscles, orbital fat stranding and reactive inflammation of sclera. In all the tumors, involving the optic nerve, MRI clearly showed the extent of the lesion and morphology. Except in one case, diagnosis in all the other cases was correlating with histopathological diagnosis. DWI (diffusion-weighted imaging) and ADC offer a useful, reliable, safe and non-invasive imaging parameter that can be used for the differentiation of malignant tumors from benign lesions with high sensitivity and specificity.

## REFERENCES

1. Dubey RB, Tara NP and Sisodiyer KN. Computed to-

- mography evaluation of orbital lesion Pictorial essay. *Ind J Radiol* 2003;13: 261-270
2. Lemke AJ, Kazi I, Felix R. magnetic resonance imaging of orbital tumours. *Eur J. Radio* 2006; 16: 2207-2219.
  3. Simona Dunarintu et al. Whole-body MR imaging with the use of parallel imaging for detection of skeletal metastases in paediatric patients with small-cell neoplasms: comparison with skeletal scintigraphy and FDG PET/CT. *Journal of Experimental Medical and Surgical Research* 2008; 1-2: 5-12
  4. S. Krohmer, I. Sorge, A. Krausse et al. Whole-body MRI for primary evaluation of malignant disease in children. *European Journal of Radiology* 2010; 74: 256261.
  5. Wilson M, Grossniklaus HE. Orbital disease in North America. *Ophthalmol: Cin North Am* 1996;4:539547.
  6. Guy J. Ben Simon et al. *American Academy of Ophthalmology* 2005;112:2196.
  7. Roshdy N, Shahin M, Kishk H, El-Khouly S, Mousa A, Elsalekh I. Role of new magnetic resonance imaging modalities in diagnosis of orbital masses: A clinicopathologic correlation. *Middle East Afr J Ophthalmol* 2010;17:175-9.
  8. Alfred P, Char D. Cavernous haemangioma of the orbit. *Orbit* 1996;15:5966.
  9. Polito E, Galieni P, Leccisotti A. Clinical and radiological presentation of 95 orbital lymphoid tumors. *Graefes Arch ClinExpOphthalmol* 1996;234:504 9.
  10. Root man J, Hay E, Graeb D. Orbital- adnexal lymphangiomas. *Ophthalmology* 1986;93:1558-1570.
  11. Vashisht S, Goulatia R K, Dayal Y, Bhargava S. Impact of computerised axial tomography on orbital diagnosis. *Indian J Ophthalmol* 1983;31:347-52

**Source of Support:** Nil; **Conflict of Interest:** None

**Submitted:** 04-12-2015; **Published online:** 19-12-2015