CASE REPORT

Brown Tumor In Maxilla As A Result Of Primary Hyperparathyroidism

Anjali[1], Neeraj Singh[2], Pallavi Malaviya[3], Sandeep Choudhary[3]

ABSTRACT

Introduction: Brown tumor or lesions resembling giant cell tumor is a rare sequel of hyperparathyroidism and occasionally affect jaw bones. Brown tumor is three times more common in women as compared to men. Mandible is more frequently involved than maxilla. Parathyroidectomy to control HPT is the treatment of choice for brown tumor.
Case report: This paper describes a rare case report of brown tumor of maxilla in a 70 year old female, she was found to have osteolytic lesion in left maxilla and high blood calcium levels. She gave a history of giant cell tumor of right side of mandible for which curettage was done one year back. Sestamibi scan revealed right inferior parathyroid adenoma. Patient underwent removal of parathyroid gland, right hemithyroidectomy and central node dissection. Histology confirmed parathyroid adenoma.
Conclusion: Primary hyperparathyroidism is a curable disease and need surgical intervention.Inital treatment of brown tumor involves control of hyperparathyroidism and once the hyperparathyroidism is controlled the tumor tends to regress

Keywords: Maxillary brown tumor, Primary hyperparathyroidism, Parathyroid adenoma.

How to cite this article: Anjali, Neeraj Singh, Pallavi Malaviya, Sandeep Choudhary. Brown Tumor In Maxilla As A Result Of Primary Hyperparathyroidism. International Journal of Contemporary Medical Research 2015;2(3): 533-535

[1]Consultant Oral and Maxillofacial Surgeon (Ex. Post Graduate Student, NIMS Dental College, Jaipur) [2]Ex HOD, Department of Oral And Maxillofacial Surgery, NIMS Dental College, [3,4]Post Graduate Student, Department of Oral And Maxillofacial Surgery NIMS Dental College, India

Corresponding author: Dr.Anjali, 1788, Gau Shala Street, Muktsar, Punjab, India

Source of Support: Nil

Conflict of Interest: None

INTRODUCTION

Brown tumor or lesions resembling giant cell tumor is a rare squeal of hyperparathyroidism.[1] Primary hyperparathyroidism is thirty times more common in India as compared to west countries.[2] Most common brown tumor sites are pelvis, femur and mandible. Maxillary involvement is extremelyrare. Females areaffected more commonly than males.[3,4]The name "BROWN TUMOR "derives from itscolor, which is due to deposition of hemosiderin and hemorrhage.[5,6] This paper describes a clinically and histologically diagnosed case of brown tumor that was located in maxilla.

CASE REPORT

A 70 year old female patient visited outpatient Department of Oral and Maxillofacial Surgery at NIMS Dental Hospital with a swelling on left side of maxilla since one month. Swelling had gradually increased in size with associated difficulty in chewing. She had a history of central Giant cell tumor of right side of mandible curetted one year back. Extra-oral examination revealed facial asymmetry. Intraorally bony hard swelling was present in left maxilla which was non tender on palpation extending from left canine to second maxillary molaranterio-posteriorly and measuring (32.3x41.0) mm in size (figure-1) with describe cortical expansion on buccal and palatal aspect. Panoramic radiograph (arrow) showedwell definedmultilocular radiolucent lesion in left maxillary region (figure-2).
Computed tomography (CT- Scan) demonstrated a large expansile lytic lesion seen centered in left bony maxillary mid region (figure-1,3) with thining and endosteal scalloping of cortical margins.Internal soft density septa gave it multilocular appearance. In soft tissue window, it showed homogenous isodense soft tissue bulging into right maxillary antrum through the floor. The alveolar margin was also involved and did not show teeth in this region .
The medial wall of left maxillary antrum was bulged into ipsilateral nasal cavity (Figure-3) displacing the inferior turbinate. However the osteomeatal complex was patent and visualized. Craniofacial bones and cervical spine showed osteopenia.Three dimensionalimage also showing destruction of left maxilla**.** Patient's biochemical analysis revealed the serum calcium levels were raised to 12.1 mg/dl (normal 8.5-10.3mg/dl) with high PTH 695.2pg/dl(normal 11-54) and low vitamin D 3mg/dl levels. There after

considering her previous history of mandibular surgery a provisional diagnosis of hyperparathyroidism was made. She was referred to department of endocrinology for evaluation,renal stones were also reported andSestamibi scan revealed right inferior parathyroid adenoma (Figure-4).

The clinical history,physical examination, laboratory and radiological findings were suggestive of primary hyperparathyroidism. She was referred for medical evaluation and surgical intervention. Right inferior parathyoidectomy and right hemithyroidectomy with isthmusectomy was done. (15 minutes post operative PTH level were normal.).The well encapsulated maxillary lesion had started to regress slowly after the removal of left parathyroid gland.Histopathological examination of excised parathyroid gland revealed an adenoma.

DISCUSSION

Hyperparathyroidism is a condition caused by high circulating level of parathyroid hormone. [7] Primary hyperparathyroidism is most commonly caused by adenoma (81 percent) followed by hyperplasia (15 percent) with carcinoma (0.5-4 percent).[8,9] It may also be inherited as an autosomal dominant condition in patient with hyperparathyroidism- jaw tumor syndrome (HPT-JT SYNDROME)[10] and multiple endocrine neoplasia syndrome (MEN SYNDROME).[7] The renal manifestations of primary hyperparathyroidism are formation of renal stones or diffuse deposition of calcium phosphate complex in parenchyma.

- Parathyroid gland hyperplasia often found in Chronic renal faliure patients.
- Hypocalcaemia, hyperphosphatemia and calcitriol deficiency may be found inchronic renal faliure and are the main reasons for increased PTH secretion; this in turn results in morphological changes in parathyroid glands. [10] Imbalance of osteoclastic and osteoblatic activity cause bone resorbtion withfibrous replacement of marrow and thining of cortex leading to condition which is called osteitisfibrosa cystic(OFC) or Von Recklinghausen disease of bone and brown tumor.[1] Browns tumor often develops at multiple sites including ribs, clavicle and pelvic girdle but maxillofacial brown tumor are rare, and in maxillofacial brown tumor involvement maxilla is relatively rare, accounting to 4.5 to11.8 % of brown tumours.[5,6] Brown tumours have been reported to occur in approximately 4.5% of patients with primary hyperparathyroidism.[1] Primary hyperthyroidism is more frequently seen in patients over 50 years of age,with gender predilection toward females.[1,7] These findings corroborate with our case where the patient was female and age was above 50. Brown tumor intraoral presents as painful, hard clearly visible,slow growing and palpable swelling,[6] in our case the patient had hard, clearly visible and slow growing swelling.Radio graphically browns tumor appear as well demarcated monolocular or multilocularosteolytic lesion. Computed tomography is helpful in identifying the extent of lesion. Computed tomography revealed following features
- A significant expansion of cortical plate.[5]
- Changes in the pattern of trabecular bone of the jaws[5], in our case also there was change in trabecular pattern of bone. Such patients with primary hyperparathyroidism frequently exhibited central giant cell granuloma of jaws, loss of lamina dura and demineralization of the jaws.[8]

Munday et al,in 1980, in a study of 207 patients with primary hyperthyroidism, found that 57% were asymptomatic. Renal involvement was present in only 7% and no bony involvement was detected.[5] In our reported case patient had renal stones in addition to hyperparathyroidism. Guney et al,reported a case of primary hyperparathyroidism associated with brown tumor of maxilla and multiple skeletal involvement.[9] The case presented here is another example of primary hyperparathyroidism with brown tumor involving maxilla. Pathological examination of right inferior parathyroid gland revealed an encapsulated solid cystic mass,40x40x12 mm and weighing 15 gm. Microscopically,the mass was composed of cord like growth of cells arranged sheets,follicles and islands separated by cystic spaces.round to oval nuclei with granular cytoplasms; fine fibrous septae were present between the tumor cells. These pathological findings were consistent with parathyroid adenoma (Figure-5)

The hemorrhage and hemosiderin gives the tumor a brown color and thus its name.[5,6] Histologically, the presence of the giant osteoclasts in the lesions along with plump fibroblasts leads to confusion of tumour with other jaw lesions that contain giant cell such as aneurismal bone cysts or cherubism.[3,4] Histopathologically our case showed multinucleated giant cells and spindal shaped stromal cells with loose fibrillar connective tissue and hemorrhage and hemosiderin laden macrophages.

Results of fine needle aspiration biopsy demonstrated osteoclastic giant cells with a lesser number of osteoblasts with minute fragments of osteoid and fibrosis. Incisional biopsy will show a giant cell lesion, and other biochemical test including parathyrodism

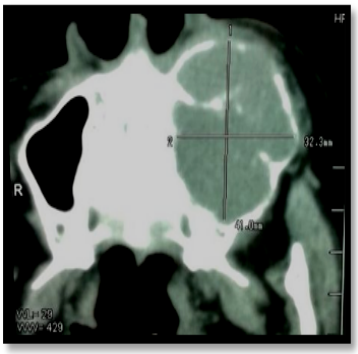

Figure-1: Lesion involving Left Maxilla

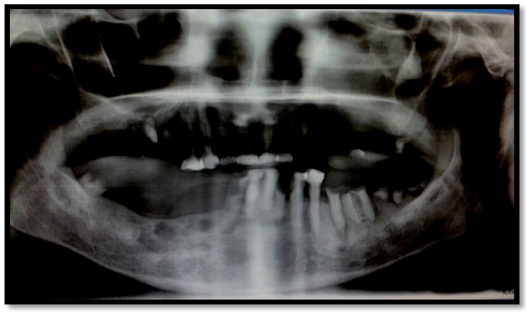

Figure-2: Multilocular radiolucent lesion in left maxilla

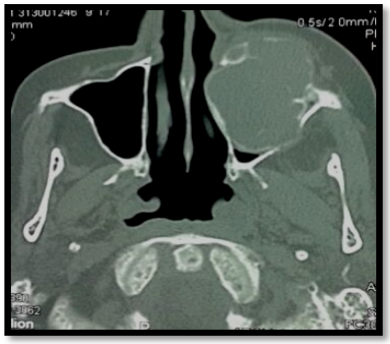

Figure-3: Radiolucent lesion involving maxillary antrum and displacing inferior turbinate

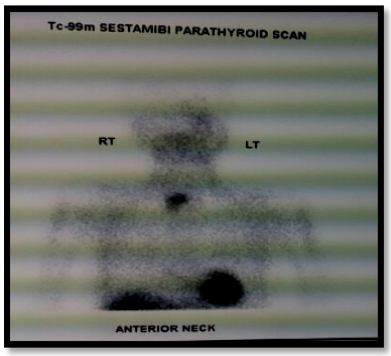

Figure-4: Sestamibi scan of anterior neck showing right inferior parathyroid adenoma.



Figure-5: Microscopically right inferior parathyroid gland, showing cord-like growth of cells, consistent with parathyroid adenoma.

from other giant cell granuloma, anurysmal bone cyst and giant cell tumor.[6,10] Primary hyperparathyroidism is a curable disease with successful removal of parathyroid adenoma overt bone disease indicates surgical intervention. Inital treatment of brown tumor involves control of hyperparathyroi- dism and once the hyperparathyroi- dism is controlled the tumor tends to regress .[1]

Several cases of browns tumor that grew even after parathyoidectomy or normalization of PTH level therefore it is considered that brown tumor should be removed if it does not show involution soon after parathyoidectomy.[3] In aggressive lesions conservative use of intralesional corticosteroid and calcitonin a possible osteoplasty after decalcific- ation of osteolytic sites.[2,3]

REFERENCES

1. Keyser JS, Postma GN.Brown tumor of mandible. Am J Otolaryngol . 1996;17:407-10
2. Jebasingh F, Jacob JJ, Shah A, Paul TV, Seshadri MS. Bilateral maxillary brown tumours as the first presentation of primary hyperparathyroidism Oral Maxillofac Surg. 2008;12:97-100.
3. Kar DK, Gupta SK, Agarwal A, Mishra SK Brown tumor of the palate and mandible in association with primary hyperparathyroidism.J Oral Maxillofac Surg. 2001;59:1352-4.
4. Michiwaki Y, Michi K, Yamaguchi A: Marked enlargement of the jaws in secondary hyperpaeathyroidism. a case report. Int J Oral Maxillofac Surg. 1996;25:54-6..
5. Triantafillidou K, Zouloumis L, Karakinaris G, Kalimeras E, Iordanidis F.. Brown tumors of the jaws associated with primary or secondary hyperparathyroidism. A clinical study and review of literature.Am J Otolaryngol.2006;27:281-6
6. Raue F, Haag Ch, Frank-Raue K. Hyperparathyroidism –jaw tumor syndrome. Ahereditary form of primary hyperparathyroidism with parathyroid carcinoma. Dtsch Med Wochenschr. 2007 29;132:1459-62.
7. Mundy GR, Cove DH, Fisken R. Primary hyperthyroidism; changes in pattern of clinical presentation Lancet. 1980 Jun 21;1(8182):1317-20.
8. Paterson CR, Burns J, Mowat E. Long term follow up of untreated primary hyperparathyroidism. Br Med J (Clin Res Ed). 1984 Nov 10; 289(6454):1261-3.
9. Masson EA, MacFarlane IA, Bodmer CW, Vaughan ED. Parathyroid carcinoma presenting with brown tumour of mandible in a young man. Br J Oral Maxillofac Surg.1993; 31: 117-9.
10. Hobbs MR, Pole AR, Pidwirny GN, Rosen IB, Zarbo RJ, Coon H et al. Hyperparathyroidism-jaw tumor syndrome the HRPT2 Locus in with in 0.7-CM region on chromosome 1q. Am J Hum Genet. 1999;64:518-25.